



Case Report

Aberrant posterior inferior cerebellar artery injury with C1 lateral mass screw placement: a case report and review of the literature

Ahmad N. Nassr, MD^{a,*}, Presley P. Swann, MD^a, John Huston, III, MD^b,
Mohamed M. Abdelfatah, MD^c, Peter S. Rose, MD^a, Bradford L. Currier, MD^a

^aDepartment of Orthopedic Surgery, Mayo Clinic, 200 First St SW, Rochester, MN 55905, USA

^bDepartment of Radiology, Mayo Clinic, 200 First St SW, Rochester, MN 55905, USA

^cDepartment of Internal Medicine, Akron General Hospital, 1 Akron General Avenue, Akron OH, USA. Tel.: (330) 344-6000

Received 13 June 2013; revised 17 December 2013; accepted 5 February 2014

Abstract

BACKGROUND CONTEXT: Complications associated with C1 lateral mass screw placement are relatively infrequent. The most commonly feared complications include neural or vascular injury. Although both vertebral artery and internal carotid artery injuries have been discussed in the literature, there have been no reports of posterior inferior cerebellar artery (PICA) injury from C1 lateral mass screw placement. We report a case of patient who had a cerebellar stroke after C1 lateral mass screw placement, secondary to injury of an aberrant PICA.

PURPOSE: To describe the normal anatomy of the PICA, the anatomic variations previously reported in the literature, the sequela and symptoms of a patient with PICA injury, and the relevance to C1 lateral mass screw placement. No previous reports of PICA injury with a cerebellar stroke have been reported with C1 lateral mass screw instrumentation.

STUDY DESIGN: Case report and literature review.

METHODS: The patient underwent an Occiput–C6 posterior instrumentation for a pathologic fracture, secondary to multiple myeloma. In the postoperative period, the patient was found to have dysarthria, imbalance, and dysdiadochokinesia. Urgent computed tomography confirmed well placed C1 lateral mass screws. Magnetic resonance imaging/Magnetic Resonance Angiography showed an infarct in the PICA distribution with an abnormal variant of the PICA coursing extracranially around C1. Neurologic monitoring did not detect the injury intraoperatively.

RESULTS: The patient was treated with anticoagulation and he made a reasonable recovery from his stroke.

CONCLUSIONS: We report the first case of an aberrant PICA injured during a C1 lateral mass screw placement, resulting in a cerebellar stroke. Consideration should be given to abnormal PICA variation when placing C1 lateral mass screws. © 2014 Elsevier Inc. All rights reserved.

Keywords:

Posterior inferior cerebellar artery (PICA); C1 lateral mass screw placement; Complications of c1 lateral mass screw placement; Vascular injury; Posterior inferior cerebellar artery injury; Complications of cervical spine instrumentation; Aberrant vascular anatomy in the cervical spine; Stroke after c1 screw placement

FDA device/drug status: Approved (Cervical lateral mass screws).

Author disclosures: **ANN:** Research Support (Investigator Salary): Cervical Spine Research Society (F, Paid directly to institution), Orthopedic Research and Education Foundation (D, Paid directly to institution), AO Spine North America (D, Paid directly to institution); Research Support (Staff/Materials): Cervical Spine Research Society (F), Orthopedic Research and Education Foundation (D), AD Spine North America (D); Fellowship Support: OREF (D), AO Spine (E). **PPS:** Nothing to disclose. **JH:** Nothing to disclose. **MMA:** Nothing to disclose. **PSR:** Nothing to disclose. **BLC:** Royalties: Depuy Spine (H for the previous 48 months. Note: Mayo Clinic received 1.5× this amount, Paid directly to institution), Stryker Spine (D for the previous 48 months. Note: Mayo Clinic received 1.5× this amount, Paid directly to institution); Consulting: DePuy Spine (B for the

previous 48 months. Note: Mayo Clinic received 1.5× this amount, Paid directly to institution), Zimmer Spine (D for the previous 48 months. Note: Mayo Clinic received 1.5× this amount, Paid directly to institution); Trips/Travel: Zimmer Spine (B for the previous 48 months. Note: Mayo Clinic received 1.5× this amount).

The disclosure key can be found on the Table of Contents and at www.TheSpineJournalOnline.com.

There were no sources of funding or conflict for the manuscript.

* Corresponding author. Department of Orthopedic Surgery, Mayo Clinic, 200 First St SW, Rochester, MN 55905, USA. Tel.: (507) 266-5262; fax: (507) 266-4234.

E-mail address: nassr.ahmad@mayo.edu (A.N. Nassr)

Introduction

Lateral mass screw fixation of the atlas as a point of fixation in the upper cervical spine surgery is thought to be safe and is widely used. Safe screw placement is enhanced with anatomical knowledge and preoperative assessment of the area [1]. Complications are relatively infrequent but can be catastrophic. These include vascular injury of the vertebral or internal carotid artery [2].

Distortion of the anatomy or congenital abnormalities may place these structures at further risk. An anomalous vertebral artery at the craniovertebral junction is a well-recognized entity and may place the vertebral artery at an increased risk for injury during screw placement [3]. There are also variations in the location of the internal carotid artery relative to the anterior aspect of the atlas that may place the artery at risk with bicortical fixation of the lateral mass [4].

The first branch of the vertebral artery is the posterior inferior cerebellar artery (PICA). Variations of the PICA, both intracranially and extracranially also exist but literature regarding extracranial abnormalities are sparse. Knowledge of anatomical variations can affect preoperative surgical planning to avoid vascular complications. We report a case of PICA distribution stroke, secondary to injury of an aberrant PICA by a C1 lateral mass screw. The type of PICA anomaly that lead to the complication is rare and has been rarely described previously in the literature [5]. In this case, the PICA branched off the vertebral artery between

the transverse foramina of C1 and C2 and coursed over the entry point for the C1 lateral mass screw.

Case report

A 61-year-old man, with multiple myeloma and a destructive lesion at C2 was treated with chemotherapy and radiation to the cervical spine. On follow-up examination, the patient had progressive neck pain and repeat imaging showed progression of the disease with pathologic fracture and subluxation at C2 and substantial kyphosis (Fig. 1). He was neurologically intact but was felt to have an unstable cervical spine, so he was taken to surgery to stabilize his spine and prevent neurologic decline.

The patient was placed into Gardner wells traction and underwent occiput–C6 posterior spinal instrumentation and fusion, including bilateral C1 lateral mass screw placement. C1 screws were placed by direct visualization of the C1 lateral mass with caudal retraction of the C2 roots. Neuromonitoring with motor-evoked and somatosensory-evoked potentials was used without any change from baseline prepositioning potentials. The case was completed without complication. Twenty-four hours later, the patient was noted to have trace weakness on the right side, dysmetria and slight dysdiadochokinesis, without nystagmus. Postoperative cervical computed tomography to assess position of the instrumentation demonstrated no malposition (Fig. 2). Magnetic resonance imaging/MRA revealed no

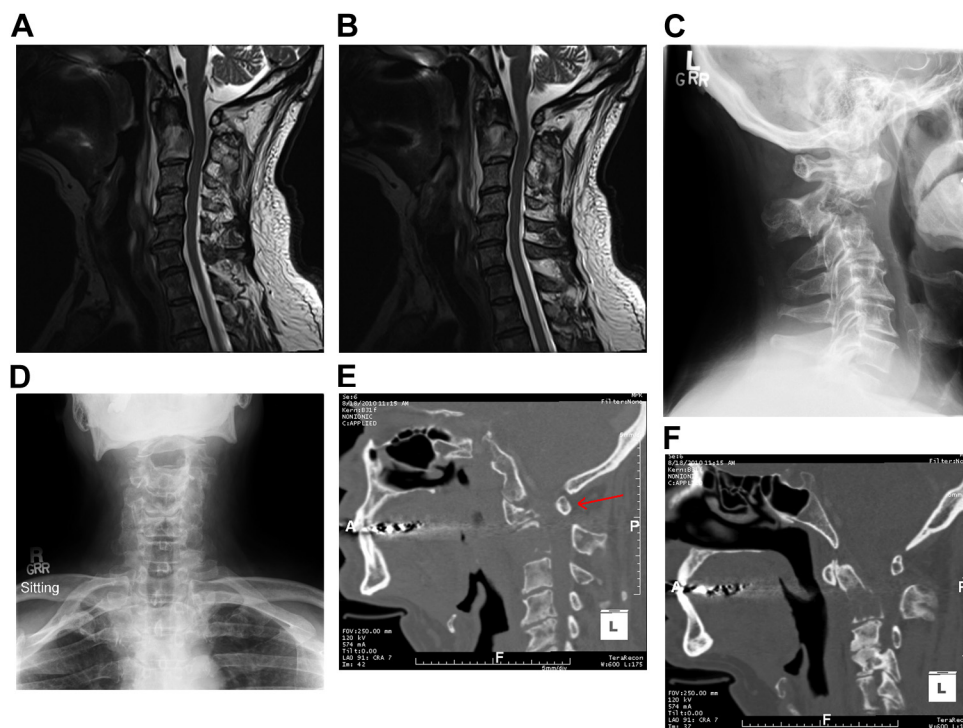


Fig. 1. (A and B) T2-weighted sagittal magnetic resonance imaging after pathologic fracture of C2. (C and D) PA and lateral X-ray showing pathologic involvement of C2 with kyphosis. (E and F) Sagittal computed tomography reconstruction preoperatively displaying the anterior displacement of C1 ring to C2 with resultant cord compression. The red arrow indicates the anterior displacement of the C1 ring secondary to the kyphosis at C2. PA, Posterior Anterior.

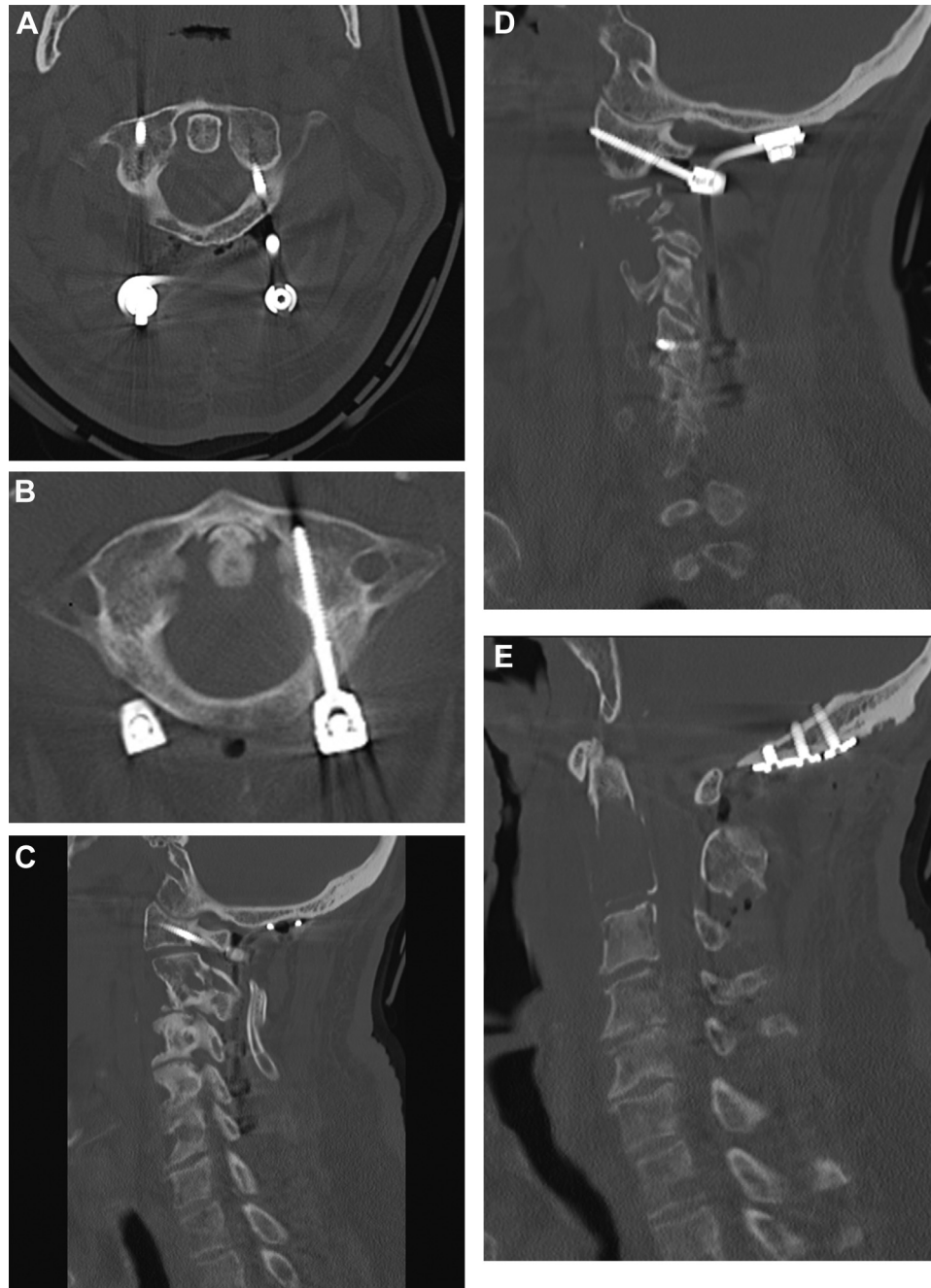


Fig. 2. (A and B) Axials of postoperative computed tomography (CT) of the C1 ring demonstrating good entry points and trajectories of the C1 screws. (C) Left parasagittal postoperative CT. (D) Right parasagittal postoperative CT. (E) Midsagittal postoperative CT demonstrating nice realignment of the pathologic fracture of C2 and correction of kyphosis.

evidence of vascular occlusion in his internal carotid or vertebral circulation; however, it demonstrated an acute left inferior cerebellar and small right parietal lobe infarction (Fig. 3). A thorough stroke work up was performed, including a bubble echocardiogram, and no other causes for the patient's apparent embolic stroke was identified. Although a formal angiogram was not obtained, based on neurologic consultation and neuroradiologist opinion, this was felt to be in the distribution of the PICA. It was theorized that

caudal retraction of the vessel during C1 screw placement resulted in a thrombus that dislodged and resulted in the clinical picture seen in this patient. The patient was managed with anticoagulation and thrombolytic therapy with subsequent improvement of hemiparesis and dysarthria. On follow-up, the patient remained neurologically intact with only a slight amount of dyskinesia. He eventually succumbed to recurrent systemic myeloma and complications of the treatment 21 months postoperatively (Fig. 4).

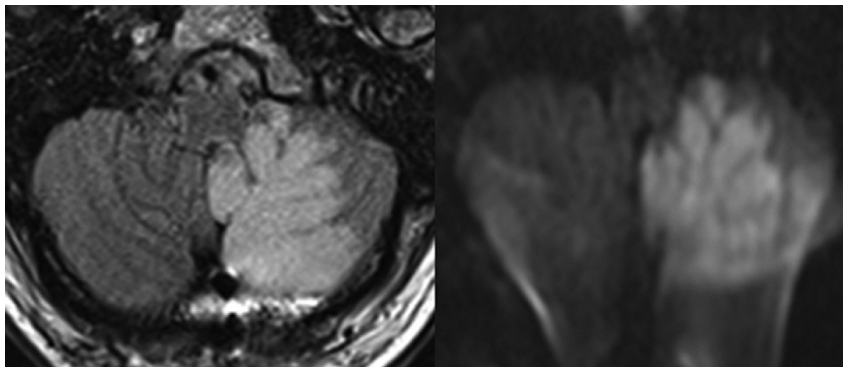


Fig. 3. (Left and Right) Diffusion weighted magnetic resonance imaging axials with acute left inferior cerebellar and small right parietal lobe infarcts in the distribution of the left posterior inferior cerebellar artery.

Radiographic review

We reviewed the patient's MRA with three independent fellowship trained neuroradiologists. The radiographic anatomy of the vertebral artery and PICA on the left side was reviewed, as this was the vessel of interest with the distribution of the embolic event. On the MRA, an abnormal location of the PICA origin was identified (Fig. 5). Computed tomography angiography (CTA) imaging confirmed the anomalous origin of this vessel, arising from the vertebral artery between the C1 and C2 transverse foramina. The artery then travels along the C2 nerve root, lying directly posterior to the C1 lateral mass screw entry point. The PICA followed the C2 nerve into the dura and coursed intradurally toward the cerebellum (Figs. 6 and 7)

Discussion

We believe, based on the distribution of the embolic event, based on the neurologist's assessment and the aberrant anatomy of the PICA confirmed by neuroradiology, that traction on the artery and C2 nerve root during placement of the C1 lateral mass screw resulted in a thrombus. During dissection, we did not encounter brisk bleeding corresponding with arterial injury and the aberrant vessel wasn't directly visualized. Based on our neuroradiologist's

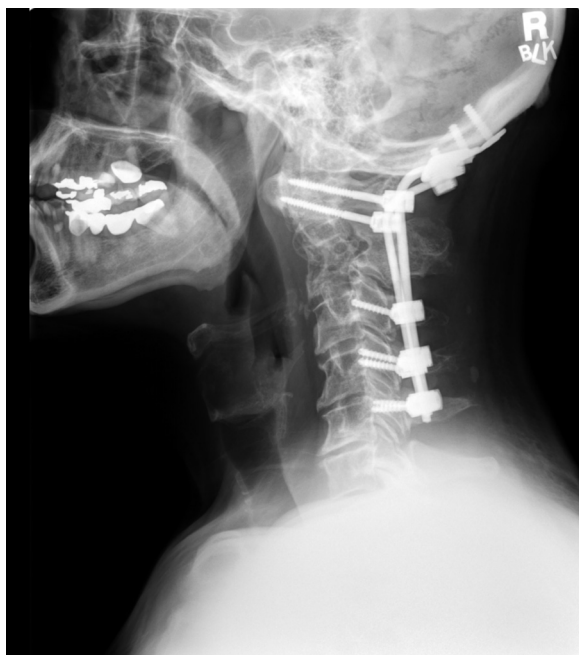

Fig. 4. Final postoperative lateral X-ray demonstrating maintenance of cervical alignment without additional hardware related complications.

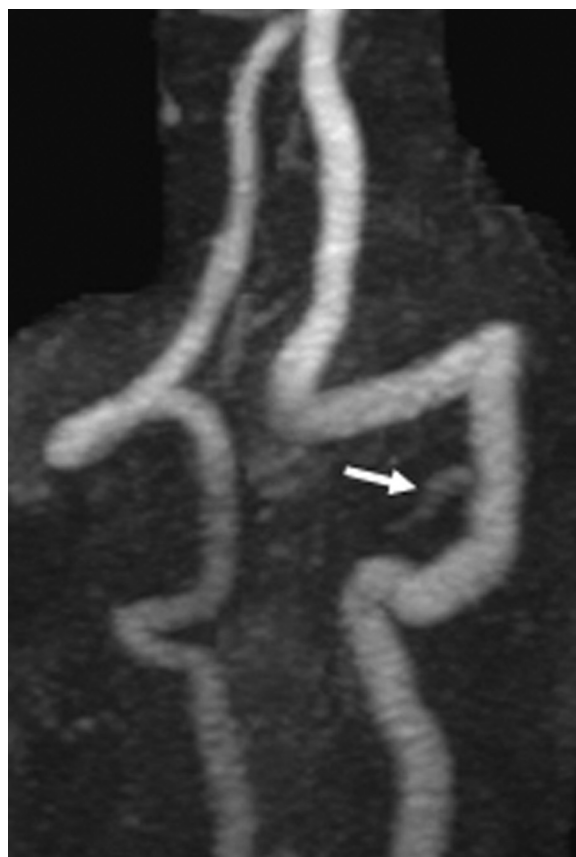

Fig. 5. Magnetic Resonance Angiography demonstrating the abnormal posterior inferior cerebellar artery origin (arrow).

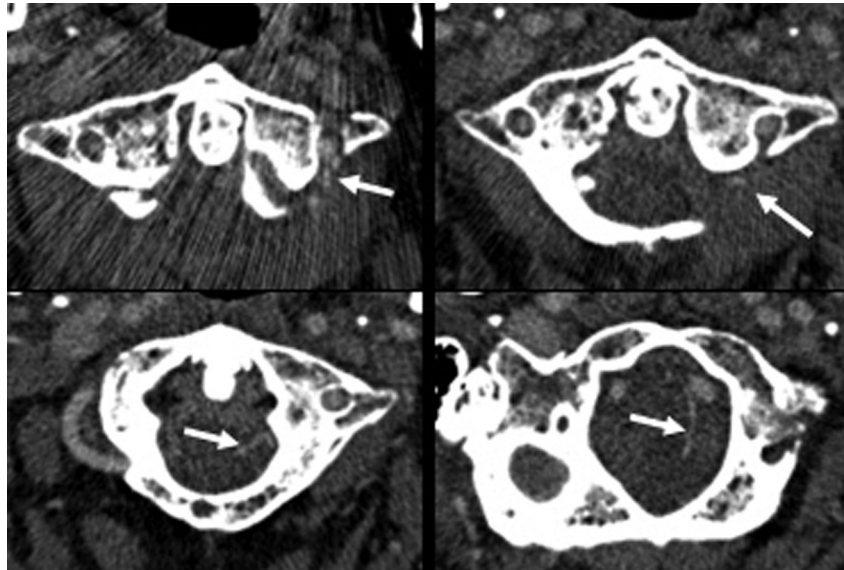


Fig. 6. Computed tomography angiogram demonstrating the course of the posterior inferior cerebellar artery that begins between the C1 and C2 foramen, following the C2 nerve root that then enters intradurally and progresses cephalad toward the cerebellum (arrows).

assessment, they were unable to visualize arterial injury such as dissection or intimal injury. However, we aren't able to definitively state based on imaging that this did not occur. No arterial injury was seen in the subaxial spine (Fig. 8). In discussion with our neurologist and radiology colleagues, we agreed on a theory based on all evidence that a thrombus had dislodged and resulted in the embolic stroke.

Based on our literature review, this is the first reported case of an aberrant PICA resulting in a stroke secondary to C1 lateral mass screw placement. One additional article describes the specific anatomic variation of PICA seen in this case. This was an angiography study, describing the different extracranial PICA variants over a 10-year period [5,6]. Discussion of abnormal PICA anatomy along with other vertebrobasilar arterial differences to reduce surgical complications is prudent (Fig. 9).

The PICA is defined as the first branch of the vertebral artery to the posterior circulation of the brain and is one of the three main arterial supplies to the cerebellum. The PICA is usually the largest branch of the vertebral artery and it typically originates intracranially and intradurally. Once the PICA ascends around the medulla, there are many variations of anatomy described in the literature but these are not pertinent to the placement of upper cervical instrumentation [7,8]. Extradural origin of the PICA may place the artery in harm's way, with the placement of upper cervical instrumentation. Fine et al. [6] describe a case in which both arteries were aberrant with origins that were 1 cm from the dura. The variant PICA ascended parallel to the vertebral artery and with the C1 nerve root. The presence of an extradural variance correlated with the intradural variance, with no direct vascular supply to the anterior brainstem. In a study by Saylam et al. [9], they found certain tendencies in the PICA variants depending on their level of origin.

The largest study found reporting on an abnormal PICA, originating or descending below the inferior border of the posterior arch of the atlas, showed an incidence of 1% [10]. Brinjikji et al. [10] reviewed 346 angiograms to study the PICA's anatomy. This was prompted because of a case report of injuring the PICA during a C1–C2 puncture [11]. Although this study supports evidence of aberrant anatomy of the PICA placing it at surgical risk, it did not report an origin as low as between C1 and C2. The only article we found to describe this relationship was a retrospective review of A-V malformations by Lasjaunias et al. [5] in which abnormal variations were recorded over a duration of 10 years in France. The report was the first and only to describe the C1–C2 extradural PICA, placing it at risk during C1 lateral mass screw placement.

Multiple variations in the vertebral basilar arterial system have been described in the literature that pose a risk to the placement of C1 lateral mass screws in cervical instrumentation. A summary of the reported variations is reviewed for knowledge of the potential surgical anatomy that maybe encountered. Vertebral ectasia is a condition in which the artery is dilated secondarily either to congenital malformation or atherosclerosis. The artery has been described as piercing the dura below the posterior arch of the atlas in the C1–C2 interlaminar space [12]. The mass effect can cause symptoms of occipital neuralgia with symptoms of pulsatile headaches, and foraminal enlargement should lend suspicion to this variant [13]. A larger artery can make the view for the starting point of C1 lateral mass screw difficult and also places the artery at risk with aggressive retraction. Tokuda et al. [14] found in an angiogram study of 300 patients, two cases in which the vertebral artery pierced the dura below C1, three cases of vertebral artery duplication, and two cases of origin of the PICA at

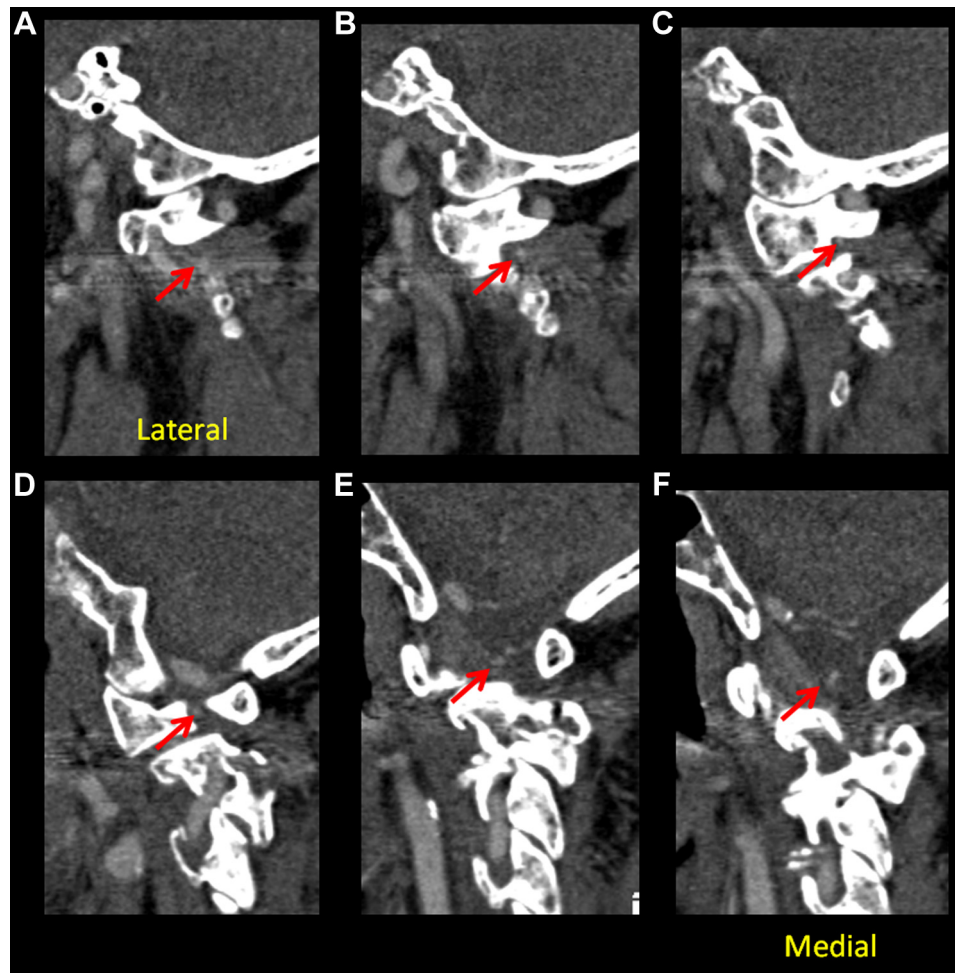


Fig. 7. (A-F demonstrating cuts from Lateral to Medial) Computed tomography angiography sagittal reconstructions demonstrating the relationship of the aberrant posterior inferior cerebellar artery and its relationship to the C1 lateral mass screw entry point. Red arrow follows the course of the PICA.

C2. Wang et al. [3] investigated 36 patients with known occipitalization of the atlas and found that 86% of the arteries would be placed at iatrogenic risk with C1 screw placement. The most common variation of the vertebral artery ascends laterally after leaving the C2-transverse foramen and enters an osseous foramen created between the atlas and occipital bone. The next variation is where the vertebral artery enters the spinal canal below the posterior arch of C1 and travels the surface of the lateral mass. Lastly, a proatlantal Type II artery can be present and complicate the surgical anatomy. The proatlantal intersegmental artery is a persistence of the embryonic carotid basilar anastomosis. These have been described as Type I, in which the artery originates from the internal carotid, and Type II, from the external carotid. The artery joins the vertebral artery around C1–C2 before entering the foramen magnum [15]. Persistence of carotid basilar anastomosis is often associated with hypoplasia or agenesis of the vertebral artery [16].

Discussion regarding when to obtain advanced imaging for craniocervical spine instrumentation is still debated. As shown by Currier et al. [4], variability in the internal carotid artery location in relation to the anterior aspect of the atlas

can place the vessel at risk with bicortical screw fixation. The location of the artery can be evaluated on a preoperative CTA and can help determine the ideal screw trajectory and length required to avoid vascular injury [4]. It is possible to avoid injury to the ICA by placing all C1 lateral mass screws unicortically, as long as the surgeon also avoids penetrating the anterior cortex of the atlas with a drill bit or tap. However, other vascular anomalies, including a persistent first intersegmental artery or an aberrant PICA, as reported here, may lead to vascular injury and could only be prevented by knowledge of the anomaly. Although the incidence of vertebral vascular anomalies is unknown in the general population, a series of 300 vertebral angiograms found the incidence to be 3% [14]. Vascular anomalies are frequently associated with congenital bony anomalies of the craniocervical region, and abnormalities such as occipitalization of the atlas should heighten the suspicion of aberrant vascular anatomy [3,17]. Other considerations to warrant investigation would be symptoms of occipital neuralgia. There has been a case report of an aberrant artery that causes irritation of the C2 nerve root and can be another clue along with osseous congenital anomalies that potential artery

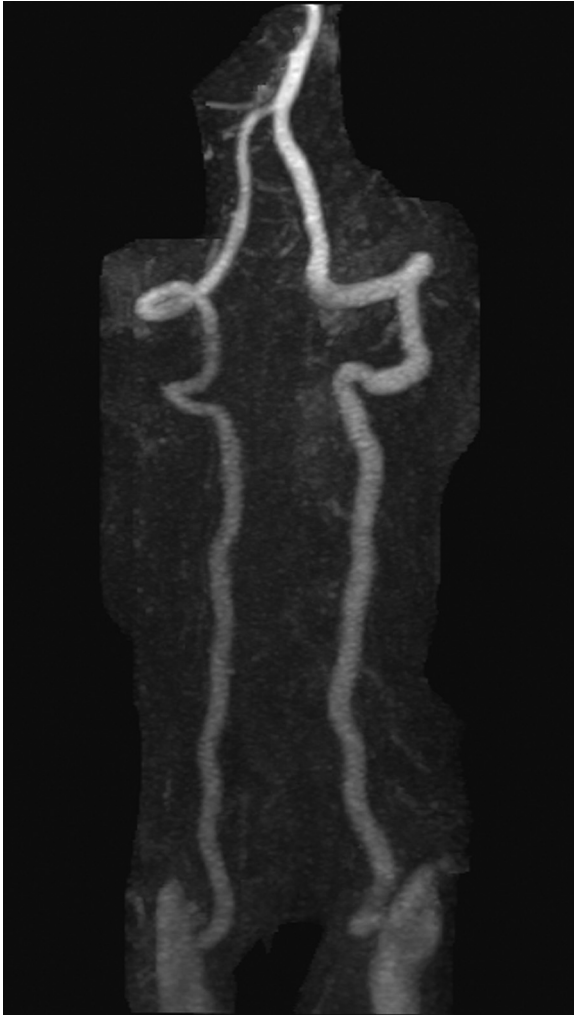

Fig. 8. MRA of complete vertebra basilar system to illustrate the integrity of the vertebral artery.

variability exists [13]. Other concerns when placing a C1 screw are the location and path of the vertebral and internal carotid arteries. An ectatic artery may be at risk with C1 screw placement. The internal carotid artery can course close to the anterior aspect of the C1 ring and can be injured with bicortical C1 screw placement [4]. Based on this case and others described in the literature, we routinely obtain a preoperative CTA of the neck when planning for upper cervical spine instrumentation, particularly at C1. We have developed a protocol, where in addition to review of standard vascular anatomy, our radiologists reformat the images to give us axial imaging in line with the C1 ring to allow for both lateral mass screw templating and assessment of the location of the vertebral and internal carotid arteries. Although this is not yet standard of care at all institutions, it may be a valuable tool to avoid vascular injury and should be strongly considered in patients with osseous congenital abnormalities or distorted anatomy.

We present this case to raise awareness that an aberrant PICA may be in close proximity to the entry point for C1

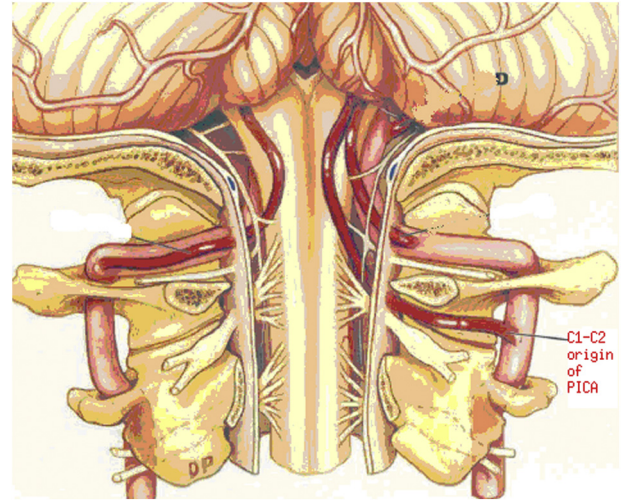


Fig. 9. Graphical representation of the anomalous PICA variant described in this case (Used and modified with permission from *Journal of Neurosurgery* [6], Publisher Excelsior). PICA, posterior inferior cerebellar artery.

lateral mass screw placement. The surgeon is ultimately responsible for complications associated with the care of these complex patients and therefore, can decide what preoperative imaging and counseling are appropriate before surgery. They must be aware of this potential complication and its postoperative symptoms to promptly intervene. A review of 25 cases with injury to the PICA resulted in symptoms of dysphagia, dysarthria, ataxia, dysmetria, dysdiadokinesis, facial pain, vertigo, nystagmus, Horner syndrome, diplopia, and palatal myoclonus [18]. Not all symptoms correlate perfectly with lateral medullary syndrome and a high clinical index of suspicion is most important in making the diagnosis; standard neurologic monitoring did not demonstrate any intraoperative changes to suggest any insult. Prompt neurology consultation and medical treatment was helpful in this patient's recovery.

Conclusion

We present the first reported case of PICA injury from C1 lateral mass screw placement, with resultant stroke secondary to aberrant artery anatomy. We present this to raise awareness of this anatomic variant and the postoperative symptoms associated with this injury. Advanced imaging in the form of a CTA or possibly an MRA can be considered in preoperative planning to reduce the risk of this complication.

References

- [1] Sonntag VK, Volker KH. Lateral mass screw fixation of the atlas: importance of anatomy of C1 for lateral mass screw placement. *World Neurosurg* 2010;74:270–1.
- [2] Lall R, Patel NJ, Resnick DK. A review of complications associated with craniocervical fusion surgery. *Neurosurgery* 2010;67:1396–402.
- [3] Wang S, Wang C, Liu Y, et al. Anomalous vertebral artery in cranio-vertebral junction with occipitalization of the atlas. *Spine* 2009;34:2838–42.

- [4] Currier BL, Todd LT, Maus TP, et al. Anatomic relationship of the internal carotid artery to the C1 vertebra: a case report of cervical reconstruction for chordoma and pilot study to assess the risk of screw fixation of the atlas. *Spine* 2003;28:E461–7.
- [5] Lasjaunias P, Vallee B, Person H, et al. The lateral spinal artery of the upper cervical spinal cord: anatomy, normal variation, angiographic aspects. *J Neurosurg* 1985;63:235–41.
- [6] Fine AD, Cardoso A, Rhoton AL Jr. Microsurgical anatomy of the extracranial-extradural origin of the posterior inferior cerebellar artery. *J Neurosurg* 1999;91:645–52.
- [7] Akar ZC, Dujovny M, Slavin KV, et al. Microsurgical anatomy of the intracranial part of the vertebral artery. *Neurol Res* 1994;16:171–80.
- [8] Warren DT, Warren MD, Malfair D, Akagami R. An incidence of antero-inferior cerebellar artery/postero-inferior cerebellar artery anatomic variants penetrating the subarcuate fossa dura: operative technique and identification with 3-dimensional fast imaging employing steady-state acquisition magnetic resonance imaging. *Neurosurgery* 2010;66:199–203.
- [9] Saylam C, Ucerler H, Orhan M, et al. The relationship of the posterior inferior cerebellar artery to cranial nerves VII–XII. *Clin Anat* 2007;20:886–91.
- [10] Brinjikji W, Cloft H, Kallmes DF. Anatomy of the posterior inferior cerebellar artery: relevance for C1–C2 puncture procedures. *Clin Anat* 2009;22:319–23.
- [11] Robertson HJ, Smith RD. Cervical myelography: survey of modes of practice and major complications. *Radiology* 1990;174:79–83.
- [12] Vincentelli F, Caruso G, Rabehanta PB, et al. Surgical treatment of a rare congenital anomaly of the vertebral artery: case report and review of the literature. *Neurosurgery* 1991;28:416–20.
- [13] Sharma R, Parekh H, Prabhu S, et al. Compression of the C-2 root by a rare anomalous ectatic vertebral artery. *J Neurosurg* 1993;78:669–72.
- [14] Tokuda K, Myasaka K, Abe H, et al. Anomalous atlantoaxial portions of vertebral and posterior inferior cerebellar arteries. *Neuroradiology* 1985;27:410–3.
- [15] Lasjaunias P, Theron J, Moret J. The occipital artery. Anatomy-normal arteriographic aspects-embryologic significance. *Neuroradiology* 1978;15:31–7.
- [16] Lui CC, Liu YH, Wai YY, Tsa CC. Persistence of both proatlantal arteries with absence of vertebral arteries. *Neuroradiology* 1987;29:304–5.
- [17] Yamazaki M, Koda M, Aramomi M, et al. Anomalous vertebral artery at the extraosseous regions of the craniovertebral junction: analysis by three-dimensional computed tomography angiography. *Spine* 2005;30:2452–7.
- [18] Fukuoka T, Takeda H, Dembo T, et al. Clinical review of 37 patients with medullary infarction. *J Stroke Cerebrovasc Dis* 2012;21:594–9.