

NOTE

MIXED TRANSCORTICAL APHASIA. ON RELATIVE SPARING OF PHONOLOGICAL SHORT-TERM STORE IN A CASE

L. TROJANO, N. A. FRAGASSI, A. POSTIGLIONE* and D. GROSSI†

Istituto per lo Studio delle Malattie del Sistema Nervoso, II Facoltà di Medicina, Napoli, Italy; and *Istituto di Medicina Interna e delle Malattie Metaboliche, II Facoltà di Medicina, Napoli, Italy

(Received 2 October 1987; accepted 25 October 1987)

Abstract—A case of Mixed Transcortical Aphasia is reported. The patient showed completely impaired verbal comprehension and speech production, with preservation of automatic speaking and singing; repetition was relatively spared. A detailed study of word and nonword repetition is reported, in order to demonstrate that the patient's residual repetition ability is based on relative sparing of short-term phonological store.

INTRODUCTION

TRANSCORTICAL Aphasia is the term used for syndromes in which repetition is preserved despite marked reduction of spontaneous speech or gross impairment of comprehension or both. Following the model provided by LICHTHEIM [8], Transcortical Aphasia can be classified into three types: Sensory, with paraphasic fluent speech, poor comprehension, and good repetition; Motor, with non-fluent speech, and preserved understanding and repetition; Mixed Transcortical Aphasia in which speech and comprehension are severely impaired, and repetition is the only possible linguistic performance, together with the "completion" of well-learned automatic phrases.

Mixed Transcortical Aphasia is not a frequent finding, and few cases have been described since Goldstein defined the condition in 1917 [1, 6, 9].

GESCHWIND *et al.* [4] reported a clinical-anatomical and post-mortem neuropathological study of a patient with Mixed Transcortical Aphasia, induced by diffuse cortical and sub-cortical lesions, caused in turn by carbon monoxide poisoning. The patient's linguistic performance was typical of Mixed Transcortical Aphasia. During the 9 yr of her illness, she gave no evidence that she could understand verbal commands, nor did she pronounce propositional speech; spontaneous speech was limited to several stereotyped exclamations, to the repetition of phrases or parts of phrases uttered by the examiner. She also showed the "completion" phenomenon of automatic phrases described by STENGEL [11], and was able to learn both words and music of songs. At post-mortem, the areas of Broca and Wernicke and the arcuate fasciculus were intact, which confirms GOLDSTEIN's [5] "isolation of the speech area" theory.

HEILMAN *et al.* [6] described a patient with Mixed Transcortical Aphasia, apparently due to an ischemic ictus in the left carotid district, who showed the ability to name objects and figures, a performance not compatible with Lichtheim's model. The authors proposed a mechanism for linguistic processes that could explain this unusual behaviour.

Lastly, ROSS [9] reported a case of Mixed Transcortical Aphasia caused by an ictus of the anterior cerebral artery, with damage extending to medial portion of the parietal and frontal lobes. A comparison with lesions observed in two cases of Motor Transcortical Aphasia led the authors to argue that the sensory supplementary area of the left medial parietal lobe was of critical importance for language.

Here we report a case of Mixed Transcortical Aphasia and describe its neuropsychological characteristics, in particular, repetition. Differently from echolalia, which is seen as a sign that cortical control of reflex mechanisms has ceased [7], repetition in cases of Mixed Transcortical Aphasia has not been previously studied in detail (only

†Correspondence to be addressed to: Dr Dario Grossi, Clinica Neurologica Ed. 17, Nuovo Policlinico, via S. Pansini 5, 80131 Napoli, Italy.

ASSAL *et al.* [1] reported some quantitative data). Our aim was to study the main mechanisms underlying repetition in a case in which we could reasonably think that there is no access to lexicon, which in normal subjects plays a relevant role. Our working hypothesis is that repetition in this aphasic syndrome occurs through a spared phonological short term store that is able to maintain phonemes for a limited period [12]. Under these conditions we studied the effect of meaningful and meaningless verbal stimuli on repetition; we expected the patient to be able to repeat either words or nonwords, because of the insensitivity of the phonological store to meaningful stimuli.

CASE HISTORY

The patient was a 69 yr-old female, right-handed, with low schooling, with a 10 yr history of hypertension. On 13 March 1985, she suffered a myocardial infarct, and 10 days later she suddenly presented right hemiparesis and global aphasia. On 28 March 1985, she was admitted to our Institute, where the neurologic examination showed central paresis of the right facial, right hemihypostenia, mainly crural, and spastic laugh. EEG showed signs of severe suffering in the deep left temporal region.

Because of the aphasic disturbance, the patient came under our observation about 1 month after the onset of the illness. Neuropsychological study demonstrated that the repetition was the only possible linguistic performance, together with a few automatic expressions. Neuropsychological study was repeated on November 1986, and it remained unchanged; at this time a detailed examination of repetition was conducted. CT scan, performed in this occasion, showed cortical and subcortical atrophy, mainly in the left hemisphere, and a wide hypodensity in left frontal-parietal-temporal region. Magnetic Resonance Tomography confirmed CT scan report, and, moreover, revealed a small ischemic area in left occipital lobe and three small areas in right periventricular region (Fig. 1).

The patient always presented smiling, and nodded to the remarks uttered by the examiner. She showed she recognized the examiner by increasing the smile and exaggerating her facial expression; on the contrary, she had a puzzled expression when confronted with a new examiner. Echolalia was often present for the last word spoken by the examiner. She was able to pronounce a few fragmentary syllables, neologisms and a few dialectal expressions which she used iterately. She was able to continue singing when the beginning of a song was suggested to her; she proceeded without difficulty and was able to remember both the words and the music. In particular, she was able to sing several traditional Neapolitan and religious songs, and even recent songs. Occasionally she stopped singing, and if prompted she would continue. She was also able to recite prayers. Moreover she could utter complete automatic sentences when prompted with the beginning (e.g.: "Buon . . ." [= Good], the patient completed ". . . giorno" [= morning]; "Lei come . . ." [= What's] she completed ". . . si chiama?" [= your name?]).

Oral comprehension was practically non-existent. The patient was unable to comply with even simple verbal commands. However, she could comply with requests if they were proposed by gesture. On occasions, she was able to grasp a word or a phrase, which she repeated continuously, but without showing understanding of its meaning.

Figure naming was impossible because the patient spontaneously and automatically named the first figure shown, and then continuously repeated that word.

Reading out was impossible, and written messages were not understood. Writing was reduced to a few difficult to decipher words, that were exclusively automatic (name and surname, "Mamma" [= Mum] and "casa" [= home]). Word copying was relatively intact.

It was difficult to evaluate the verbal span, for words and numbers, because the patient would repeat the first item presented and ignore the following words proposed by the examiner. Nevertheless, we succeeded to limit her tendency and finally we obtained a verbal span of two items. After much effort to explain the task, the patient scored 2 on Corsi's block tapping test.

Aim of the study of repetition was to obtain quantitative and qualitative data, regarding words and nonwords, on the basis of our working hypothesis. We prepared a list of 70 words (nouns and verbs), balanced for frequency and length, and a list of 108 nonwords, balanced for length and phonemic distance from the words. The session was recorded and the patient's replies were classified as follows: (A) *exact repetition*: when the repetition was identical to the stimulus; (B) *repetition similar to the stimulus*: when the response differed from the stimulus in only one feature. In this group we included: (1) in words beginning with a vowel, when the patient omitted the first vowel or added a consonant at the beginning of the word—an error that may be attributed to an articulatory disturbance (e.g.: "impeto"—"vimpeto"); (2) end fragments of words, when the patient repeated only part of a word (e.g.: "divento"—"ventó"); (3) single phonemic paraphasias, when the patient substituted one letter (e.g.: "rango" "ranco"); (C) *non-related repetitions*: when the repetition was unrecognizable, either because of the substitution of several letters, or because the repetition was unrelated to the presented stimulus.

Repetition of nonwords was divided into the same categories; in addition, the lexicalization error was taken into account.

Results of the study of the repetition are shown in Tables 1 and 2.

Type B errors for words consisted mainly in paraphasias (16/29): of these, 10 were substitutions of couples of letters with the same articulatory point (e.g.: p b, c g), and six were substitutions without articulatory relationship. The repetition of end fragments of words [4] occurred only with longer words (two with seven letter words, two with eight letter words).

The number of type C errors was low.

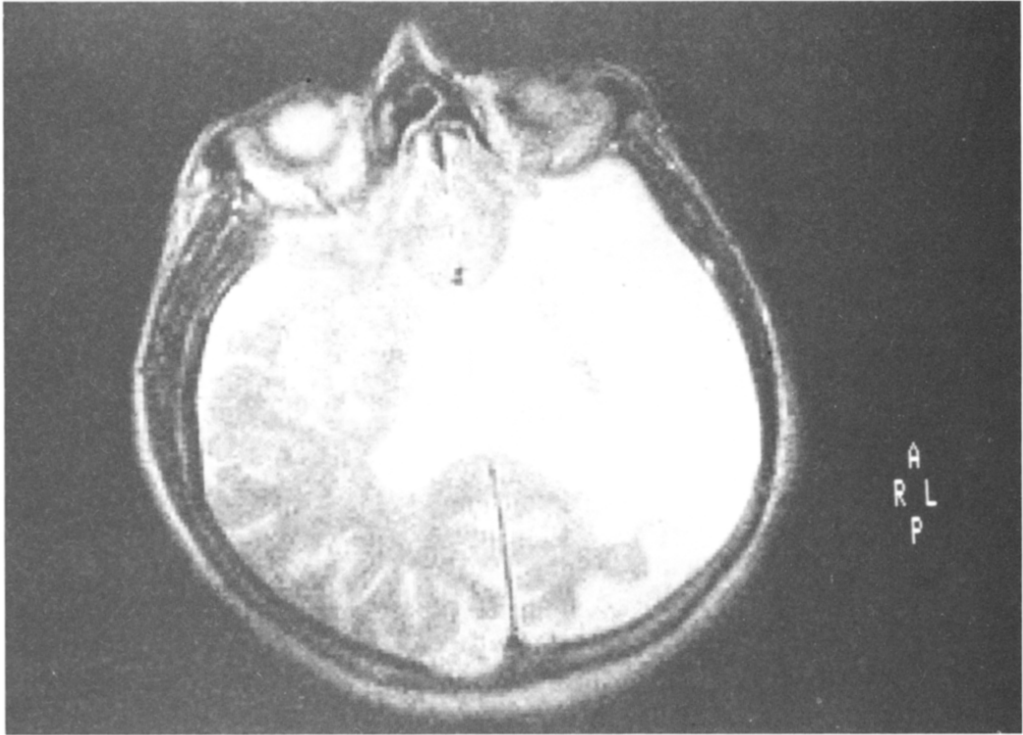


FIG. 1.

Table 1. Word repetition

(A) Exact repetitions	31/70 (44.3%)
High frequency words	19/35
Low frequency words	12/35
Four letter words	5/14
Five letter words	9/14
Six letter words	5/14
Seven letter words	6/14
Eight letter words	6/14
(B) Similar to the stimulus repetitions	29/70 (41.4%)
Words beginning with a vowel	9
End fragments of words	4
Phonemic paraphasias	16
(C) Non-related repetitions	10/70 (14.2%)
Multiple substitutions	8
Unrecognizable	2

Table 2. Nonword repetitions

(A) Exact repetitions	29/108 (26.9%)
Four letter nonwords	11/20
Five letter nonwords	6/22
Six letter nonwords	6/22
Seven letter nonwords	4/22
Eight letter nonwords	2/22
(B) Similar to the stimulus repetitions	53/108 (49.1%)
Nonwords beginning with a vowel	12
End fragments	6
Phonemic paraphasias	35
(C) Non-related repetitions	17/108 (15.7%)
Multiple substitutions	16
Unrecognizable	1
(D) Lexicalizations	9/108 (8.3%)

Paraphasias were the most represented type B errors also for nonwords [35/53]: however, in this case, substitutions of couples of articulatorily similar letters [13] were fewer than substitutions without articulatory relationship [21]. Again, repetition of the last parts of words occurred with the longer items (one with five letter nonwords, two with seven letter items, three with eight letter items).

COMMENT

The patient described was affected by Mixed Transcortical Aphasia. In fact she presented classical symptoms of this syndrome: completely impaired verbal comprehension and speech production, with preservation of automatic speaking and singing ability; repetition was relatively spared.

The patient was similar to those reported by Geshwind and by Ross, but she differed from that reported by Heilman, because she could not name objects. Moreover, her syndrome was more severe than those described, because she could only repeat little fragments of sentences, and never whole sentences, she showed some articulatory disturbances, was not able to read, and had a poor immediate memory span.

Repetition task showed a large number of correct and "almost correct" responses; in our opinion, many of these "almost correct" responses (type B errors) are articulatory in nature, and articulatory defect is easy to admit because of the syndrome severity.

Non-correlated repetitions were very few, for both types of stimuli; this performance seems excellent, especially if one takes into account that the patient never refused to repeat. It must be remembered that a patient with global aphasia is completely unable to carry out a repetition task. Lastly, lexicalizations were few, while being more represented in other aphasia syndromes; it indirectly confirms the impairing of the lexicon access.

Data inspection shows a better performance for words than for nonwords; moreover a striking length-effect was evident for nonwords. Another difference that must be noted between word- and nonword-repetition is the pattern of paraphasic type B errors: in word repetition they were mainly articulatory, in nonword repetition they were genuine selection paraphasias. These considerations suggest that familiar stimuli (words), even if they cannot evoke specific meanings, undergo some kind of facilitation that unfamiliar stimuli do not.

DISCUSSION

Our working hypothesis foresaw that in Mixed Transcortical Aphasia the repetition was based on short-term phonological store, relatively spared in comparison to other, totally impaired, linguistic functions. In fact, the reproduction of orally presented stimuli necessarily must presume the temporary storing of coded phonemes in a short term store for successive articulation. Our idea was that the patient processed spoken words only as clusters of phonemes, because she could not have access to lexicon; thus, she could reproduce both words and nonwords, because meaningful and meaningless stimuli could be reproduced by means of the same mechanisms. The working hypothesis was demonstrated because the patient was able to repeat words and nonwords; nevertheless, nonwords were reproduced less accurately and showed a clear "length effect".

We interpreted this result in the following way: sequences of phonemes, corresponding to words, activate pre-arranged programmes at the articulatory system level, that thus are able to store traces of words as "sounds", dissociated from their meaning. Vice versa unfamiliar clusters of phonemes activate an articulatory sequence point-by-point; this makes the reproduction process liable to errors and can explain the "length effect".

The relative sparing of short-term phonological store does not presume a normal verbal memory span; in fact, the efficiency in this task is also connected to the functioning of rehearsal processes, that are means of maintaining traces which may otherwise fade [10]. We retain that rehearsal processes are impaired in our patient who in fact showed pathological spans, only corresponding to the phonological store capacity. The store thus can work with minimal effort, even dissociated from more complex linguistic architecture. This is a more simple function that is impaired only if his specific neuronal substratum is damaged.

Echolalia, one of the clinical features of this kind of aphasia, is explained as the spontaneous and afixalistic activation of this mechanism: in this sense its relative sparing is included in relative sparing of other automatisms, that characterize this severe aphasic syndrome.

REFERENCES

1. ASSAL, G., REGLI, F., THUILLARD, F., STECK, A., DERUAZ, J. P. and PERENTES, E. Syndrome d'isolement de la zone du langage. Etude neuropsychologique et pathologique. *Revue Neurologique* **139**, 417-424, 1983.
2. BOGOUSSLAVSKY, J., REGLI, F. and ASSAL, G. Isolation of speech area from focal brain ischemia. *Stroke* **16**, 441-443, 1985.
3. BROWN, J. W. The problem of repetition: a study of "conduction" aphasia and the "isolation" syndrome. *Cortex* **11**, 37-52, 1975.
4. GESCHWIND, N., QUADRESE, F. A. and SEGARRA, J. M. Isolation of the speech area. *Neuropsychologia* **6**, 327-340, 1968.
5. GOLDSTEIN, K. Die transcorticalen Aphasien. *Erg. d. Neur. u. psychiatr.* **2**, 349-629, 1917.
6. HEILMAN, K. M., TUCKER, D. M. and VALENSTEIN, E. A case of mixed transcortical aphasia with intact naming. *Brain* **99**, 415-426, 1976.
7. KORNVEY, E. Aphasie transcorticale et echolalie: le problème de l'initiative de la parole. *Revue Neurologique* **5**, 347-363, 1975.
8. LICHTHEIM, L. On aphasia. *Brain* **7**, 433-484, 1885.
9. ROSS, E. D. Left medial parietal lobe and receptive language functions: mixed transcortical aphasia after left anterior cerebral artery infarction. *Neurology* **30**, 144-151, 1980.
10. SALAMÉ, P. and BADDELEY, A. D. Disruption of short-term memory by unattended speech: implication for the structure of working memory. *J. Verb. Learn. Verb. Behav.* **21**, 150-164, 1982.
11. STENGL, E. A clinical and psychological study of echo reactions. *J. Mental Sciences* **93**, 598-612, 1947.
12. VALLAR, G. and BADDELEY, A. D. Fractionation of working memory: neuropsychological evidence for phonological short-term store. *J. Verb. Learn. Verb. Behav.* **23**, 151-161, 1984.