

[Click for updates](#)

## Neurocase: The Neural Basis of Cognition

Publication details, including instructions for authors and subscription information:

<http://www.tandfonline.com/loi/nncs20>

### Improvement of language functions in a chronic non-fluent post-stroke aphasic patient following bilateral sequential theta burst magnetic stimulation

Jasmina Vuksanović<sup>ab</sup>, Milan B. Jelić<sup>a</sup>, Sladjan D. Milanović<sup>a</sup>, Katarina Kačar<sup>c</sup>, Ljubica Konstantinović<sup>de</sup> & Saša R. Filipović<sup>a</sup>

<sup>a</sup> Department of Neurophysiology, Institute for Medical Research, University of Belgrade, Beograd, Serbia

<sup>b</sup> Department for Philosophy (Psychology), State University of Novi Pazar, Novi Pazar, Serbia

<sup>c</sup> Radiology Department, Special Hospital for Cerebrovascular Diseases "Sveti Sava", Belgrade, Serbia

<sup>d</sup> Klinika za Rehabilitaciju "Dr Miroslav Zotović", Belgrade, Serbia

<sup>e</sup> Department of Rehabilitation, Faculty of Medicine, University of Belgrade, Belgrade, Serbia

Published online: 03 Mar 2014.

To cite this article: Jasmina Vuksanović, Milan B. Jelić, Sladjan D. Milanović, Katarina Kačar, Ljubica Konstantinović & Saša R. Filipović (2015) Improvement of language functions in a chronic non-fluent post-stroke aphasic patient following bilateral sequential theta burst magnetic stimulation, *Neurocase: The Neural Basis of Cognition*, 21:2, 244-250, DOI: [10.1080/13554794.2014.890731](https://doi.org/10.1080/13554794.2014.890731)

To link to this article: <http://dx.doi.org/10.1080/13554794.2014.890731>

PLEASE SCROLL DOWN FOR ARTICLE

Taylor & Francis makes every effort to ensure the accuracy of all the information (the "Content") contained in the publications on our platform. However, Taylor & Francis, our agents, and our licensors make no representations or warranties whatsoever as to the accuracy, completeness, or suitability for any purpose of the Content. Any opinions and views expressed in this publication are the opinions and views of the authors, and are not the views of or endorsed by Taylor & Francis. The accuracy of the Content should not be relied upon and should be independently verified with primary sources of information. Taylor and Francis shall not be liable for any losses, actions, claims, proceedings, demands, costs, expenses, damages, and other liabilities whatsoever or howsoever caused arising directly or indirectly in connection with, in relation to or arising out of the use of the Content.

This article may be used for research, teaching, and private study purposes. Any substantial or systematic reproduction, redistribution, reselling, loan, sub-licensing, systematic supply, or distribution in any form to anyone is expressly forbidden. Terms & Conditions of access and use can be found at <http://www.tandfonline.com/page/terms-and-conditions>

## Improvement of language functions in a chronic non-fluent post-stroke aphasic patient following bilateral sequential theta burst magnetic stimulation

Jasmina Vuksanović<sup>a,b</sup>, Milan B. Jelić<sup>a</sup>, Sladjan D. Milanović<sup>a</sup>, Katarina Kačar<sup>c</sup>, Ljubica Konstantinović<sup>d,e</sup>  
and Saša R. Filipović<sup>a\*</sup>

<sup>a</sup>Department of Neurophysiology, Institute for Medical Research, University of Belgrade, Beograd, Serbia; <sup>b</sup>Department for Philosophy (Psychology), State University of Novi Pazar, Novi Pazar, Serbia; <sup>c</sup>Radiology Department, Special Hospital for Cerebrovascular Diseases “Sveti Sava”, Belgrade, Serbia; <sup>d</sup>Klinika za Rehabilitaciju “Dr Miroslav Zotović”, Belgrade, Serbia; <sup>e</sup>Department of Rehabilitation, Faculty of Medicine, University of Belgrade, Belgrade, Serbia

(Received 9 May 2013; accepted 27 December 2013)

In chronic non-fluent aphasia patients, inhibition of the intact right hemisphere (RH), by transcranial magnetic stimulation (TMS) or similar methods, can induce improvement in language functions. The supposed mechanism behind this improvement is a release of preserved left hemisphere (LH) language networks from RH transcallosal inhibition. Direct stimulation of the damaged LH can sometimes bring similar results too. Therefore, we developed a novel treatment approach that combined direct LH (Broca's area (BA)) stimulation, by intermittent theta burst stimulation (TBS), with homologue RH area's inhibition, by continuous TBS. We present the results of application of 15 daily sessions of the described treatment approach in a right-handed patient with chronic post-stroke non-fluent aphasia. The intervention appeared to improve several language functions, but most notably propositional speech, semantic fluency, short-term verbal memory, and verbal learning. Bilateral TBS modulation of activation of the language-related areas of both hemispheres seems to be a feasible and promising way to induce recovery in chronic aphasic patients. Due to potentially cumulative physiological effects of bilateral stimulation, the improvements may be even greater than following unilateral interventions.

**Keywords:** aphasia; transcranial magnetic stimulation; rehabilitation; interhemispheric interaction; propositional speech; verbal learning; semantic fluency; language; stroke

Aphasia is a common consequence of strokes affecting structures in the language-dominant (usually left) cerebral hemisphere (Dronkers & Larsen, 2001). Most patients show some degree of spontaneous recovery of language function, typically during the first 2–3 months following a stroke (Laska, Hellblom, Murray, Kahan, & Von, 2001). However, the amount of recovery varies greatly (Lazar & Antonello, 2008) and a number of patients are left with lasting impairment of language functions in spite of receiving speech therapy (Kelly, Brady, & Enderby, 2010).

Language recovery after stroke is critically dependent on the degree and pattern of compensatory plastic changes in cerebral hemispheres taking place in the post-stroke period (Thompson, 2000). Noninvasive brain stimulation (NBS) interventions, such as transcranial magnetic stimulation (TMS) and transcranial direct current stimulation (tDCS), can be used to promote plastic changes in brain recovery (Miniussi et al., 2008). In relation to the language system, there is an evidence that such interventions can have a positive impact on a number of language functions in both healthy individuals and aphasic patients (Hamilton, Chrysikou, & Coslett, 2011; Mylius, Zouari, Ayache, Farhat, & Lefaucheur, 2012; Schlaug, Marchina, & Wan, 2011).

Most of the published NBS studies in post-stroke aphasia have been based on a widely accepted view that for the *long-term recovery of language*, a reactivation of undamaged network areas of the ipsilateral hemisphere is more efficient than the involvement of homologue contralateral regions (Heiss & Thiel, 2006). Decreased activity in contralesional areas following an inhibitory NBS treatment should cause interhemispheric transcallosal inhibition toward the lesioned side to diminish, thus permitting activity in lesioned or perilesioned areas to increase, which eventually should lead to improvement in language functions. An alternative option, a direct facilitation of the lesioned and perilesioned areas, has been tried in only a handful of cases (e.g. Baker, Rorden, & Fridriksson, 2010) due to various safety and methodological issues, the most important ones being risk of seizures and exact determination of the area to stimulate. Even so, it is still unknown whether direct stimulation of the lesioned hemisphere coupled with inhibition of homologue contralateral areas might bring similar or even greater effects.

Moreover, verbal memory and verbal learning are usually impaired together with language loss in aphasia (Burgio & Basso, 1997; Schouten, Schiemanck, Brand, & Post, 2009). However, the effects of NBS on verbal

\*Corresponding author. Email: [sasa.filipovic@imi.bg.ac.rs](mailto:sasa.filipovic@imi.bg.ac.rs)

memory and learning in chronic aphasic patients have not been investigated in detail yet.

Therefore, we developed a TMS-based treatment procedure designed to inhibit the right Broca's area homologue (BAh) and subsequently to facilitate Broca's area (BA). The procedure was developed in keeping with the hypothesis of a maladaptive right hemisphere (RH) over-activation in chronic aphasia patients and a need to promote the reappearance of functions in the left hemisphere (LH) to achieve proper language recovery. In this study, we report the effects of 15 consecutive daily applications of the treatment on language deficits and verbal memory in a right-handed patient with chronic non-fluent aphasia.

## Methods

### Case history

The patient was a 63-year-old monolingual Serbian-speaking right-handed man with 12 years of formal education who worked as a telecommunication technician before his stroke. Seventeen months before participation in this study, he suffered an ischemic stroke in the left middle cerebral artery territory, which caused damage in the left frontotemporoparietal white matter but with relative sparing of cortical gray matter (Figure 1). The stroke left him with right hemiparesis and severe non-fluent aphasia (one monosyllabic word phrase length in spontaneous and/or on-demand language production). During the first 2 months following the stroke, he had an initial rehabilitation program, including speech and language therapy, at a specialized residential rehabilitation facility. This was

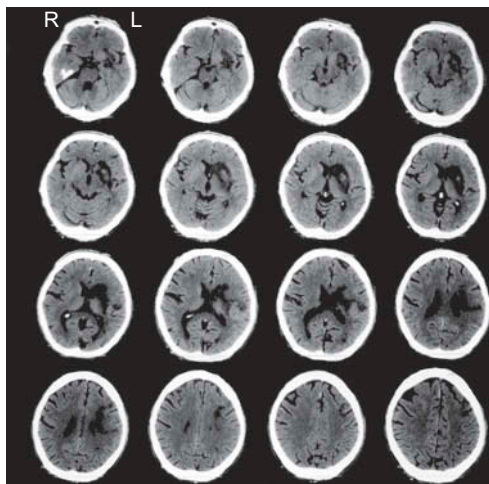


Figure 1. CT scan, carried out a week after the stroke, showed ischemic lesions in the left basal ganglia, extending into periventricular and supraventricular white matter, with hemorrhagic transformation within the area of lentiform nucleus, but with relative sparing of the cortical gray matter. Sides are positioned according to medical imaging convention; the left side of the brain is on the right image side.

followed by fairly regular physiotherapy sessions at a community medical center. He has regained considerable mobility of his right limbs, and at the time he entered the study, he had only mild right hemiparesis. His modified Rankin scale score was 3, and average Medical Research Council (MRC) score (across all muscle groups) for the right upper limb was 1.9. However, his speech has recovered poorly and he presented with severe non-fluent aphasia, which was little different than it was in the acute phase.

The patient had not had previous strokes or transient ischemic attacks. Twenty years earlier, he suffered an injury of the right hip for which he had a metal prosthesis implanted. The metal in his hip prevented carrying out MRI scanning.

Here, we present results of the language function and verbal memory assessments, first carried out a few days before the first (initial) TMS treatment session (baseline test – T0), and from two retests. One retest (T1) was within a week of completing the TMS treatment (i.e. 4 weeks following the T0), and another retest (T2) took place 2 months later. The study was approved by the local Ethics Committee and the patient gave his written informed consent.

### Language function assessment

For language function assessment, the Boston Naming Test (BNT) (Kaplan, Goodglass, & Weintraub, 1983) and several subtests of the Boston Diagnostic Aphasia Examination (BDAE) (Goodglass & Kaplan, 1983) were used. To limit the strain on the patient, the selection of BDAE subtests was limited to propositional speech (Cookie Theft picture description task), repetition, auditory comprehension, and semantic verbal fluency (number of animal names generated within a 2-min period).

### Verbal memory and learning assessment

*The Rey Auditory Verbal Learning Test* (RAVLT) (Lezak, Howieson, & Loring, 2004) was used for verbal memory and learning assessment. The test consists of two parallel sets of 15-noun lists (A and B). First, list A was presented five times in a row, each time followed by free recall, (A1, A2, A3, A4, A5), then, list B (interference) was presented followed by free recall (B1). After a 20-min interval, the subject was asked to recall list A (A6), and finally, after another 20-min delay, A list was recalled again (A7). For all recall tasks, the number of correct words recalled from the presented word list (either A or B) was taken as the task's score. Several different sets of stimuli (i.e. lists A and B) were used to eliminate the effects of repetition on the test.

### TMS treatment protocol

TMS was applied through a 70-mm-diameter figure-of-eight coil using Magstim Rapid magnetic stimulator (Magstim,

Whitland, UK). The treatment intervention consisted of the so-called theta burst stimulation (TBS) (Huang, Edwards, Rounis, Bhatia, & Rothwell, 2005) in which bursts consisting of 3 TMS pulses given at 50-Hz rate are repeated every 200 ms (i.e. with frequency of 5 Hz). The TMS pulse intensity was set to be at 80% of the active motor threshold (AMT) obtained from the RH. The AMT for the RH primary motor cortex was established according to published criteria (Rothwell et al., 1999). Due to the stroke, the AMT values for the LH were too high to be used. Two types of TBS were used: (1) facilitatory intermittent TBS (iTBS), consisting of 2-s trains of TBS followed by 8-s rest, which was repeated 20 times for a total of 200 s (i.e. 600 pulses); and (2) inhibitory continuous TBS (cTBS), consisting of a 40-s train of uninterrupted TBS (i.e. 600 pulses). First, the cTBS was delivered over RH BA<sub>H</sub>, and then immediately after, iTBS was delivered over LH BA. For scalp projections of the BA and the BA<sub>H</sub>, F7 and F8 sites of the 10–20 International EEG electrode positioning system (Klem, Luders, Jasper, & Elger, 1999) were used; the two sites were found to correspond reliably enough with pars triangularis of the inferior frontal gyrus (Brodmann area 45) (Koessler et al., 2009; Okamoto et al., 2004), the cortical region that forms a part of the BA and the BA<sub>H</sub>, respectively. Prior studies of TMS in aphasia showed that enhancements of language ability were associated specifically with stimulation of the pars triangularis area (e.g. Naeser et al., 2011).

## Results

### Language functions

The BNT score at the baseline (T0) was 17, considerably below the published norms (Tombaugh & Hubiey, 1997). Following the TMS treatment, it increased slightly to 19 at

T1 and increased again to 21 at T2. However, major improvement was observed in some of the BDAE subtests that were used (Table 1), particularly in propositional elicited speech. The number of words per longest phrase, which was a meager 2 at T0, increased to 6 at T1, with further increase to 8 at T2. The mean number of words per sentence increased as well, from only 2 at T0 to 6 at T2. The number of sentences dramatically increased also, from only 3 at T0 to 10 at T1, with slight decrease to 8 at T2. In addition, the performance on semantic verbal fluency task increased, particularly at T2 where it was 10, a 100% higher than at T0 where it was only 5. In addition to these results, auditory comprehension was generally improved. The number of discriminated words increased from 49 at T0 to 65 at T1, followed by a slight decrease to 54 at T2. The number of correct commands performed increased from 8 at T0 to 14 at both T1 and T2.

### Verbal memory and learning

All scores, apart from the delayed recall task score (A7), increased after the TMS treatment, at T1 (Figure 2). Unfortunately, due to time restrictions imposed on the patient by sudden family problems, we were not able to carry out a planned verbal memory evaluation at T2.

The total number of correct words recalled immediately after the first reading of list A (A1) increased from 2 at T0 to 4 at T1. Verbal learning improved proportionally more. At the end of the learning curve, following the fifth presentation of the list A (A5), the patient was able to correctly recall only five list A words at T0, but this increased by 100%, to 10 at T1. The total number of correct words recalled across the first five trials ( $\sum A_{1-5}$ ) increased from 25 at T0 to 32 at T1 (a 28% increase

Table 1. Primary outcome measures, Boston Naming Test (BNT) and selected Boston Diagnostic Aphasia Examination (BDAE) scores, before (T0), a week after (T1), and 2 months after (T2) the TMS treatment.

Testing material	T0	T1	T2
BNT score (max = 60)	17	19	21
BDAE scores:			
(1) Semantic verbal fluency	5	6	10
(2) Spontaneous speech (Cookie Theft picture description)			
Longest number of words per phrase length	2	6	8
Mean number of words per phrase length	2	5	6
Number of sentences	3	10	8
Articulatory agility (max = 8)	4	5	7
(3) Auditory comprehension			
Word discrimination (max = 72)	49	65	54
Commands (max = 15)	8	14	14
Complex ideational material (max = 12)	6	7.5	7.5
(4) Repetition			
Single words (max = 10)	7	9	10
High probability sentences (max = 8)	7	8	8
Low probability sentences (max = 8)	2	4	4

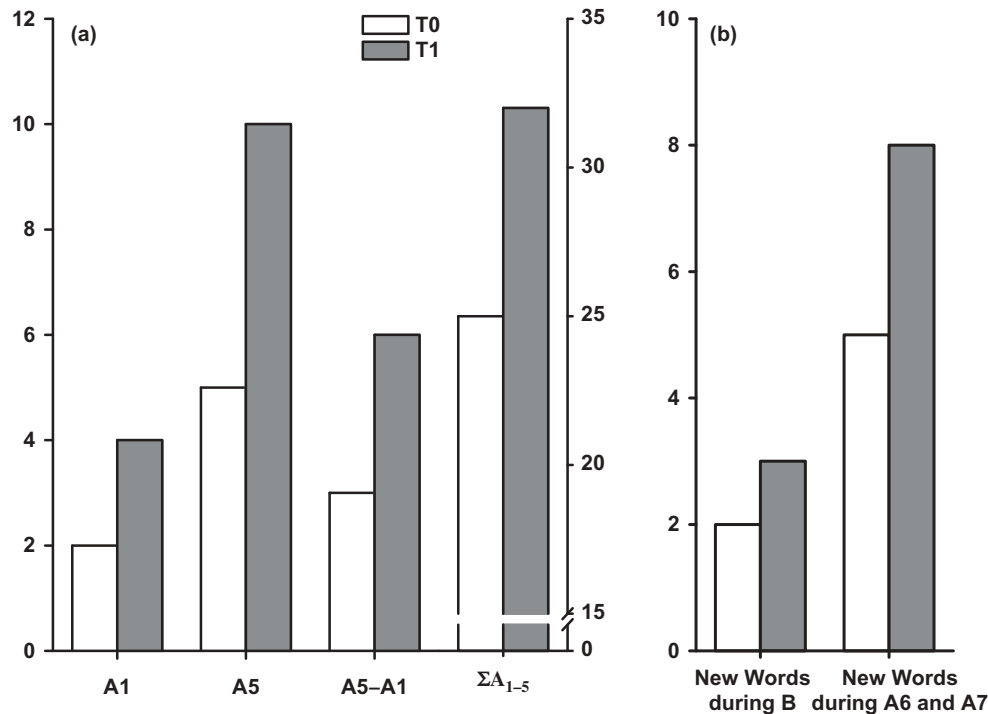


Figure 2. Results of the Rey Auditory Verbal Learning Test (RAVLT) before (T0) and after (T1) the TMS treatment. (a) Verbal learning and memory indices. The number of correct words recalled from the relevant word list (A or B) was taken as the task's score. The A1 score was used as a measure of short-term memory. The A5 score, the A5–A1 score difference, and the sum of scores across A1 to A5 ( $\Sigma A_{1-5}$ ), were used as measures of verbal learning. The first three measures refer to the left Y-axis, the fourth measure refers to the right Y-axis. (b) Numbers of non-list words during list B recall and during 6th and 7th recall of A list.

compared to T0). The learning score ( $rA5-rA1$  difference) increased also, from 3 at T0 to 6 at T1 (a 100% increase compared to T0). The patient's retrieval of list B words (B1) increased also, from 0 at T0 to 4 at T1. Long-term retention (A6) improved slightly, from 3 at T0 to 4 at T1. However, delayed recall (A7) did not change and remained 4 throughout.

Regarding the derivative measures, the number of intrusions of list A words into list B recall stayed low, it was 1 at T0 and at T1, signaling a low level of proactive interference effect. On the other hand, the number of intrusions of list B words into A6 remained 0 throughout, indicating consistent lack of retroactive interference effect. In keeping with the latter, the A6 score, as an indirect indicator of retroactive interference, remained relatively stable across the testing sessions.

In addition, qualitative analyses of B1, A6 and A7 answers, showed that the patient, in an attempt to retrieve existing words from the lists, produced many new non-list words that shared either phonological or semantic features with the existing words; e.g. a non-list word *children* as a semantic analog to the list word *parent*; a non-list word *arm* (*ruka* in Serbian [pronounced as *rookah*]) as a phonological analog to the list word *river* (*reka* in Serbian [pronounced as *rekah*]). This tendency increased after the

TMS treatment (at T1) for both, list A and list B words, but was considerably more expressed for list A words (Figure 2b).

## Discussion

Increased activation of RH regions, homologue to the lesioned LH language areas, typically encountered in chronic aphasic post-stroke patients, was found to be not only associated with unsuccessful or deficient recovery of language performance (Crosson et al., 2007; Saur & Hartwigsen, 2012) but also supposed to strongly inhibit activity in the remaining language-related LH structures (Heiss & Thiel, 2006).

Several reports have been published on the beneficial effects of NBS treatments on the language functions of chronic aphasic patients (reviewed in Hamilton et al., 2011; Mylius et al., 2012; Schlaug et al., 2011). However, all attempts so far have used unilateral application of either TMS or tDCS; in most cases the undamaged RH was targeted with inhibitory protocols, while in only a handful of cases a direct modulation of LH structures was attempted.

In this report, we present the results of an NBS treatment, applied in a bilateral sequential and potentially



physiologically cumulative manner, in a chronic non-fluent aphasic patient. We aimed to explore whether this novel approach could bring about improvement in language performance similar or even greater than improvements that have been reported for unilateral NBS treatments. Our expectation that in this patient, with dominantly subcortical lesions and relatively preserved left inferior frontal cortical regions, the TMS treatment aimed at suppressing BA<sub>H</sub> on the RH and stimulating BA would result in improved language skills and verbal memory performance and was confirmed by the outcome results.

### *Language functions*

The patient showed improvement in almost all measures of language functions tested (Table 1), but most notably in naming, semantic verbal fluency, auditory comprehension of commands, and most of all in elicited propositional speech.

Naming improvement has been one of the most consistent findings of NBS studies in chronic post-stroke non-fluent aphasia regardless of the approach adopted, inhibition of the RH (Barwood et al., 2011; Hamilton et al., 2010; Martin et al., 2009; Naeser et al., 2005, 2010), or stimulation of the lesioned LH (Baker et al., 2010; Szaflarski et al., 2011). The magnitude of our patient's naming improvement 2 months after the TMS treatment was rather modest, but similar to the magnitudes of improvement reported within the similar window of time following NBS treatment in the former studies.

Interestingly, although a high correlation between BNT scores and achievements on semantic fluency tests was found to generally exist in patients with lesions in the left inferior frontal gyrus (Stuss et al., 1998), in our patient semantic fluency improved much more than naming. At 2 months after TMS treatment it was 100% better than pre-TMS. Similar dissociation between significant improvement in semantic fluency (although of much smaller magnitude than in our patient) and negligible improvement in naming was found by Szaflarski et al. (2011) in eight chronic post-stroke aphasic patients following 10 days of unilateral iTBS over fMRI localized BA. The results may suggest that in chronic aphasia the two linguistic domains, the externally driven one (i.e. naming) and the dominantly internally driven one (i.e. fluency), differ in their susceptibility for the TMS-treatment-induced functional plasticity. Whether or not it is a more general feature of chronic non-fluent aphasia is an issue that may be investigated further.

Auditory comprehension of commands increased considerably as well. It went from only 53.3% of maximal score pre-TMS to 93.3% (almost 100% improvement) immediately post-TMS and remained at the same level 2 months after. Similar improvement, but of notably lesser magnitude, was reported for their patients by Naeser et al.

(2010) and Barwood et al. (2011), 2–3 months following RH 1-Hz repetitive TMS (rTMS).

Finally, the most prominent improvement was observed in elicited propositional speech during picture description. Following the TMS treatment, the longest phrase length during storytelling (Cookie Theft picture) improved four-fold, while the mean number of words per sentence and number of sentences increased three-fold. This finding is in line with recent reports of patients with non-fluent aphasia, following LH stroke, who experienced significant benefits in elicited propositional speech after receiving 10 sessions of inhibitory 1-Hz rTMS over the intact right BA<sub>H</sub> (Barwood et al., 2011; Hamilton et al., 2010; Martin et al., 2009). However, in all of those studies, patients improved noticeably more modestly in comparison to the patient in our study.

It is of note that in several domains, most notably in elicited propositional speech, semantic fluency, and auditory comprehension of commands, our patient improved considerably more than patients in other NBS studies, which targeted either right BA<sub>H</sub> or left BA. The difference may well be due to the differences in extent and location of the cerebral lesion, relative preservation of left inferior frontal regions, or duration of aphasia, or a combination of all of them (Lazar & Antonello, 2008). However, an alternative explanation could be that combined stimulation of LH language areas and inhibition of their right-sided homologues, achieved by bilateral physiologically potentially cumulative neuromodulatory treatment in our study, was behind the greater magnitude of the language recovery effects. Using functional imaging, Heiss, Kessler, Thiel, Ghaemi, and Karbe (1999) showed that efficient restoration of language functions was usually achieved only if left temporal areas were preserved and could be reintegrated into the functional network. Similarly, Martin et al. (2009), reported that a “good responder” patient, one whose naming and phrase length in propositional speech significantly improved, showed notable post-rTMS increase in LH peri-lesional activation on fMRI. Therefore, we may presume that in our patient, suppression of the RH BA<sub>H</sub> coupled with direct facilitation of BA managed to promote quite substantial activation of the dominant hemisphere language network important for lexical retrieval and syntactic production, as well as language comprehension.

### *Verbal memory and learning*

In addition to improvements in language functions, the beneficial effect of the TMS treatment in our patient was seen also in short-term verbal memory and verbal learning. In healthy adults, LH facilitatory anodal tDCS was shown to be able to improve verbal learning (Flöel, Rösser, Michka, Knecht, & Breitenstein, 2008). Our results suggest that NBS may have the potential to improve verbal

learning in post-stroke aphasic patients as well. At the end of the TMS treatment, two of the three indices of verbal learning improved by 100% in comparison to the baseline.

It is of note that following the TMS treatment, the tendency for producing new non-list words increased in our patient. In an attempt to retrieve existing words from the list, the patient also produced many non-list words that shared either phonological or semantic features with the list words. It is already known that word representations are interrelated within semantic memory; the associations are not formed only semantically, but also based on phonology/orthography and morphology (e.g. Frost, Deutsch, Gilboa, Tannenbaum, & Marslen-Wilson, 2000; Slowiaczek & Hamburger, 1992). Ability to use these associations seemed to be lost in our patient before the TMS treatment, but apparently has been reestablished following the treatment. Besides being of interest per se, the finding may provide a clue for explaining the other beneficial effects of the TMS treatment in our patient.

### Concluding remarks

Retrieval of language material, through pre-existing semantic and non-semantic associative links, generally tends to cause the spread of activation from cue item to other items, increasing their probability to be retrieved. In normal circumstances, this is counterbalanced by activity of various intrinsic and extrinsic inhibitory mechanisms that reduce the level of activation for inappropriate responses, preventing them from achieving a threshold to be overtly expressed. However, it can be speculated that in aphasic patients the activity of the inhibitory mechanisms within language-related cortical areas is increased, well over the limits required for normal linguistic functioning, and effectively interferes with a patient's ability to recover premorbid lexical competences. By combining reduction of RH transcallosal inhibition with direct LH facilitation, the TMS treatment seems to have induced weakening of inhibitory activity within our patient's LH BA, which allowed him to gain easier availability of lexical units within his mental lexicon. This in turn led not only to the increased number of non-list words in delayed retrieval conditions but also to improvements in language functions, particularly propositional speech and semantic fluency.

There is of course a possibility that observed improvements may have been caused by concomitant speech and language therapy. However, it has to be noted that the patient had speech and language therapy for 3 weeks before starting with TMS, but in spite of that his pre-TMS scores were quite low. In contrast, scores on several language tests increased dramatically after TMS treatment.

The presented results are from one patient only and thus cannot be easily generalized. Moreover, there was no control for possible placebo effects of the TMS

procedures. However, the data obtained suggest that in patients with LH strokes but with relatively preserved LH cortical structures, the NBS-induced suppression of the RH BAh followed by facilitation of BA has potential to promote strong functional activation of previously dormant language networks in the dominant hemisphere. This LH language areas' activation seems to be able to bring about not only improvements in lexical retrieval and syntactic production of aphasic patients but also improvements in their language comprehension and verbal learning. Further placebo-controlled studies on larger number of patients are required to confirm this hypothesis.

### Acknowledgments

The authors would like to express their gratitude to Ms Ivana Avramović, Ms Irena Avramović, Dr Aleksandra Jeremić, and Dr Aleksandra Dragin, for their help in data collection, to Ms Natalija Radivojević for her help in data interpretation, and to Dr Denis Collins for his help in finalization of the manuscript.

### Funding

This study was supported by the Ministry for Education, Science and Technological Development of Republic of Serbia [grant number 175012].

### References

- Baker, J. M., Rorden, C., & Fridriksson, J. (2010). Using transcranial direct-current stimulation to treat stroke patients with aphasia. *Stroke*, *41*, 1229–1236. doi:10.1161/STROKEAHA.109.576785
- Barwood, C. H., Murdoch, B. E., Whelan, B. M., Lloyd, D., Riek, S., O' Sullivan, J. D., ... Wong, A. (2011). Improved language performance subsequent to low-frequency rTMS in patients with chronic non-fluent aphasia post-stroke. *European Journal of Neurology*, *18*, 935–943. doi:10.1111/j.1468-1331.2010.03284.x
- Burgio, F., & Basso, A. (1997). Memory and aphasia. *Neuropsychologia*, *35*, 759–766. doi:10.1016/S0028-3932(97)00014-6
- Crosson, B., McGregor, K., Gopinath, K. S., Conway, T. W., Benjamin, M., Chang, Y. L., ... White, K. D. (2007). Functional MRI of language in aphasia: A review of the literature and the methodological challenges. *Neuropsychology Review*, *17*, 157–177. doi:10.1007/s11065-007-9024-z
- Dronkers, N. F., & Larsen, J. (2001). Neuroanatomy of the classical syndromes of aphasia. In R. S. Berndt (Ed.), *Handbook of neuropsychology: Language and aphasia* (pp. 19–30). Amsterdam: Elsevier Science B.V.
- Flöel, A., Rösler, N., Michka, O., Knecht, S., & Breitenstein, C. (2008). Noninvasive brain stimulation improves language learning. *Journal of Cognitive Neurosciences*, *20*, 1415–1422. doi:10.1162/jocn.2008.20098
- Frost, R., Deutsch, A., Gilboa, O., Tannenbaum, M., & Marslen-Wilson, W. (2000). Morphological priming: Dissociation of phonological, semantic, and morphological factors. *Memory and Cognition*, *28*, 1277–1288. doi:10.3758/BF03211828
- Goodglass, H., & Kaplan, E. (1983). *The assessment of aphasia and related disorders*. Philadelphia, PA: Lea & Febiger.

- Hamilton, R. H., Chrysikou, E. G., & Coslett, B. (2011). Mechanisms of aphasia recovery after stroke and the role of noninvasive brain stimulation. *Brain and Language*, 118, 40–50. doi:10.1016/j.bandl.2011.02.005
- Hamilton, R. H., Sanders, L., Benson, J., Faseyitan, O., Norise, C., Naeser, M., ... Coslett, H. B. (2010). Stimulating conversation: Enhancement of elicited propositional speech in a patient with chronic non-fluent aphasia following transcranial magnetic stimulation. *Brain and Language*, 113(1), 45–50. doi:10.1016/j.bandl.2010.01.001
- Heiss, W. D., Kessler, J., Thiel, A., Ghaemi, M., & Karbe, H. (1999). Differential capacity of left and right hemispheric areas for compensation of poststroke aphasia. *Annals of Neurology*, 45, 430–438. doi:10.1002/1531-8249(199904)45:4<430::AID-ANA3>3.0.CO;2-P
- Heiss, W. D., & Thiel, A. (2006). A proposed regional hierarchy in recovery of post-stroke aphasia. *Brain and Language*, 98, 118–123. doi:10.1016/j.bandl.2006.02.002
- Huang, Y. Z., Edwards, M. J., Rounis, E., Bhatia, K. P., & Rothwell, J. C. (2005). Theta burst stimulation of the human motor cortex. *Neuron*, 45, 201–206. doi:10.1016/j.neuron.2004.12.033
- Kaplan, E., Goodglass, H., & Weintraub, S. (1983). *Boston naming test*. Philadelphia, PA: Lea & Febiger.
- Kelly, H., Brady, M. C., & Enderby, P. (2010). Speech and language therapy for aphasia following stroke. *Cochrane Database Systematic Reviews*, 5, CD000425. doi:10.1002/14651858.CD000425.pub2
- Klem, G. H., Luders, H. O., Jasper, H. H., & Elger, C. (1999). The ten-twenty electrode system of the international federation. The international federation of clinical neurophysiology. *Electroencephalography and Clinical Neurophysiology, Supplement*, 52, 3–6.
- Koessler, L., Maillard, L., Benhadid, A., Vignal, J. P., Felblinger, J., Vespignani, H., ... Braun, M. (2009). Automated cortical projection of EEG sensors: Anatomical correlation via the international 10–10 system. *NeuroImage*, 46, 64–72. doi:10.1016/j.neuroimage.2009.02.006
- Laska, A. C., Hellblom, A., Murray, V., Kahan, T., & Von, M. (2001). Aphasia in acute stroke and relation to outcome. *Journal of Internal Medicine*, 249, 413–422. doi:10.1046/j.1365-2796.2001.00812.x
- Lazar, R. M., & Antonietto, D. (2008). Variability in recovery from aphasia. *Current Neurology and Neuroscience Reports*, 8, 497–502. doi:10.1007/s11910-008-0079-x
- Lezak, M. D., Howieson, D. B., & Loring, D. W. (2004). *Neuropsychological assessment* (4th ed.). New York, NY: Oxford University Press.
- Martin, P. I., Naeser, M. A., Ho, M., Doron, K. W., Kurland, J., Kaplan, J., ... Pascual-Leone, A. (2009). Overt naming fMRI pre- and post-TMS: Two nonfluent aphasia patients, with and without improved naming post-TMS. *Brain and Language*, 111, 20–35. doi:10.1016/j.bandl.2009.07.007
- Miniussi, C., Cappa, S. F., Cohen, L. G., Floel, A., Fregni, F., Nitsche, M. A., ... Walsh, V. (2008). Efficacy of repetitive transcranial magnetic stimulation/transcranial direct current stimulation in cognitive neurorehabilitation. *Brain Stimulation*, 1, 326–336. doi:10.1016/j.brs.2008.07.002
- Mylius, V., Zouari, H. G., Ayache, S. S., Farhat, W. H., & Lefaucheur, J.-P. (2012). Stroke rehabilitation using noninvasive cortical stimulation: Aphasia. *Expert Review of Neurotherapeutics*, 12(8), 973–982. doi:10.1586/ern.12.76
- Naeser, M. A., Martin, P. I., Lundgren, K., Klein, R., Kaplan, J., Treglia, E., ... Pascual-Leone, A. (2010). Improved language in a chronic nonfluent aphasia patient after treatment with CPAP and TMS. *Cognitive and Behavioral Neurology*, 23, 29–38. doi:10.1097/WNN.0b013e3181bf2d20
- Naeser, M. A., Martin, P. I., Nicholas, M., Baker, E. H., Seekins, H., Kobayashi, M., ... Kurland, J. (2005). Improved picture naming in chronic aphasia after TMS to part of right Broca's area: An open-protocol study. *Brain and Language*, 93, 95–105. doi:10.1016/j.bandl.2004.08.004
- Naeser, M. A., Martin, P. I., Theoret, H., Kobayashi, M., Fregni, F., Nicholas, M., ... Pascual-Leone, A. (2011). TMS suppression of right pars triangularis, but not pars opercularis, improves naming in aphasia. *Brain and Language*, 119, 206–213. doi:10.1016/j.bandl.2011.07.005
- Okamoto, M., Dan, H., Sakamoto, K., Takeo, K., Shimizu, K., Kohno, S., ... Dan, I. (2004). Three-dimensional probabilistic anatomical cranio-cerebral correlation via the international 10–20 system oriented for transcranial functional brain mapping. *NeuroImage*, 21, 99–111. doi:10.1016/j.neuroimage.2003.08.026
- Rothwell, J. C., Hallett, M., Berardelli, A., Eisen, A., Rossini, P., & Paulus, W. (1999). Magnetic stimulation: Motor evoked potentials. The international federation of clinical neurophysiology. *Electroencephalography and Clinical Neurophysiology, Supplement*, 52, 97–103.
- Saur, D., & Hartwigsen, G. (2012). Neurobiology of language recovery after stroke: Lessons from neuroimaging studies. *Archives of Physical Medicine and Rehabilitation*, 93 (1 Suppl), S15–S25. doi:10.1016/j.apmr.2011.03.036
- Schlaug, G., Marchina, S., & Wan, C. Y. (2011). The use of non-invasive brain stimulation techniques to facilitate recovery from post-stroke aphasia. *Neuropsychology Review*, 21, 288–301. doi:10.1007/s11065-011-9181-y
- Schouten, E. A., Schiemanck, S. K., Brand, N., & Post, M. W. (2009). Long-term deficits in episodic memory after ischemic stroke: Evaluation and prediction of verbal and visual memory performance based on lesion characteristics. *Journal of Stroke and Cerebrovascular Diseases*, 18, 128–138. doi:10.1016/j.jstrokecerebrovasdis.2008.09.017
- Slowiaczek, L. M., & Hamburger, M. (1992). Prelexical facilitation and lexical interference in auditory word recognition. *Journal of Experimental Psychology: Learning Memory and Cognition*, 18, 1239–1250.
- Stuss, D. T., Alexander, M. P., Hamer, L., Palumbo, C., Dempster, R., Binns, M., ... Izukawa, D. (1998). The effects of focal anterior and posterior brain lesions on verbal fluency. *Journal of the International Neuropsychological Society*, 4, 265–278.
- Szaflarski, J. P., Vannest, J., Wu, S. W., DiFrancesco, M. W., Banks, C., & Gilbert, D. L. (2011). Excitatory repetitive transcranial magnetic stimulation induces improvements in chronic post-stroke aphasia. *Medical Science Monitor*, 17(3), CR132–CR139.
- Thompson, C. K. (2000). Neuroplasticity: Evidence from aphasia. *Journal of Communication Disorders*, 33, 357–366. doi:10.1016/S0021-9924(00)00031-9
- Tombaugh, T. N., & Hubiey, A. M. (1997). The 60-item Boston naming test: Norms for cognitively intact adults aged 25 to 88 years. *Journal of Clinical and Experimental Neuropsychology*, 19, 922–932. doi:10.1080/01688639708403773