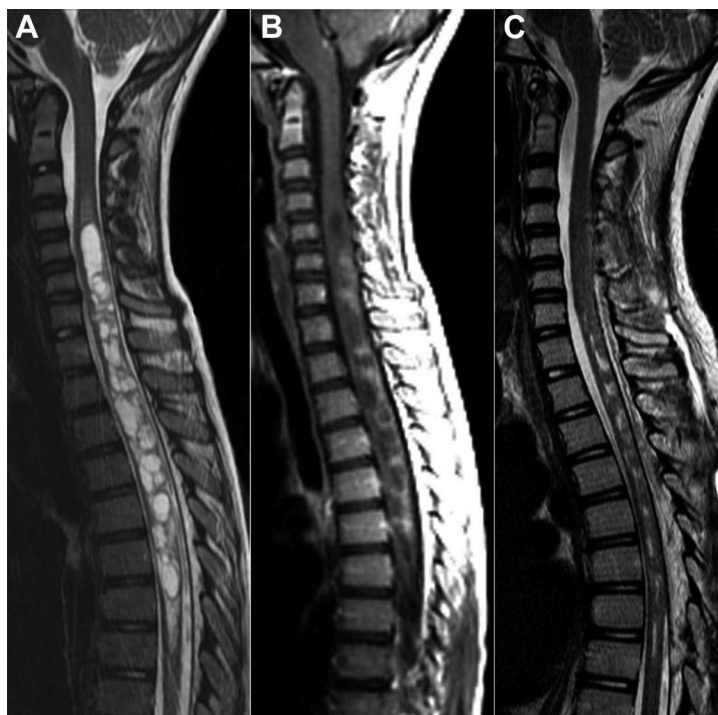

Multicystic demyelinating myelopathy

Widening spectrum of pediatric aquaporin-4 autoimmunity

Figure 1 Baseline and repeat spinal cord MRI after immunotherapy



Sagittal T2-weighted MRI demonstrates a large multiloculated cystic lesion within the spinal cord extending from C4 to T7 (A), with patchy peripheral nodular enhancement on postcontrast scan (B). (C) Decreased axial extension of the lesion and improvement in spinal cord edema and expansion 4 weeks after steroid therapy.

A 10-year-old girl presented with subacute lower limb weakness and gait ataxia. MRI revealed a large multicystic spinal cord lesion with patchy enhancement (figure 1, A and B) and 3 small (<6 mm) periventricular and deep white matter brain lesions. The presence of serum anti-aquaporin-4 (AQP4) immunoglobulin G (ELISA assay) and compatible neuropathologic features from neurosurgical specimens¹ (figure 2) suggested the diagnosis of a neuromyelitis optica spectrum disorder.² Targeted immunotherapy was started, with partial lesion resolution (figure 1C).

This case provides neuroradiologic evidence for macroscopic multicystic cord demyelination in AQP4-related disorders and highlights the role of inflammatory etiologies in childhood spinal cord disease.

Giulia Longoni, MD, Sandra Bigi, MD, Helen M. Branson, MD, Cynthia Hawkins, MD, James T. Rutka, MD, PhD, Massimo Filippi, MD, E. Ann Yeh, MD

From the Neuroimaging Research Unit (G.L., M.F.), Institute of Experimental Neurology; San Raffaele Scientific Institute (G.L., M.F.); Vita-Salute University, Milan, Italy; University of Toronto (G.L., S.B., H.M.B., C.H., J.T.R., E.A.Y.); and The Hospital for Sick Children (G.L., S.B., H.M.B., C.H., J.T.R., E.A.Y.), Toronto, Canada.

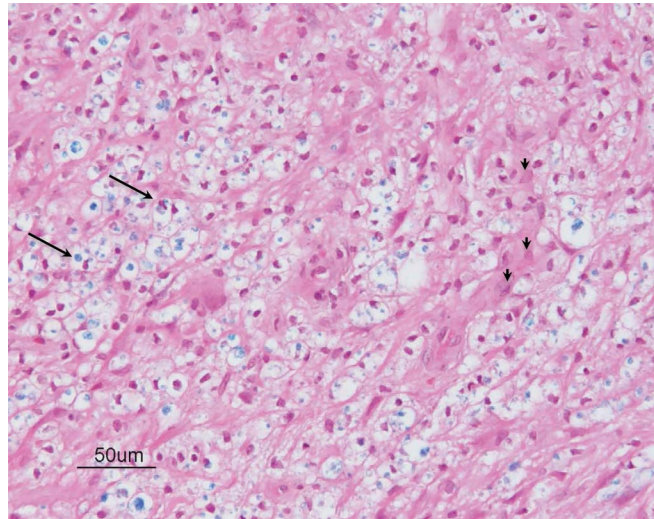
Author contributions: Dr. Longoni drafted/revised the manuscript. Dr. Bigi, Dr. Branson, Dr. Hawkins, and Dr. Rutka contributed to the interpretation of medical data. Prof. Filippi and Dr. Yeh revised the manuscript and performed medical writing for content. All authors reviewed and approved the final manuscript.

Study funding: No targeted funding reported.

Disclosure: The authors report no disclosures relevant to the manuscript. Go to Neurology.org for full disclosures.

Correspondence to Dr. Yeh: ann.yeh@sickkids.ca

Figure 2 Spinal cord biopsy



Hematoxylin & eosin/Luxol fast blue (LFB) stained section from the spinal cord biopsy demonstrates sheets of macrophages (arrows) containing LFB-positive debris and scattered reactive astrocytes (arrowheads) suggestive of an active demyelinating process (200 \times).

1. Lucchinetti CF, Mandler RN, McGavern D, et al. A role for humoral mechanisms in the pathogenesis of Devic's neuromyelitis optica. *Brain* 2002;125:1450–1461.
2. McKeon A, Lennon VA, Lotze T, et al. CNS aquaporin-4 autoimmunity in children. *Neurology* 2008;71:93–100.

NeuroImages Are Free at www.neurology.org!

All *Neurology*[®] NeuroImages can now be freely accessed on the *Neurology* Web site. See them at www.neurology.org, where you can also sign up for journal email alerts and check out other online features, including the Resident & Fellow section, *Neurology: Clinical Practice*, and the weekly *Neurology* Podcasts.