

Recurrent Extracranial Internal Carotid Artery Vasospasm Diagnosed by Serial Magnetic Resonance Angiography and Superselective Transarterial Injection of a Calcium Channel Blocker

Yoshiteru Shimoda, MD,*† Miki Fujimura, MD, PhD,*† Naoto Kimura, MD, PhD,†
Masayuki Ezura, MD, PhD,† Hiroshi Uenohara, MD, PhD,†
and Teiji Tominaga, MD, PhD*

Recurrent vasospasm of the extracranial internal carotid artery (ICA) is extremely rare, and optimal management is unclear. A 25-year-old woman developed transient dysarthria and left-sided hemiparesis. Initial magnetic resonance (MR) imaging showed spotty acute infarction in the right temporal lobe, and MR angiography revealed right ICA occlusion. ICA occlusion was spontaneously resolved within 6 days of its onset, whereas transient left ICA narrowing was evident at 12 days. Because recurrent occlusion of the right ICA occurred at 14 days when the contralateral ICA was still narrowed, we attempted a local intra-arterial injection of a calcium channel blocker based on the diagnosis of recurrent extracranial ICA vasospasm. The local injection of 1 mg of nicardipine partially dilated the affected ICA, which confirmed the diagnosis of vasospasm. After the introduction of oral medication with benidipine hydrochloride, bilateral ICA vasospasm was completely resolved 23 days after its onset, as shown by MR angiography. In conclusion, we recommend intensive radiologic follow-up at the acute stage and therapeutic catheter angiography when the bilateral lesion is evident because bilateral occlusion of the ICA could lead to a catastrophic condition. **Key Words:** Recurrent extracranial internal carotid artery vasospasm—magnetic resonance angiography—interventional neuroradiology—calcium channel blocker.

© 2014 by National Stroke Association

From the *Department of Neurosurgery, Tohoku University Graduate School of Medicine, Sendai; and †Department of Neurosurgery, National Hospital Organization Sendai Medical Center, Sendai, Japan.

Received November 13, 2013; revision received December 14, 2013; accepted December 31, 2013.

Address correspondence to Miki Fujimura, MD, PhD, Department of Neurosurgery, Tohoku University Graduate School of Medicine, 1-1 Seiryomachi, Aoba-ku, Sendai 980-8574, Japan. E-mail: mfujimur@gmail.com.

1052-3057/\$ - see front matter

© 2014 by National Stroke Association

<http://dx.doi.org/10.1016/j.jstrokecerebrovasdis.2013.12.050>

Introduction

Vasospasm of the extracranial internal carotid artery (ICA) has generally been attributed to mechanical stress such as catheter examination and trauma, whereas idiopathic recurrent vasospasm of the extracranial ICA is extremely rare, with only 8 cases being reported to date.¹⁻⁷ Here, we report a case of bilateral recurrent extracranial ICA vasospasm that underwent serial magnetic resonance (MR) angiography and the interventional transarterial injection of a calcium channel blocker to the affected vessel.

Case Report

A 25-year-old woman developed transient dysarthria and left-sided hemiparesis. Diffusion-weighted MR imaging revealed a spotty high intensity area in the right frontal operculum (Fig 1, A), and MR angiography demonstrated right ICA occlusion (Fig 2, A). She was subsequently transferred to our hospital with the initial diagnosis of right ICA dissection. Although her neurologic status was unremarkable on admission, she had a headache. She did not have any risk factors for cardiovascular disease, except for migraine-like headaches. She had a habit of active dancing but had no history of trauma to the head or neck.

Laboratory data, x-rays of the chest, and screening for thrombophilia and vasculitis found no apparent abnormalities. *N*-isopropyl-*p*-[¹²³I]iodoamphetamine single-photon emission computed tomography (CT) demonstrated no hemodynamic compromise (data not shown); therefore, she was treated conservatively with the initial diagnosis of idiopathic ICA dissection. Occlusion of the right ICA was relieved 6 days after its onset, as shown by MR angiography (Fig 2, B). Repeated MR angiography 12 days after the onset demonstrated no steno-occlusive changes in the right ICA, but segmental narrowing at the contralateral extracranial ICA at the left C1-2 junction (Fig 2, C, arrow). Three-dimensional CT angiography revealed occlusion of the right ICA again 2 days later when the contralateral ICA was still narrowed (Fig 2, D). In light of the dynamic courses of bilateral extracranial ICA stenosis, we suspected recurrent extracranial ICA vasospasm, and attempted therapeutic catheter angiography 14 days after the onset. Bilateral carotid angiography revealed that the left ICA narrowing was almost relieved and cross flow from the left ICA supplied the vascular territory of the right ICA (Fig 2, G). Because the right ICA was still occluded at the cervical portion (Fig 2, H), we attempted interventional therapy to the affected vessel. Although a local intra-arterial injection of 15 mg of fasudil hydrochloride (15 mg) was not

effective, an intra-arterial injection of 1 mg of nicardipine partially dilated the vasoconstricted right ICA, suggesting the efficacy of the calcium channel blocker to this intrinsic pathology (Fig 2, I, arrow). We then administered oral medication of benidipine hydrochloride (4 mg/day) in addition to low-dose aspirin (100 mg/day). Right ICA vasospasm was ameliorated 2 days later (Fig 2, E), and the patient completely recovered at 23 days (Fig 2, F). She did not exhibit neurologic deterioration during the follow-up period.

Discussion

We demonstrated the temporal profile of recurrent extracranial ICA vasospasm with bilateral lesion by neuroimaging, such as MR angiography, and revealed a dynamic course during a short period. Recurrent extracranial ICA vasospasm is characterized by reversible steno-occlusive changes in the ICA 2-4 cm distal to the common carotid artery bifurcation, and has been reported in 9 cases including the present case (Table 1). All 9 cases were relatively younger adults (24-48 years),¹⁻⁷ and repeatedly exhibited temporary segmental vasospasm during a short period ranging from 3 days to 42 months. Eight of the 9 cases had bilateral ICA vasospasm including our case.¹⁻⁷ None of the 9 cases showed involvement of the external carotid artery. Our case also showed dynamic changes in the bilateral extracranial ICA during the 20 days from admission, although the site of vasospasm of the left ICA appeared to be more distal than that of the typical location. Eight of the 9 cases developed cerebral infarction.¹⁻⁷ Our patient also developed spotty cerebral infarction in the right frontal operculum. Although we failed to detect apparent hemodynamic compromise in the initial flow study in our case, development of cerebral infarction could be because of the hemodynamic ischemia at the acute stage after vasospastic occlusion of the extracranial ICA, in light of the absence of any atherosclerotic background in

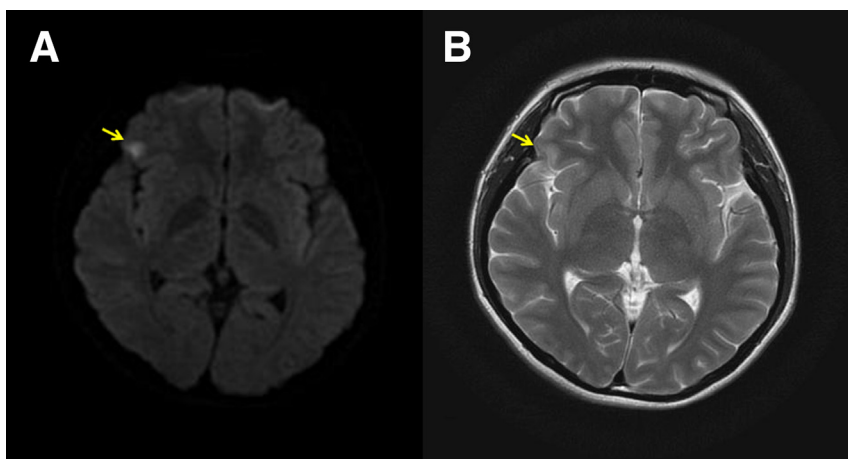


Figure 1. Diffusion-weighted imaging (A) and T2-weighted imaging (B) of initial magnetic resonance study demonstrating spotty acute infarction in the right frontal operculum (arrows).

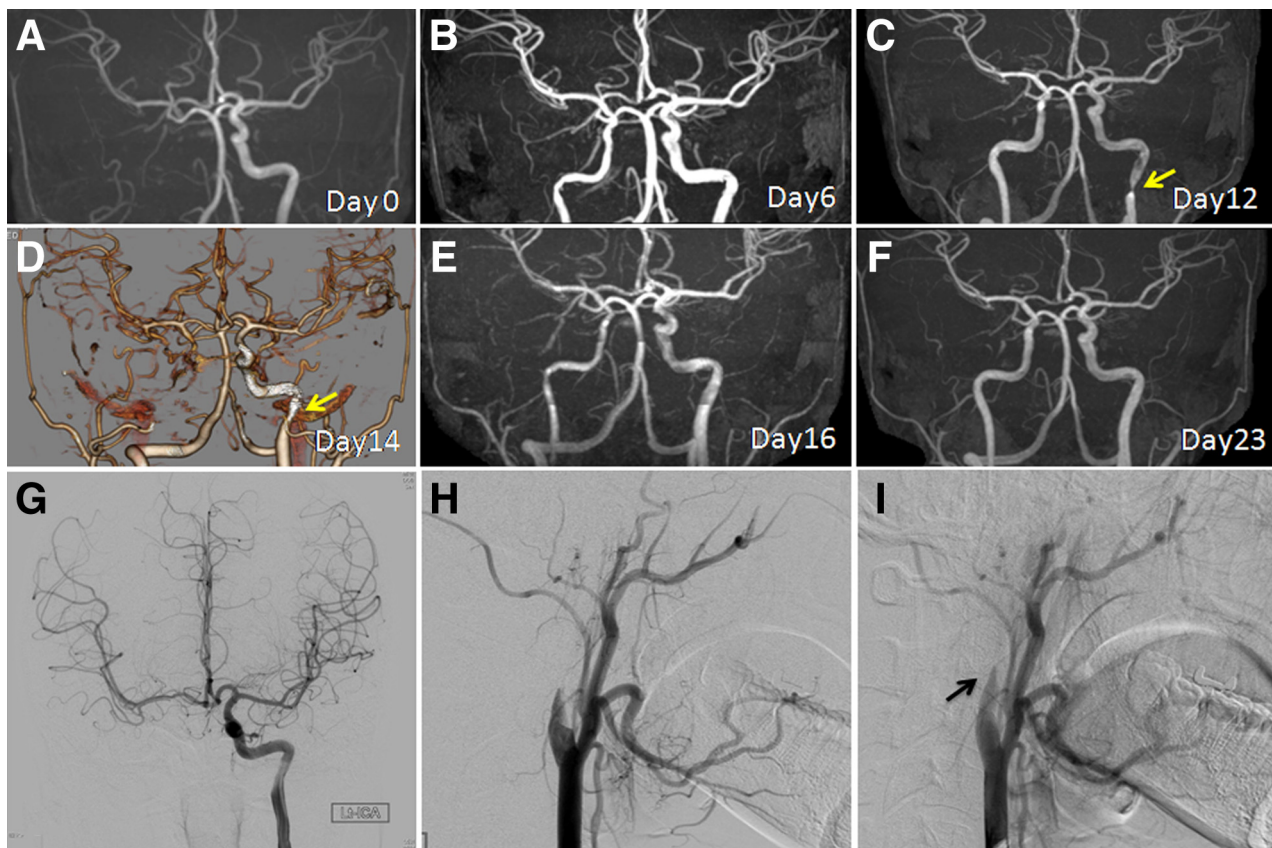


Figure 2. (A-F) Temporal profile of MR angiography (A-C, E, and F) and 3-dimensional computed tomography angiography 14 days after the onset (D). MR angiography at the onset (A), 6 days (B), 12 days (C), 16 days (E), and 23 days (F) after the onset. Temporal profile of reversible bilateral ICA vasospasm before (A-D) and after (E and F) the interventional local intra-arterial injection of a calcium channel blocker. The site of left ICA vasospasm is indicated by arrows in (C) and (D). (G-I) Anteroposterior view of the left ICA injection before treatment, demonstrating collateral cross flow to the right ICA territory. Lateral view of the right common carotid artery injection before (H) and after (I) the interventional local intra-arterial injection of a calcium channel blocker. Abbreviations: ICA, internal carotid artery; MR, magnetic resonance.

this young patient. Characteristics of the 9 reported cases are summarized in [Table 1](#).

The underlying mechanism of this rare condition has yet to be determined. In light of the finding that sympathetic neurons controlling vasoconstriction around this area of the ICA are innervated bilaterally and are not distributed to the external carotid artery, hypersensitivity of the sympathetic neurons may contribute to bilateral reversible vasospasm at this particular site.⁷ The association of recurrent extracranial ICA vasospasm with coronary arteries and/or with migraine may further support the common pathogenesis of sympathetic dysfunction. Our case did not have coronary artery disease, but she did have a history of migraine-like headaches and a habit of active dancing. Taken together with the previous studies suggesting that a mechanical stimulus from the surrounding soft tissue could be a trigger for the hypersensitivity leading to vasospasm,⁸⁻¹⁰ it is conceivable that these backgrounds together contributed in part to hypersensitivity of the sympathetic neurons and ultimately led to ICA vasospasm.

An optimal management protocol for recurrent extracranial ICA vasospasm has not yet been established. Although most of the reported cases were managed by oral medication of a calcium channel blocker,²⁻⁷ the exact efficacy remains unclear. We attempted, for the first time, therapeutic catheter angiography at the acute stage. The effect of intra-arterial injection of nicardipine on the ICA occlusion was only partial in our case, but it provided important information leading to the definitive diagnosis of this rare condition. The local intra-arterial injection of a calcium channel blocker verified the potential reactivity of the affected vessel in this case, indicating the potential efficacy of the calcium channel blocker to resolve this pathogenesis. In fact, we started oral medication of benidipine hydrochloride based on this finding, which led to a complete resolution of the vasospasm. Further studies with a larger number of patients are necessary to answer this important question whether intra-arterial injection of nicardipine on the affected ICA has a potential role for relieving extracranial ICA vasospasm.

Table 1. Summary of the cases with recurrent extracranial ICA vasospasm

| Reference | Age/sex | Clinical symptom | Affected side (extracranial ICA) | Diagnosis | Infraction | Radiologic findings | Past history | Additional therapy besides oral medication of a calcium blocker |
|----------------------------------|---------|--|----------------------------------|-----------------------|------------|------------------------|-----------------------------|---|
| Arning et al ¹ | 32/F | Visual disturbance, headache, hemiparesis | Left | MRA, US | + | Stenosis | — | Anticoagulation, prednisone |
| Yokoyama et al ⁴ | 35/M | Visual blurring, eye pain, headache, hemiparesis | Bilateral | MRA, US SPECT | + | Occlusion and stenosis | Myocardial infraction | Stellate ganglion block |
| Janzarik et al ² | 30/M | Visual disturbance hemiparesis | Bilateral | MRA, DSA, US | + | Occlusion and stenosis | — | Anticoagulation, papaverine ia |
| Janzarik et al ² | 48/F | Lack of motivation | Bilateral | MRA, US | + | Stenosis | Migraine | Anticoagulation, magnesium methylprednisolone |
| Mosso et al ³ | 45/M | Monocular blindness | Bilateral | MRA, US | — | Occlusion and stenosis | Migraine | Anticoagulation, isosorbide dinitrate, nitroglycerin |
| Yoshimoto et al ⁵ | 39/F | Amaurosis hemiparesis | Left | MRA, DSA, 3DCTA | + | Stenosis | Vasospastic angina, Smoking | Anticoagulation, aspirin, cilostazol, α -1-blocker |
| Dembo and Tanahashi ⁶ | 24/F | Headache, visual impairment | Right | DSA, IVUS Xe-CT | + | Stenosis | Smoking | Isosorbide ia, PTA, fasudil hydrochloride, ozagrel sodium |
| Moeller et al ⁷ | 25/M | Amaurosis, hemiparesis | Bilateral | MRA, US | + | Stenosis | — | Anticoagulation, α -1-blocker (without calcium blocker) |
| Present case | 25/F | Hemiparesis, dysarthria | Bilateral | MRA, DSA 3DCTA, SPECT | + | Occlusion and stenosis | Migraine-like headache | Nicardipine ia, fasudil hydrochloride ia, anticoagulation |

Abbreviations: 3DCTA, 3-dimensional computed tomography angiography; DSA, digital subtraction angiography; F, female; ia, intra-arterial injection; ICA, internal carotid artery; IVUS, intravascular ultrasonography; M, male; MRA, magnetic resonance angiography; PTA, percutaneous transluminal angioplasty; SPECT, single-photon emission computed tomography; US, ultrasonography; Xe-CT, xenon computed tomography.

References

1. Arning C, Schrattenholzer A, Lachenmayer L. Cervical carotid artery vasospasms causing cerebral ischemia: detection by immediate vascular ultrasonographic investigation. *Stroke* 1998;29:1063-1066.
2. Janzarik WG, Ringleb PA, Reinhard M, et al. Recurrent extracranial carotid artery vasospasms: report of 2 cases. *Stroke* 2006;37:2170-2173.
3. Mosso M, Jung HH, Baumgartner RW. Recurrent spontaneous vasospasm of cervical carotid, ophthalmic and retinal arteries causing repeated retinal infarcts: a case report. *Cerebrovasc Dis* 2007;24:381-384.
4. Yokoyama H, Yoneda M, Abe M, et al. Internal carotid artery vasospasm syndrome: demonstration by neuroimaging. *J Neurol Neurosurg Psychiatry* 2006;77:888-889.
5. Yoshimoto H, Matsuo S, Umemoto T, et al. Idiopathic carotid and coronary vasospasm: a new syndrome? *J Neuroimaging* 2011;21:273-276.
6. Dembo T, Tanahashi N. Recurring extracranial internal carotid artery vasospasm detected by intravascular ultrasound. *Intern Med* 2012;51:1249-1253.
7. Moeller S, Hilz MJ, Blinzler C, et al. Extracranial internal carotid artery vasospasm due to sympathetic dysfunction. *Neurology* 2012;78:1892-1894.
8. Gurdjian ES, Audet B, Sibayan RW, et al. Spasm of the extracranial internal carotid artery resulting from blunt trauma demonstrated by angiography. *J Neurosurg* 1971;35:742-747.
9. Verillaud B, Ducros A, Massiou H, et al. Reversible cerebral vasoconstriction syndrome in two patients with carotid glomus tumour. *Cephalalgia* 2010;30:1271-1275.
10. Bland JF, Perry MO, Clark K. Spasm of the cervical internal carotid artery. *Ann Surg* 1967;166:987-989.