

CASE REPORT

High-altitude cerebral oedema mimicking stroke

Uday Yanamandra,¹ Amul Gupta,² Sagarika Patyal,³ Prem Prakash Varma⁴¹Department of Internal Medicine, 153 General Hospital, Leh, Jammu & Kashmir, India²Department of Radiology, 153 General Hospital, Leh, Jammu & Kashmir, India³Department of Ophthalmology, 153 General Hospital, Leh, Jammu & Kashmir, India⁴Department of Medicine, Northern Command Medical, Leh, Jammu & Kashmir, India

Correspondence to

Dr U Yanamandra,
udayj2@gmail.com,
udayj2@yahoo.com

Accepted 21 February 2014

SUMMARY

High-altitude cerebral oedema (HACO) is the most fatal high-altitude illness seen by rural physicians practising in high-altitude areas. HACO presents clinically with cerebellar ataxia, features of raised intracranial pressure (ICP) and coma. Early identification is important as delay in diagnosis can be fatal. We present two cases of HACO presenting with focal deficits mimicking stroke. The first patient presented with left-sided hemiplegia associated with the rapid deterioration in the sensorium. Neuroimaging revealed features suggestive of vasogenic oedema. The second patient presented with monoplegia of the lower limb. Neuroimaging revealed perfusion deficit in anterior cerebral artery territory. Both patients were managed with dexamethasone and they improved dramatically. Clinical picture and neuroimaging closely resembled acute ischaemic stroke in both cases. Thrombolysis in these patients would have been disastrous. Recent travel to high altitude, young age, absence of atherosclerotic risk factors and features of raised ICP concomitantly directed the diagnosis to HACO.

BACKGROUND

High altitude is associated with a variety of physiological changes in the body primarily due to hypoxia and associated changes in barometric pressure and temperature. Lack of acclimatisation can lead to a variety of medical problems, especially acute mountain sickness (AMS), high-altitude cerebral oedema (HACO) and high-altitude pulmonary oedema (HAPO).

HACO is the most fatal high-altitude illness seen by rural physicians practising in high-altitude areas. HACO, primarily a clinical entity, occurs in a patient of AMS or HAPO and is characterised by sudden-onset ataxia, altered consciousness or both. Early identification is important as delay in diagnosis can be fatal. Focal neurological deficit is not a usual feature of HACO. We report two cases of HACO who presented with deficits mimicking stroke which resolved by the resolution of cerebral oedema.

CASE PRESENTATION

Case 1

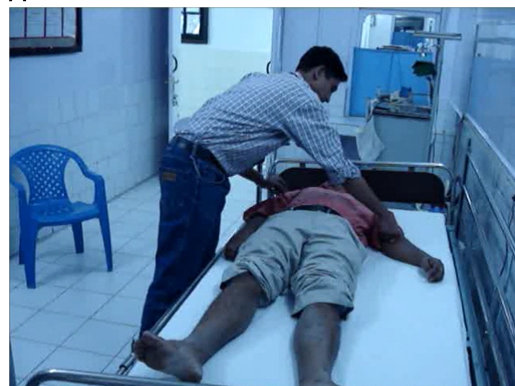A 23-year-old man was inducted to high altitude (11 800 ft) on 12 September 2012. On the third day of his acclimatisation (14 September 2012), he was observed to have an unsteady gait by his colleagues. Within the next few hours, he was found to be drowsy and not responding to verbal commands and hence brought to our hospital. Examination on arrival to our hospital: pulse was 84/min, blood pressure 132/82 mm Hg, and SpO₂ was 62% in

ambient air. Neurologically he was found to be disoriented, non-coherent and had left-sided hemiplegia (video 1A). Respiratory evaluation revealed a respiratory rate of 32/min and chest examination revealed bilateral basal crepitations (right>left). Other systemic examination was normal. Fundus examination revealed papilloedema.

Investigations

His haematological parameters and biochemical parameters were within normal limits (haemoglobin

A



B



Video 1 (A) The patient described in case 1 on arrival to our hospital. Observe that the individual is unable to move the left half of his body even on painful stimulus. (B) The patient described in case 1 at the time of discharge.



CrossMark

To cite: Yanamandra U, Gupta A, Patyal S, et al. *BMJ Case Rep* Published online: [please include Day Month Year] doi:10.1136/bcr-2013-201897

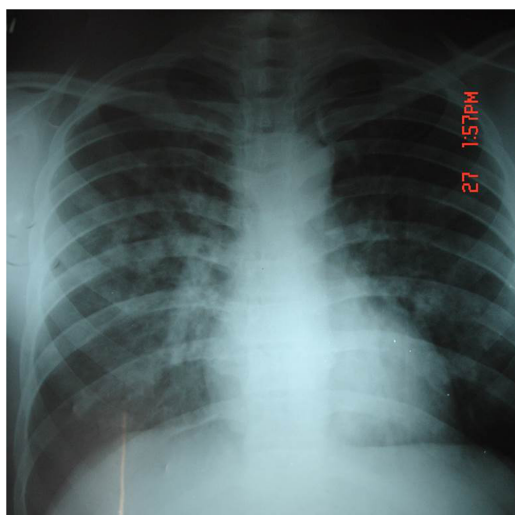


Figure 1 Chest radiograph on the day of admission (case 1) depicting fluffy air space opacities in the right mid and lower zone consistent with high-altitude pulmonary oedema.

13.2 g/dL, total leucocyte count 10 500/ μ L, differential leucocytes polymorphs 68%, lymphocytes 24%, blood sugar fasting/postprandial 84/112 mg/dL, urea/creatinine 28/1.0 mg/dL, total cholesterol 182 mg/dL). Chest radiograph revealed fluffy air-space opacities in right mid and lower zones consistent with high-altitude pulmonary oedema (HAPO; [figure 1](#)). Optic nerve sheath diameter (ONSD) was 11 mm. Non-contrast CT scan (NCCT) of the brain showed diffuse cerebral oedema involving white matter of bilateral cerebral hemispheres, mass effect in the form of the effacement of the overlying sulci and compression of the lateral ventricles and third ventricle. The corpus callosum was also hypodense due to oedema. Accentuation of grey–white matter differentiation was suggestive of vasogenic oedema ([figure 2](#)).

Differential diagnosis

A clinical possibility of stroke/central venous thrombosis (CVT) was considered due to focal neurological deficit.

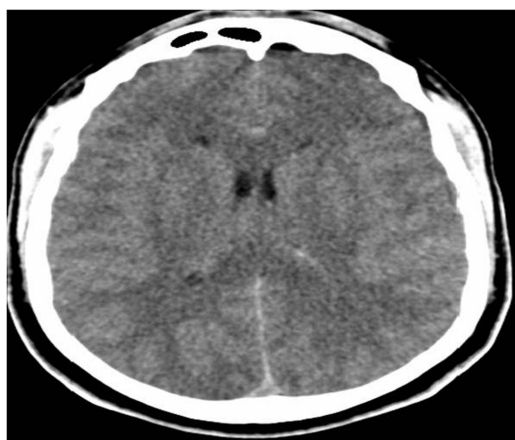

Figure 2 Non-contrast CT of the head on the day of admission (case 1) reveals diffuse cerebral oedema with mass effect effacing the sulci and compressing bilateral lateral ventricles. Grey–white matter differentiation is also accentuated.

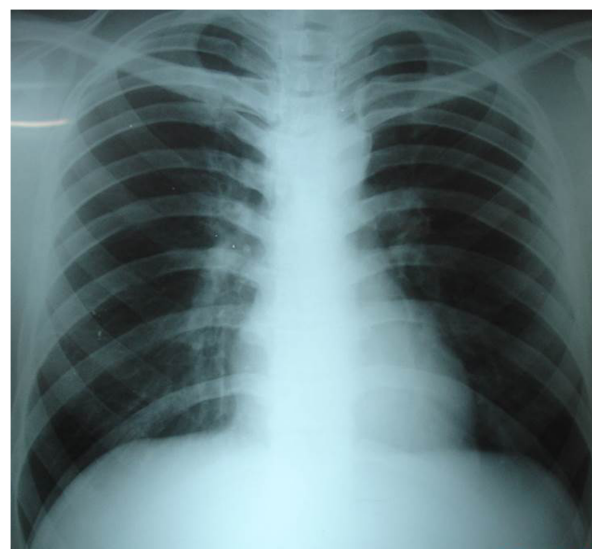


Figure 3 Chest radiograph on day 3 of admission (case 1) showing resolution of air space opacities seen on D1 roentgenogram.

Treatment

The patient was managed with oxygen by venturi-mask at 6 L/min and parenteral dexamethasone 8 mg q8 h.

Outcome and follow-up

His cognitive functions started improving within 4 h and hemiplegia within 12 h. However, ataxia improved slowly, and by the third day of hospitalisation, his chest was clear and his gait was normal ([video 1B](#)). Repeat chest radiograph on the third day of admission showed complete resolution of the opacities ([figure 3](#)). Repeat NCCT performed on the fourth day showed that the white matter oedema had subsided with decreased mass effect and the grey–white matter differentiation was seen to be normal ([figure 4](#)). He was discharged on the tenth day, and at that time, his ONSD was 4.5 mm and papilledema had subsided.

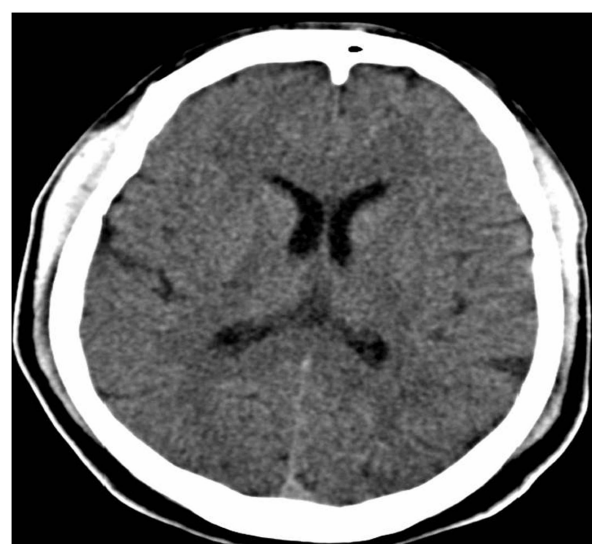

Figure 4 Repeat non-contrast CT on day 4 of admission (case 1) showing resolution of cerebral oedema and mass effect. Grey–white matter differentiation has normalised.

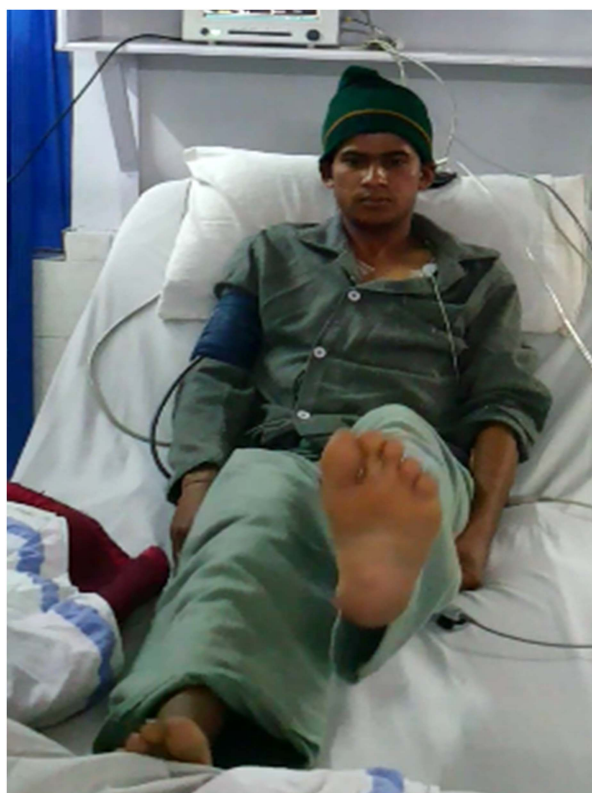

Figure 5 The patient described in case 2 depicting difficulty in lifting the right lower limb due to monoplegia.

CASE PRESENTATION

Case 2

A 21-year-old man was inducted into high altitude (18 000 ft) on 7 May 2013. On the fifth day of his arrival to this altitude (12 May 2013), he presented with sudden onset of weakness of the right lower limb on waking up from sleep ([figure 5](#)). Examination revealed SpO₂ of 52% (on ambient air); neurologically, he had monoplegia of right lower limb while the rest of the neurological examination was found to be normal. Chest examination revealed a respiratory rate of 36/min and bilateral crepitations up to the middle of the chest. Other systems were normal.

Investigations

His haematological parameters and biochemical parameters were within normal limits. Chest radiograph revealed fluffy air space opacities in bilateral mid and lower zones, consistent with HAPO ([figure 6](#)). ONSD was 12 mm. NCCT scan did not reveal any evidence of acute/ sub-acute/old infarction or haemorrhage, but had features of vasogenic oedema with mass effect, as seen in case 1. CT perfusion scan of the brain showed perfusion deficit in the anterior cerebral artery (ACA) territory bilaterally ([figure 7](#)).

Differential diagnosis

A clinical possibility of stroke or CVT was considered.

Treatment

The patient was managed with oxygen by venturi mask at 6 L/min and parenteral dexamethasone 8 mg q8 h.

Outcome and follow-up

Within 12 h of initiation of the treatment, monoplegia started improving. Repeat chest radiograph on the third day of

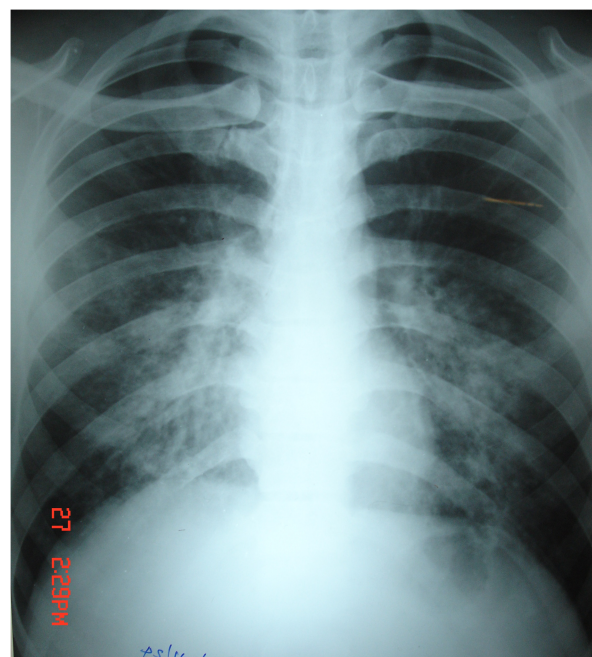


Figure 6 Chest radiograph on the day of admission (case 2) depicting fluffy air space opacities in the right mid and lower zone consistent with high-altitude pulmonary oedema.

admission showed complete resolution of the opacities ([figure 8](#)). Repeat CT perfusion performed on the seventh day showed that the perfusion defects had reversed, white matter oedema had subsided with decreased mass effect, and the grey–white matter differentiation was normal ([figure 9](#)). Power in the right lower limb became normal (5/5 power, both lower limbs; [figure 10](#)). He was discharged on the fourteenth day, his ONSD was 4.2 mm at the time of discharge.

DISCUSSION

The incidence of HACO in HAPO varies from 14 to 50%. It can occasionally present in the absence of AMS, when it is

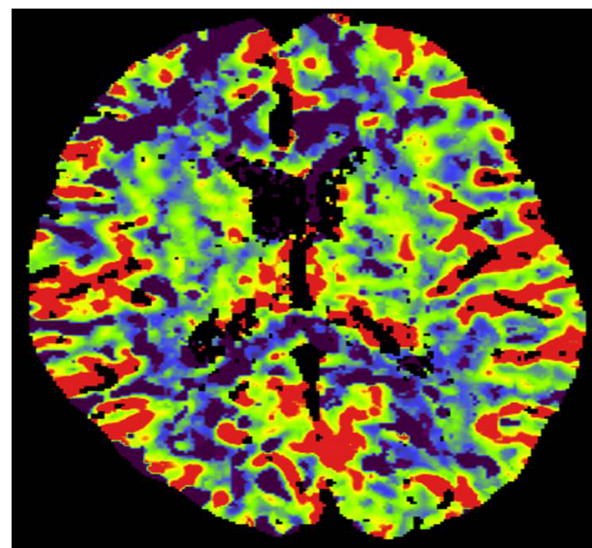


Figure 7 CT perfusion imaging on day 1 of the hospitalisation (case 2) revealing reversible perfusion defects in the anterior cerebral artery territory.

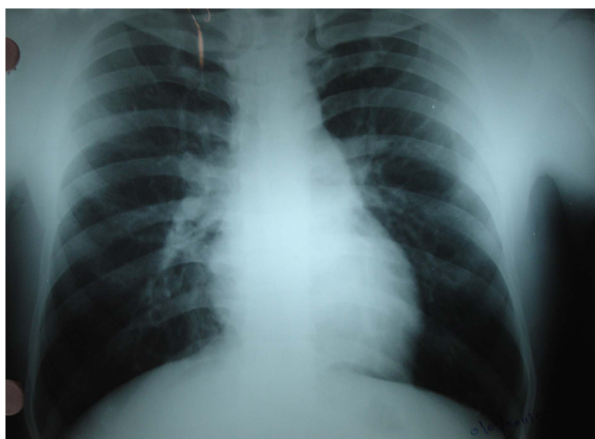

Figure 8 Chest radiograph on day 3 of admission (case 2) showing resolution of air space opacities seen on D1 roentgenogram.

particularly dangerous.¹ In our patients, HACO was coexisting with HAPO, but there were no features of AMS. HACO is a sequence of cerebral effects of high altitude, which can progress to a life-threatening encephalopathic stage. A prevalence of 0.5–1.0% of HACO is observed in individuals reaching a height >4500 m.²

Pathophysiologically, increased hydrostatic pressure, cytokines or chemical mediators damage vessel walls, leading to microhaemorrhages in HACO. These microhaemorrhages are usually seen only in individuals of non-fatal HACO, but not with AMS. These haemorrhages can be seen many months after the acute attack and are generally present in corpus callosum.³ Owing to increased permeability of the blood–brain barrier, intracellular and extracellular water accumulation takes place, leading to cerebral oedema.^{4,5} Evidence of cerebral oedema has been seen in the autopsies of military personnel and trekkers who had died of HACO.⁶ Ring haemorrhages have also been seen in autopsies of individuals who expired due to HACO.⁷

The oedema in HACO is generally due to blood–brain barrier leakage and is vasogenic in aetiology. The CT findings in HACO

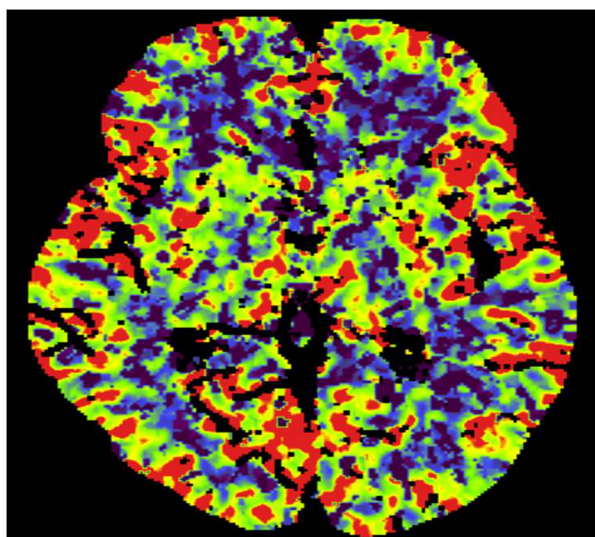


Figure 9 CT perfusion imaging on day 5 of the hospitalisation (case 2) revealing reversible perfusion defects in the anterior cerebral artery territory.

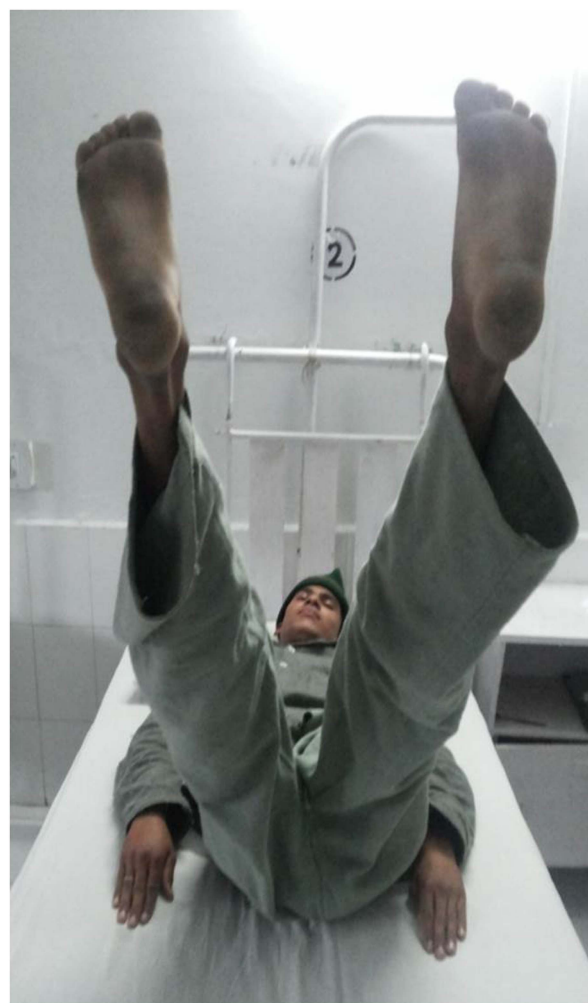

Figure 10 The patient described in case 2 showing normal power in both lower limbs after the treatment.

are: diffuse hypodense appearance of the entire cerebrum with small compressed ventricles and cisterns, and disappearance of sulci. The CT findings in our patient correlate with the vasogenic type of oedema. MRI is much more sensitive than CT in detecting early changes of HACO in brain parenchyma. The characteristic findings on MRI are vasogenic oedema and increased T2 signal in the white matter, especially in the splenium of the corpus callosum and no grey matter oedema.

The non-invasive technique of optic nerve sheath ultrasonography allows measurement of ONSD, which correlates with intracranial pressure (ICP). Measurement of ONSD has a stronger association in the presence of AMS and correlates with the severity of AMS than any prior assessment tool. The physiological basis of this technique is that increase in ICP is transmitted by the cerebrospinal fluid down the perineural subarachnoid space of the optic nerve, causing an expansion of the nerve sheath that can be measured by ultrasound.⁸ In our cases, patients had increased ONSD (normal <5 mm) which subsided to normal with treatment.

HACO generally presents with headache, change in level of consciousness (70%), unsteady gait (61%), breathlessness, lethargy and other behavioural changes, which can later progress to coma and death.⁹ Other neurological features noted in a case series of 44 patients by Dickson *et al* include, papilloedema (52%), urinary retention or incontinence (48%), abnormal

plantar reflexes (34%), abnormal limb tone and power (14%), abducens nerve palsy, pupil difference, visual field loss, speech difficulty, hearing loss and flapping tremor.¹⁰ Other neurological findings, as observed during high-altitude ascent in many studies, include impairment of memory,¹¹ metamemory,¹² psychomotor skills,^{13 14} cognition, learning, language, perception and mathematics.¹⁵ These neuropsychological changes generally relate to rate and height of ascent. Focal neurological deficit simulating stroke, as seen in our cases, has rarely been reported. The pathophysiology explaining the presentation of our patients (hemi/ monoplegia) remains conjectural. In the absence of MRI, it would be difficult to comment on the exact aetiopathogenesis. Possibly, raised ICP could have led to transient ischaemic attack, which promptly reversed with appropriate therapy. False localisation, secondary to uncus herniation, can explain long-tract signs in patients with cerebral oedema. In our case, CT scan during the neurological deficit did not reveal any herniation.

The perfusion deficits in the second case, with the presentation of lower limb weakness, may be due to ACA territory ischaemic infarction. However, recent arrival to high altitude, associated features of HAPo, absence of vascular comorbidities, age of the individual and presence of associated evidence of vasogenic oedema point to a diagnosis of HACO. The decision-making in such cases becomes difficult when treatment for the two conditions is divergent. Thrombolysis in HACO would have led to haemorrhagic transformation and at the other end dexamethasone is not advisable in case of ischaemic stroke. The second case raises the possibility of vascular compression and perfusion defects as a probable aetiology for neurological

manifestations in HACO, which needs to be evaluated in larger studies.

The recovery time in HACO has been reported to be 3–14 days¹⁵ and average time of 2.4 weeks in series by Hackett *et al.*⁵ In our case, patients were hospitalised for 14 days with complete functional and radiological recovery achieved by days 3–5 of admission.

Acknowledgements Director General Armed Forces for the support in management of high-altitude illnesses.

Contributors UY, AG, SP and PPV were all involved actively in managing the patients. UY prepared the manuscript and is responsible for submitting the paper.

Competing interests None.

Patient consent Obtained.

Provenance and peer review Not commissioned; externally peer reviewed.

REFERENCES

- Clarke C. High altitude cerebral oedema. *Int J Sports Med* 1988;9:170–4.
- Hackett PH, Rennie D, Levine HD. The incidence, importance, and prophylaxis of acute mountain sickness. *Lancet* 1976;2:1149–55.
- Kallenberg K, Dehnert C, Dorfler A, *et al.* Microhemorrhages in nonfatal high-altitude cerebral oedema. *J Cereb Blood Flow Metab* 2008;28:1635–42.
- Houston CS, Dickinson J. Cerebral form of high-altitude illness. *Lancet* 1975;2:758–61.
- Hackett PH, Yarnell PR, Hill R, *et al.* High-altitude cerebral oedema evaluated with magnetic resonance imaging: clinical correlation and pathophysiology. *JAMA* 1998;280:1920–5.
- Murkin JM, Adams SJ, Novick RJ, *et al.* Monitoring brain oxygen saturation during coronary bypass surgery: a randomized, prospective study. *Anesth Analg* 2007;104:51–8.
- Dickinson J, Health D, Gosney J, *et al.* Altitude-related deaths in seven trekkers in the Himalayas. *Thorax* 1983;38:646–56.
- Fagenholz PJ, Jonathan A, *et al.* Optic nerve sheath diameter correlates with the presence and severity of acute mountain sickness: evidence for increased intracranial pressure. *J Appl Physiol* 2009;106:1207–11.
- Hackett PH, Roach RC. High altitude cerebral oedema. *High Alt Med Biol* 2004;5:136–46.
- Dickinson JG. High altitude cerebral oedema: cerebral acute mountain sickness. *Semin. respir. Med* 1983;151–8.
- Pelamatti G, Pascotto M, Semenza C. Verbal free recall in high altitude: proper names vs common names. *Cortex* 2003;39:97–103.
- Du JY, Li XY, Zhuang Y, *et al.* Effects of acute mild and moderate hypoxia on human short memory. *Space Med Eng* 1999;12:270–3.
- Virues-Ortega J, Buela-Casal G, Garrido E, *et al.* Neuropsychological functioning associated with high-altitude exposure. *Neuropsychol Rev* 2004;14:197–224.
- Bouquet CA, Gardette B, Gortan C, *et al.* Psychomotor skills learning under chronic hypoxia. *Neuroreport* 1999;10:3093–9.
- Wu X, Li X, Han L, *et al.* Effects of acute moderate hypoxia on human performance of arithmetic. *Space Med Med Eng* 1998;11:391–5.

Learning points

- Careful differentiation between stroke and high-altitude cerebral oedema (HACO) is important in rural high-altitude medical practice.
- HACO can present with reversible focal neurological deficits mimicking stroke.
- Thrombolysis is contraindicated if HACO exists.
- Prompt therapy can lead to complete recovery of deficits in these patients

Copyright 2014 BMJ Publishing Group. All rights reserved. For permission to reuse any of this content visit <http://group.bmj.com/group/rights-licensing/permissions>.
BMJ Case Report Fellows may re-use this article for personal use and teaching without any further permission.

Become a Fellow of BMJ Case Reports today and you can:

- Submit as many cases as you like
- Enjoy fast sympathetic peer review and rapid publication of accepted articles
- Access all the published articles
- Re-use any of the published material for personal use and teaching without further permission

For information on Institutional Fellowships contact consortiasales@bmjgroup.com

Visit casereports.bmj.com for more articles like this and to become a Fellow