



Pure subdural haematoma caused by rupture of middle cerebral artery aneurysm: Case report and literature review

Jie Gong, Hu Sun, Xiao-Yong Shi, Wei-Xian Liu and Zheng Shen

Abstract

Pure subdural haematoma (occurring without detectable subarachnoid haemorrhage) caused by intracranial aneurysm rupture is uncommon and is usually associated with delayed diagnosis and treatment. We describe the case of a 43-year-old man who presented with ongoing headache. Computed tomography and magnetic resonance imaging of the brain revealed subdural haematoma in the left fronto-temporo-parietal region, without subarachnoid haemorrhage. Digital subtraction angiography showed an aneurysm measuring ≤ 5 mm in diameter, arising from the distal region of the left middle cerebral artery. During hospitalization, an acute change in mental status accompanied by slurred speech and narcolepsy prompted an emergency CT scan. This revealed an enlargement of the subdural haematoma. The patient underwent an emergency craniotomy, during which a large amount of bloody fluid was evacuated, and the aneurysm was coagulated and resected. The patient had a good outcome without neurological deficit. The incidence, mechanisms and treatment of this condition are discussed.

Keywords

Subdural haematoma, intracranial aneurysm, middle cerebral artery

Date received: 6 December 2013; accepted: 30 January 2014

Introduction

Aneurysms of the middle cerebral artery (MCA) comprise 20–30% of all intracranial aneurysms.^{1,2} Intracranial aneurysm rupture is classically characterized by

subarachnoid haemorrhage and intracerebral haematoma. Pure subdural haematoma (occurring without detectable subarachnoid haemorrhage) caused by intracranial

Corresponding author:

Jie Gong, Department of Neurosurgery, Zhejiang Hospital, 12 Lingyin Road, Hangzhou 310013, Zhejiang Province, China.

Email: orchidwave@163.com

Department of Neurosurgery, Zhejiang Hospital, Hangzhou, Zhejiang Province, China



aneurysm rupture is uncommon.^{3,4} We report a case of pure subdural haematoma secondary to MCA aneurysm rupture.

Case report

A 43-year-old man presented at the Department of Neurosurgery, Zhejiang Hospital, Hangzhou China on 13 August 2010 with a history of headache for 8 days. He reported no loss of consciousness,

nausea, vomiting, dizziness or neurological deficit. The patient had no explicit history of head trauma, hypertension or coagulopathy. Emergency computed tomography (CT) and magnetic resonance imaging of the head revealed subdural haematoma in the left fronto-temporo-parietal region without subarachnoid haemorrhage or intracerebral haematoma (Figure 1A–C). No aneurysm or arteriovenous malformation was detected on CT angiography. As the haematoma

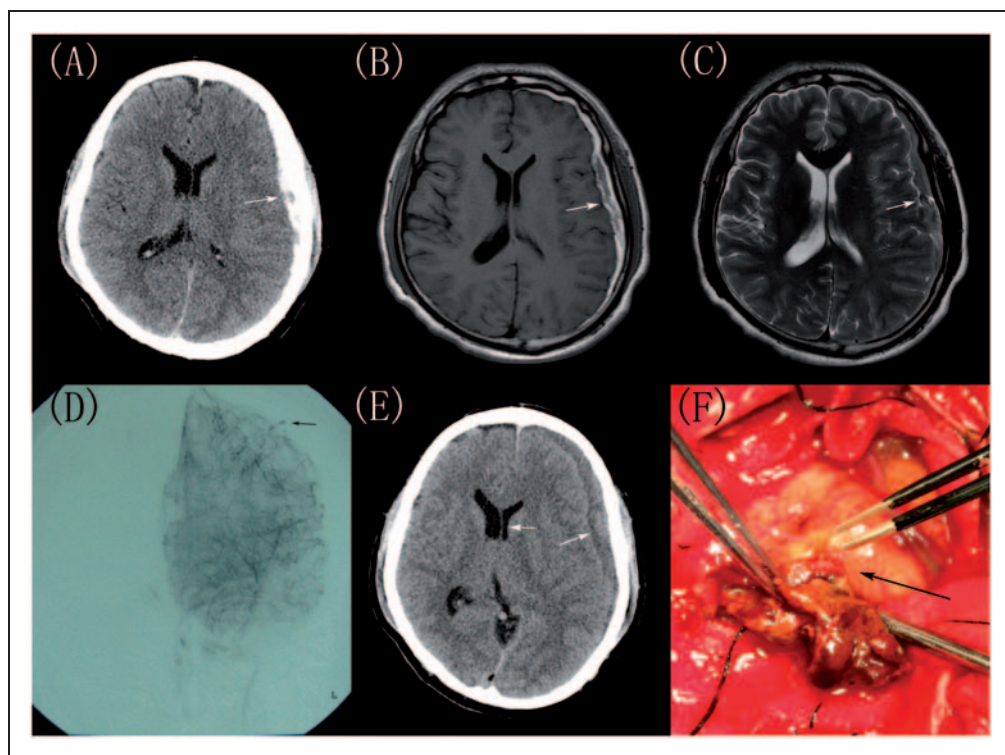


Figure 1. Brain images from a 43-year-old man presenting with a history of headache for 8 days. (A) Axial noncontrast computed topography (CT) scan showing a lunar hyperdense lesion in the left fronto-temporo-parietal region with no evidence of subarachnoid haemorrhage (white arrow); (B) T₁-weighted magnetic resonance image (MRI) revealing the haematoma as high intensity with isointense components (white arrow); (C) T₂-weighted MRI revealing the haematoma as low intensity with high intensity components (white arrow); (D) Angiogram of the left middle cerebral artery (MCA) revealing a small aneurysm located in the distal region of the MCA (black arrow); (E) Axial noncontrast CT scan showing mixed-density haematoma in the left fronto-temporo-parietal region with midline shift (white arrows); (F) Intraoperative view, confirming a small MCA aneurysm embedded in the subdural haematoma (black arrow). The colour version of this figure is available at: <http://imr.sagepub.com>.

showed no signs of enlargement, emergency craniotomy was not recommended at initial presentation but the patient was admitted to hospital.

Digital subtraction angiography performed 6 days after hospitalization showed normal appearance of the right internal carotid artery (ICA), MCA and anterior cerebral artery (ACA). An aneurysm measuring <5 mm in diameter was seen arising from the left distal region of the MCA, and was accompanied by an occluded left A1 segment of the ACA. The dome of the aneurysm was oriented towards the subdural space. No vasospasm was present (Figure 1D). Due to the small size of the aneurysm and lack of any accompanying subarachnoid haemorrhage, it was unclear whether the aneurysm was the underlying cause of the subdural haematoma and craniotomy was therefore not pursued at that time.

However, 8 days after hospitalization, the patient developed an acute change in mental status accompanied by slurred speech and narcolepsy, prompting an emergency CT scan. Enlargement of the left-sided subacute subdural haematoma was revealed as a mixed-density subdural lesion, indicating subacute haemorrhage, and was accompanied by a new slight midline shift (Figure 1E). The patient underwent an emergency craniotomy, during which an MCA aneurysm was seen: this was embedded within the subacute subdural haematoma, with the dome of the aneurysm fused to the thick parietal layer of the subdural haematoma capsule (Figure 1F). A large amount of bloody fluid was evacuated, the site was irrigated with normal saline, and the aneurysm was coagulated and resected. No evidence of subarachnoid blood was seen intraoperatively.

Histopathology of the resected tissue revealed the formation of a fibrous wall around the aneurysm. The patient had an unremarkable postoperative course, without

neurological deficit or subjective discomfort. The patient was discharged from hospital 14 days postoperatively.

Discussion

Intracranial aneurysms usually present as subarachnoid haemorrhages or intracerebral haematomas, with only 0.5–7.9% being accompanied by subdural haematomas.^{5–9} Pure subdural haematoma caused by intracranial aneurysm is extremely rare.^{5,10} We describe a case of ruptured MCA aneurysm presenting as pure subdural haematoma, without radiographic evidence of subarachnoid haemorrhage or intracerebral haematoma at any point during hospitalization. An additional 40 similar cases of pure subdural haematoma caused by intracranial aneurysm have been reported since 1980 (Table 1).^{3–8,10–35} The average age at presentation was 46.6 years, with 27/41 patients (65.9%) being female. The site of aneurysm included ICA-posterior communicating artery (PcomA; 16 cases, 39.0%), MCA (10 cases, 24.4%; including the present case), anterior communicating artery (AcomA; six cases, 14.6%), distal ACA (four cases, 9.8%) and other sites (five cases, 12.2%). Subdural haematoma may be located in the cerebral convexity (24 cases, 58.5%; including the present case), both convexity and tentorium (seven cases, 17.1%) and other locations (nine cases, 22.0%). The most common treatment was haematoma evacuation and clipping (19 cases, 46.3%). Haematoma evacuation and aneurysm resection was used in two cases (4.9%; including the present case). The majority of patients had a good outcome (25 cases, 61.0%; including the present case).

Several mechanisms have been proposed to explain pure subdural haematoma caused by intracranial aneurysm: (i) minor haemorrhages may cause adhesion of the aneurysm to the arachnoid membrane with a final

Table 1. Reported cases of pure subdural haemorrhage caused by rupture of intracranial aneurysm.

Author(s)	Year of publication	Age	Sex	Symptoms/signs	Location of aneurysm	Location of subdural hematoma	Treatment	Outcome
Rengachary and Szymanski ¹¹	1981	49	M	Confusion, dysphagia	MCA	Convexity	Haematoma evacuation and clipping	Good
Eggers et al ¹²	1982	34	F	Headache	ICA-PcomA	Convexity	Haematoma evacuation	Good
Williams et al ¹³	1983	18	F	Coma	ICA-PcomA	Convexity	Haematoma evacuation and clipping	Disabled
Friedman and Brandt-Zawadzki ¹⁴	1983	55	F	Headache	ICA-PcomA	Tentorium and interhemispheric	Clipping	Good
O'Leary and Sweeny ¹⁵	1986	28	F	Coma	MCA	Convexity	None	Death
Kondziolka et al ¹⁶	1988	43	M	Coma	ICA-PcomA	Tentorium and convexity	Haematoma evacuation and clipping	Good
Kondziolka et al ¹⁶	1988	38	F	Coma	ICA-PcomA	Tentorium and convexity	Haematoma evacuation and clipping	Disabled
Shinmura et al ¹⁷	1989	53	F	Coma	MCA	Convexity	Haematoma evacuation and clipping	Disabled
Onda et al ¹⁸	1989	44	F	Semicoma	ICA-PcomA	Convexity	Haematoma evacuation and clipping	Disabled
Watanabe et al ⁶	1991	51	M	Semicoma	Distal ACA	Interhemispheric and convexity	Haematoma evacuation and clipping	Death
Ragland et al ¹⁹	1993	27	M	Coma	AcomA	Convexity	Haematoma evacuation and clipping	Death
Hatayama et al ²⁰	1994	55	M	Semicoma	Distal ACA	Interhemispheric and convexity	Haematoma evacuation and clipping	Good
Hatayama et al ²⁰	1994	66	F	Semicoma	Distal ACA	Interhemispheric, convexity, and tentorium	Haematoma evacuation and clipping	Disabled
Ishibashi et al ²¹	1997	54	F	Headache	ICA-PcomA	Tentorium and convexity	Haematoma evacuation and clipping	Good
Sato et al ²²	1999	58	F	Semicoma	ICA-PcomA	Convexity	Haematoma evacuation and clipping	Good

(continued)

Table 1. Continued.

Author(s)	Year of publication	Age	Sex	Symptoms/signs	Location of aneurysm	Location of subdural hematoma	Treatment	Outcome
Satoh et al ²²	1999	25	F	Headache	ICA-PcomA	Convexity	Haematoma evacuation and clipping	Good
Satoh et al ²²	1999	22	F	Coma	ICA-PcomA	Convexity	Haematoma evacuation and clipping	Good
Huang et al ²³	1999	61	F	Headache	MCA	Tentorium and convexity	Clipping	Good
Nonaka et al ²⁴	2000	52	F	Coma	ICA-PcomA	Tentorium and convexity	Haematoma evacuation and clipping	Good
Ishikawa et al ²⁵	2000	62	M	Headache, ptosis	ICA-PcomA	Tentorium and interhemispheric	Clipping	Good
Inamasu et al ²⁶	2002	28	F	Coma	ICA-PcomA	Convexity	Haematoma evacuation	Death
Araki et al ²⁷	2002	55	F	Headache, ptosis, semicoma	ICA-PcomA	Convexity	Haematoma evacuation and clipping	Good
Nozar et al ⁴	2002	56	M	Headache, drowsiness	AcomA	Convexity	Haematoma evacuation	Death
Nozar et al ⁴	2002	28	M	Headache	PcomA	Convexity	Haematoma evacuation and clipping	Good
Nozar et al ⁴	2002	39	F	Headache	PcomA	Convexity	Coiling	Good
Nozar et al ⁴	2002	46	M	Coma	MCA	Convexity	Haematoma evacuation and clipping	Death
Blake et al ²⁸	2003	35	F	Coma	ICA-PcomA	Convexity	None	Death
Katsuno et al ²⁹	2003	63	F	Headache, nausea, dizziness	Distal ACA	Interhemispheric and convexity	Haematoma evacuation and clipping	Good
Krishnaney et al ⁷	2004	42	F	Headache, photophobia	AcomA	Tentorium and convexity	Haematoma evacuation and clipping	Good
Koerbel et al ⁸	2005	62	F		Bifurcation of ICA	Convexity		Good

(continued)

Table 1. Continued.

Author(s)	Year of publication	Age	Sex	Symptoms/signs	Location of aneurysm	Location of subdural hematoma	Treatment	Outcome
Triantafyllopoulou et al ³⁰	2006	65	F	Headache, semicoma Headache, nausea, vomiting, ptosis	ICA	Convexity and cavernous sinus	Haematoma evacuation and coiling Haematoma evacuation	Comatose
Gilad et al ³¹	2007	47	M	Nausea, vomiting	AcomA	Sella, migrating to spinal canal	Coiling	Good
Kocak et al ³²	2009	47	F	Not described	AcomA	Not described	Clipping	Good
Kurabe et al ³³	2010	75	M	Headache, vomiting	MCA	Anterior fossa	Haematoma evacuation and resection	Not described
Field and Heran ³⁴	2010	33	M	Headache, Terson syndrome	MCA	Convexity	Not described	Not described
Weil et al ³⁵	2010	51	F	Coma	MCA	Convexity	Haematoma evacuation and coiling	Disabled
De Blasi et al ³	2010	47	F	Headache, stupor	ICA-PcomA	Convexity	Coiling	Good
De Blasi et al ³	2010	60	F	Headache, abducens palsy	MCA	Convexity	Clipping	Good
Takada ⁵	2012	54	M	Headache	AcomA	Tentorium and convexity	Clipping	Good
Mirfka ¹⁰	2012	40	F	Headache, nausea, vomiting	PcomA	Convexity	Haematoma evacuation and coiling	Good
Present case	2014	43	M	Headache	MCA	Convexity	Haematoma evacuation and resection	Good

MCA, middle cerebral artery; ICA, internal carotid artery; PcomA, posterior communicating artery; AcomA, anterior communicating artery.

bleed occurring into the subdural space;^{10,24,25,31} (ii) high-pressure haemorrhage from the ruptured aneurysm may lacerate the arachnoid membrane;^{25,26,31,32} (iii) intracerebral bleeding may rupture the cortex and tear the arachnoid membrane;^{21,26} (iv) enlargement of the intracavernous aneurysm could erode the wall of the cavernous sinus;^{5,32} (v) a carotid artery aneurysm located in the subdural space may cause subdural haematoma directly.^{21,36,37}

Clinical and radiographical findings in the present case indicate that the patient experienced two discrete episodes of aneurysm rupture. The first manifested as headache, indicating that blood from the aneurysm had penetrated the arachnoid membrane into the subdural cavity. The second rupture, which occurred 16 days after the first, manifested as narcolepsy and slurred speech, implying enlargement of the subarachnoid haemorrhage. The tight adhesions that were observed intraoperatively strongly support the first mechanism described above.

In conclusion, pure subdural haematoma can be caused by rupture of intracranial aneurysm. The rarity of this condition can lead to delays in diagnosis and treatment, as occurred in the present case.^{4,7,26,30,31} In addition, the mild symptoms (which may occur several days before admission) are unusual for aneurysm rupture, and intracranial aneurysm bleeding is often ruled out in the absence of subarachnoid haemorrhage. Aneurysm rupture should be strongly considered, however, if a patient presents with a pure subdural haematoma without history of trauma or coagulopathy. CT angiography and/or digital subtraction angiography should be performed, and treatment (including clipping and/or haematoma evacuation) should be conducted promptly, depending on the location of the aneurysm and the clinical situation. Timely diagnosis and suitable treatment are both critical in the management of this rare condition.

Declaration of conflicting interest

The authors declare that there are no conflicts of interest.

Funding

This research received no specific grant from any funding agency in the public, commercial, or not-for-profit sectors.

References

1. Shim YS, Moon CT, Chun YI, et al. Grading of intracerebral hemorrhage in ruptured middle cerebral artery aneurysms. *J Korean Neurosurg Soc* 2012; 51: 268–271.
2. Lee CS, Park JU, Kang JG, et al. The clinical characteristics and treatment outcomes of patients with ruptured middle cerebral artery aneurysms associated with intracerebral hematoma. *J Cerebrovasc Endovasc Neurosurg* 2012; 14: 181–185.
3. De Blasi R, Salvati A, Renna M, et al. Pure subdural hematoma due to cerebral aneurysmal rupture: an often delayed diagnosis. *Cardiovasc Intervent Radiol* 2010; 33: 870–873.
4. Nozar A, Philippe D, Fabrice P, et al. Acute pure spontaneous subdural haematoma from ruptured intracranial aneurysms. *Interv Neuroradiol* 2002; 8: 393–398.
5. Takada T, Yamamoto T, Ishikawa E, et al. Acute subdural hematoma without subarachnoid hemorrhage caused by ruptured A1-A2 junction aneurysm. Case report. *Neurol Med Chir (Tokyo)* 2012; 52: 430–434.
6. Watanabe K, Wakai S, Okuhata S, et al. Ruptured distal anterior cerebral artery aneurysms presenting as acute subdural hematoma – report of three cases. *Neurol Med Chir (Tokyo)* 1991; 31: 514–517.
7. Krishnaney AA, Rasmussen PA and Masaryk T. Bilateral tentorial subdural hematoma without subarachnoid hemorrhage secondary to anterior communicating artery aneurysm rupture: a case report and review of the literature. *AJNR Am J Neuroradiol* 2004; 25: 1006–1007.

8. Koerbel A, Ernemann U and Freudenstein D. Acute subdural haematoma without subarachnoid haemorrhage caused by rupture of an internal carotid artery bifurcation aneurysm: case report and review of literature. *Br J Radiol* 2005; 78: 646–650.
9. Barton E and Tudor J. Subdural haematoma in association with intracranial aneurysm. *Neuroradiology* 1982; 23: 157–160.
10. Mrfka M, Pistracher K, Augustin M, et al. Acute subdural hematoma without subarachnoid hemorrhage or intraparenchymal hematoma caused by rupture of a posterior communicating artery aneurysm: case report and review of the literature. *J Emerg Med* 2013; 44: e369–e373.
11. Rengachary SS and Szymanski DC. Subdural hematomas of arterial origin. *Neurosurgery* 1981; 8: 166–172.
12. Eggers FM, Tomsick TA, Lukin RR, et al. Recognition of subdural hematoma secondary to ruptured aneurysm by computerized tomography. *Comput Radiol* 1982; 6: 309–313.
13. Williams JP, Joslyn JN, White JL, et al. Subdural hematoma secondary to ruptured intracranial aneurysm: computed tomographic diagnosis. *J Comput Tomogr* 1983; 7: 142–153.
14. Friedman MB and Brant-Zawadzki M. Interhemispheric subdural hematoma from ruptured aneurysm. *Comput Radiol* 1983; 7: 129–134.
15. O’Leary PM and Sweeny PJ. Ruptured intracerebral aneurysm resulting in a subdural hematoma. *Ann Emerg Med* 1986; 15: 944–946.
16. Kondziolka D, Bernstein M, ter Brugge K, et al. Acute subdural hematoma from ruptured posterior communicating artery aneurysm. *Neurosurgery* 1988; 22: 151–154.
17. Shinmura F, Nakajima S, Maruyama T, et al. A case of ruptured middle cerebral artery aneurysm with acute subdural hematoma after clipping of the aneurysm nine years previously. *No Shinkei Geka* 1989; 17: 1175–1179. [in Japanese, English Abstract].
18. Onda J, Kodama Y, Emoto K, et al. A case report of “pure” acute subdural hematoma secondary to ruptured intracranial aneurysm. *Kyukyū Igaku* 1989; 13: 631–634. [in Japanese, English Abstract].
19. Ragland RL, Gelber ND, Wilkinson HA, et al. Anterior communicating artery aneurysm rupture: an unusual cause of acute subdural hemorrhage. *Surg Neurol* 1993; 40: 400–402.
20. Hatayama T, Shima T, Okada Y, et al. Ruptured distal anterior cerebral artery aneurysms presenting with acute subdural hematoma: report of two cases. *No Shinkei Geka* 1994; 22: 577–582. [in Japanese, English Abstract].
21. Ishibashi A, Yokokura Y and Sakamoto M. Acute subdural hematoma without subarachnoid hemorrhage due to ruptured intracranial aneurysm – case report. *Neurol Med Chir (Tokyo)* 1997; 37: 533–537.
22. Satoh K, Sasaki T, Osato T, et al. Intracranial aneurysm presenting as acute subdural hematoma without subarachnoid hemorrhage: report of three cases. *J Hokkaido Brain Res Found* 1999; 8: 27–31.
23. Huang D, Abe T, Kojima K, et al. Intracystic hemorrhage of the middle fossa arachnoid cyst and subdural hematoma caused by ruptured middle cerebral artery aneurysm. *AJNR Am J Neuroradiol* 1999; 20: 1284–1286.
24. Nonaka Y, Kusumoto M, Mori K, et al. Pure acute subdural haematoma without subarachnoid haemorrhage caused by rupture of internal carotid artery aneurysm. *Acta Neurochir (Wien)* 2000; 142: 941–944.
25. Ishikawa E, Sugimoto K, Yanaka K, et al. Interhemispheric subdural hematoma caused by a ruptured internal carotid artery aneurysm: case report. *Surg Neurol* 2000; 54: 82–86.
26. Inamasu J, Saito R, Nakamura Y, et al. Acute subdural hematoma caused by ruptured cerebral aneurysms: diagnostic and therapeutic pitfalls. *Resuscitation* 2002; 52: 71–76.
27. Araki T, Sampei T, Murata H, et al. A case of internal carotid-posterior communicating artery aneurysm presenting pure acute subdural hematoma. *No Shinkei Geka* 2002; 30: 861–866. [in Japanese, English Abstract].
28. Blake G, James M, Ramjit C, et al. Acute subdural haematoma without subarachnoid

- haemorrhage caused by rupture of an intracranial aneurysm. *West Indian Med J* 2003; 52: 80–81.
29. Katsuno M, Murai Y and Teramoto A. Acute subdural hematoma without subarachnoid hemorrhage following rupture of a distal anterior cerebral artery aneurysm: a case report. *No To Shinkei* 2003; 55: 435–438. [in Japanese, English Abstract].
 30. Triantafyllou A, Beaumont A, Ulatowski J, et al. Acute subdural hematoma caused by an unruptured, thrombosed giant intracavernous aneurysm. *Neurocrit Care* 2006; 5: 39–42.
 31. Gilad R, Fatterpekar GM, Johnson DM, et al. Migrating subdural hematoma without subarachnoid hemorrhage in the case of a patient with a ruptured aneurysm in the intrasellar anterior communicating artery. *AJNR Am J Neuroradiol* 2007; 28: 2014–2016.
 32. Kocak A, Ates O, Durak A, et al. Acute subdural hematomas caused by ruptured aneurysms: experience from a single Turkish center. *Turk Neurosurg* 2009; 19: 333–337.
 33. Kurabe S, Ozawa T, Fujiwara H, et al. Peripheral intracranial aneurysm causing subdural hematoma without subarachnoid hemorrhage. *Neurology* 2010; 74: 268.
 34. Field TS and Heran MK. Teaching NeuroImages: middle cerebral artery aneurysm rupture presenting as pure acute subdural hematoma. *Neurology* 2010; 74: e13.
 35. Weil AG, McLaughlin N, Lessard-Bonaventure P, et al. A misleading distal anterior cerebral artery aneurysm. *Surg Neurol Int* 2010; 1: 55.
 36. Nishikawa T, Ueba T, Kajiwarra M, et al. Bilateral acute subdural hematomas with intracerebral hemorrhage without subarachnoid hemorrhage, caused by rupture of an internal carotid artery dorsal wall aneurysm. Case report. *Neurol Med Chir (Tokyo)* 2009; 49: 152–154.
 37. Ho TL, Lee KW and Lee HJ. Acute massive subdural hematoma caused by rupture of internal carotid artery aneurysm during angiography: a case report. *Emerg Radiol* 2002; 9: 237–239.