

De novo cerebral arteriovenous malformations: is epileptic seizure a potential trigger?

Jun Wu · Yu Li · Yong Cao · Shuo Wang

Received: 23 December 2013 / Accepted: 27 March 2014
© Springer-Verlag Berlin Heidelberg 2014

Abstract

Material and methods The pathogenesis of cerebral arteriovenous malformations (cAVMs) is still not well understood. Generally, cAVMs are thought to be congenital lesions originating prenatally. We report a 7-year-old boy diagnosed with a de novo cAVM after 3 years of recurrent epileptic seizures.

Results MR imaging at 4 years of age was normal. Follow-up MR imaging 3 years later demonstrated a de novo 2-cm cAVM in the right occipital lobe, confirmed by conventional angiography. We reviewed five previously reported cases of de novo cAVMs who did not have a previous neurovascular abnormality. Including our case, recurrent epileptic seizures are the major presentation (83.3 %) before de novo cAVM occurrence.

Conclusion We suggest that epileptic seizure is a potential trigger of de novo cAVMs.

Keywords Cerebral arteriovenous malformations · De novo · Children · Epileptic seizure · Etiology · Angiogenesis

Introduction

Cerebral arteriovenous malformations (cAVMs) are vascular malformations in the brain characterized by arteriovenous shunt through a collection of tortuous vessels (nidus) without an intervening capillary bed [28]. cAVMs were traditionally thought to be congenital in origin [15]. However, cases of de

novo cAVM have been reported which challenge the traditional viewpoint [2–4, 6, 10, 11, 14, 16, 23–25, 27]. Here, we present a case of de novo cAVM in a child after 3 years of recurrent epilepsy and discuss the pathogenesis of de novo cAVMs and the influence of epileptic seizures on the cAVMs.

Case report

A 7-year-old boy (born in 2006) developed a fever when he was 4 years old (2010). During the fever, he suffered from sudden convulsions with teeth, fists clenched and eyes turned up, which lasted about 30 s. He was sent to the emergency department for symptomatic treatment. The first MR imaging revealed no abnormalities, or any sign of cAVM (Fig. 1a). The tentative diagnosis was febrile seizure, and the doctor suggested a clinical observation with no antiepileptic drugs. No neurological deficit was found after he recovered. In the following 3 years, the aforementioned seizures occurred annually. The symptoms recurred again on August 2013. A second MR imaging revealed an abnormal signal in the right occipital lobe of the T2-weighted scan (Fig. 1b). Visual field examination showed scotoma in the left visual field (Fig. 2a, b). The boy was then admitted to our hospital, and a right occipital lobe cAVM was confirmed by conventional angiography. The feeding artery of the cAVM came from the branches of the right posterior cerebral artery, and the cAVM drained to the sigmoid sinus and superior sagittal sinus via the superficial veins (Fig. 3a, b). A right occipital craniotomy was successfully performed to remove the 2-cm cAVM (Fig. 4a). Postoperative pathology confirmed the diagnosis of cAVM (Fig. 4b). Postoperative angiography revealed no cAVM residue (Fig. 3c, d). He recovered well after the operation except for the visual defect (Fig. 2c, d).

J. Wu · Y. Li · Y. Cao · S. Wang (✉)
Department of Neurosurgery, Beijing Tiantan Hospital, Capital Medical University, No.6 Tiantanxili, Dongcheng district 100050 Beijing, China
e-mail: captain9858@vip.sina.com

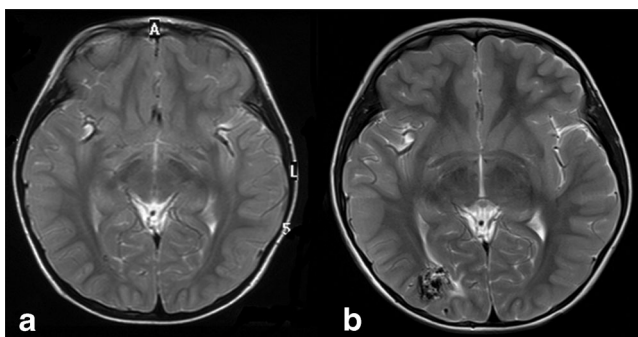


Fig. 1 **a** Axial T2-weighted MRI obtained in 2010; there is no evidence of any vascular lesion. **b**: Axial T2 MRI obtained in 2013, demonstrating an irregular tangle of vessels in right occipital lobe

Literature review

We reviewed the published cases of de novo cAVMs using the search term “de novo” and “cerebral arteriovenous malformations” in PUBMED. A total of 12 cases of de novo cAVMs were found [2–4, 6, 10, 11, 14, 16, 23–25, 27]. Among the total 13 cases of de novo cAVMs, six had accompanying cerebral vascular diseases and one had radiotherapy for medulloblastoma (Table 1). The remaining six cases including ours had no history of cerebral vascular disease or brain tumor. Of these six cases, five (83.3 %) had recurrent epileptic seizures, half were children, and only one patient had a prior history of hemorrhage. The other five only had a history of epilepsy seizures before the de novo cAVMs were

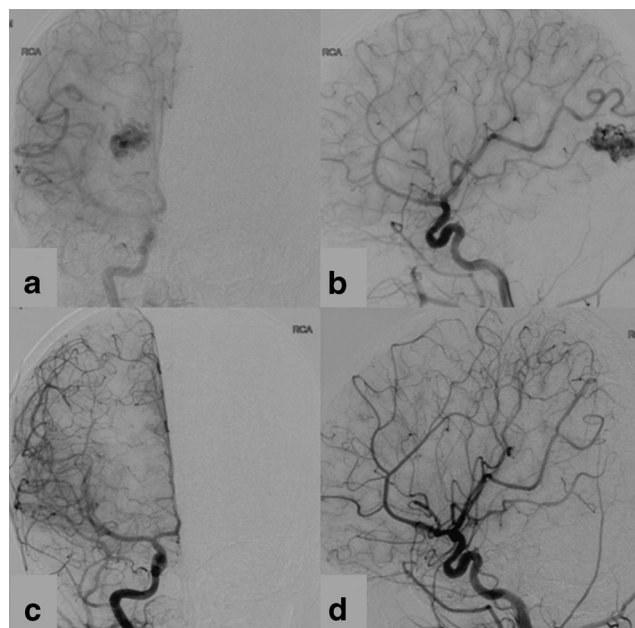


Fig. 3 **a, b** Preoperative conventional angiography showed the cAVM was located in the right occipital lobe. **c, d**: Postoperative conventional angiography revealed that the cAVM was totally removed

found. In these five patients, one girl had a history of traumatic brain injury 4 years ago and another girl showed developmental delay (Table 2).

Discussion

We present a rare case of de novo cAVM formation in a child with a long history of epilepsy before the lesion was found. We also reviewed five previously reported cases of de novo cAVMs with no previous neurovascular abnormalities. Including our case, epileptic seizures are the major presentation (83.3 %) before de novo cAVM occurrence, whereas in the ordinary cAVMs patients, seizures as initial presentation occur in less than 30 % of patients [7].

The pathogenesis of cAVMs is not completely understood. It has been suggested that cAVMs are primarily congenital, originating at or before the 40 to 80-mm embryo length stage

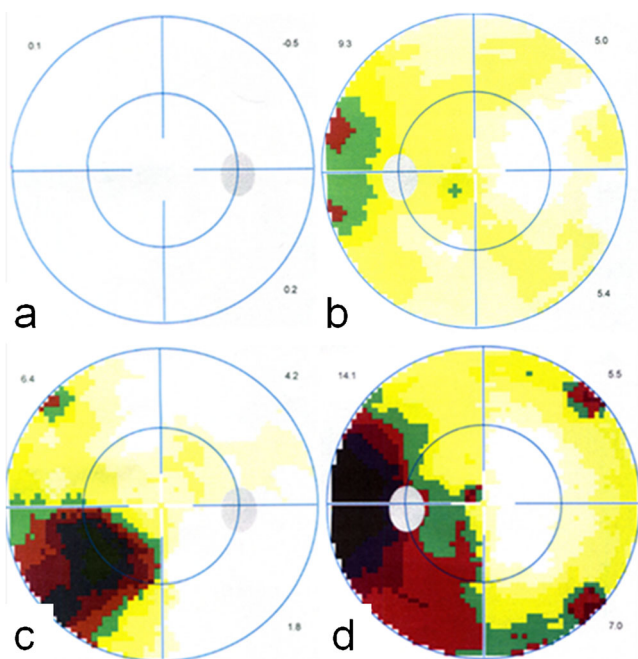


Fig. 2 **a, b**: Preoperative visual field examination showed scotoma in left visual field and normal right visual field. **c, d**: Postoperative visual field examination showed left a temporal visual field deficit which was more serious after the operation

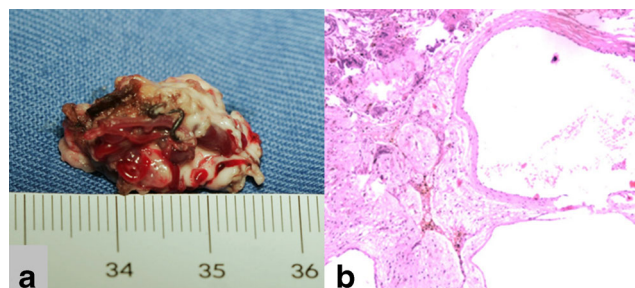


Fig. 4 **a** The resected cAVM specimen which clearly shows the abnormal blood vessels (units: cm). **b** Postoperative pathology confirmed the diagnosis of cAVM (HE, ×100)

Table 1 Summary of de novo cAVM patients with a history of cerebral vascular disease or brain tumor

Authors and year	Age	Gender	Symptoms of the de novo cAVM	Location of the de novo cAVM	Preexisting condition or illness	Treatment	Outcome
Schmit et al. 1996	11	Male	Ischemic epileptic seizure	Left parietal lobe	Moyamoya disease	NA	NA
Jonathan A. Fridenman et al. 2000	60	Male	NA	Vermis of cerebellum	Dural arteriovenous fistula (DAVF) Radiosurgery of the DAVF	Radiosurgery	Well
Akimoto et al. 2003	27	Female	Hemorrhage	Cingulate gyrus	Previous cAVMs located in splenium of corpus callosum and left occipital lobe, both totally removed	Microsurgery	Well
O'Shaughnessy et al. 2005	6	Female	NA	Right temporal lobe	Sickle cell disease Moyamoya disease	Microsurgery	Well
Hortensia Alvarez et al. 2012	6	Male	NA	Third ventricle	Cavernous malformation	NA	NA
Yahui Bai et al. 2012	7	Male	Epileptic seizure	Left occipital lobe	Cerebral arteriovenous fistula (CAVF)	Embolization	Well
Bertrand et al. 2013	9	Male	NA	Right temporal lobe	Radiosurgery after surgery of medulloblastoma	NA	NA

and may be related to a primary abnormality of primordial capillary or venous formation [19]. However, our case and a few previous reports of de novo cAVMs challenge the concept that cAVMs are purely congenital lesions. These reports suggest that actually cAVMs are not static lesions; growth, shrinkage, and spontaneous resolution of cAVMs with time have been documented [1, 5, 17, 18]. From the dynamic nature of cAVMs, it is possible that acquired inciting events might be the catalyst for the formation of cAVMs later in life. Desal et al. reported a case of the development of multiple de novo vascular malformations (transverse sinus, dural fistula, and posterior fossa cavernomas) following acoustic neuroma surgery. They speculated that venous occlusive disease and ischemia may be powerful revealing triggers and support the capillary venous origin of some vascular malformations [8].

Seizures contribute to hypoxic-ischemic brain injury, particularly in childhood. In ischemic brain regions, abundant potent angiogenic factors like vascular endothelial growth

factor (VEGF) can be produced [22, 26]. Studies of seizure-prone patients with cAVMs reveal impaired peri-nidal cerebral reserve and concomitant venous congestion [9]. Additionally, research has shown that VEGF is upregulated in neurons and glial cells after epileptic seizures and counteracts seizure-induced neurodegeneration [21].

It has been proposed that overstimulated angiogenesis may lead to cAVMs. VEGF may be a key link between insult and cAVM formation. In animal models, deletion of the ALK1 gene can induce cAVM formation [29]. Gene microarray analysis of human cAVMs demonstrated increased VEGF gene expression levels for angiogenesis, accompanied by increased protein product [12]. It has been proven that the notch signaling pathway is an important molecular candidate in cAVM pathogenesis, which seems to depend on local levels of VEGF [20].

William L. Young. et al. proposed a “response-to-injury” model of cAVM pathogenesis [13]. An inciting event turns on

Table 2 Summary of de novo cAVM patients with no history of cerebral vascular disease or brain tumor

Authors and year	Age	Gender	Symptoms of the de novo cAVM	Location of the de novo cAVM	Preexisting condition or illness	Treatment	Outcome
Bulsara et al. 2002	32	Female	Hemorrhage	Right temporal lobe	Severe <i>streptococcal</i> throat infection 6 years ago	Microsurgery	Well
Gonzalez et al. 2005	7	Female	Epileptic seizure	Right temporal lobe	Traumatic brain injury 4 years ago	Radiosurgery	NA
Stevens et al. 2009	9	Female	Increased seizure activity Aphasia after minor head injury	Left temporal occipital lobe	Developmental delay	Radiosurgery	Well
Amit et al. 2010	30	Female	Epileptic seizure	Left frontal parietal lobe	Bell's palsy migraines	NA	NA
Murat Ozsarac et al. 2012	50	Male	Epileptic seizure	Left temporal parietal lobe	NA	Conservative treatment	Well
Our case 2013	7	Male	Epileptic seizure	Right parietal lobe	NA	Microsurgery	Well

the cAVM pathogenesis pathway which can involve angiogenesis, endothelial mitogenesis, and vascular stabilization. When this response is superimposed on an underlying structural defect or genetic background, the normal injury response may shift towards an abnormal dysplastic response. It is obvious that recurrent epileptic seizures were more common in the group of patients who had no other cerebral vascular disease with de novo cAVMs. Epileptic seizures may be an initial clinical manifestation in unruptured cAVM and could also be a consequence of a complication. Additionally, the recurrent epileptic seizures might be the inciting event in the angiogenesis pathway of the de novo cAVMs by upregulating VEGF expression.

Conclusion

cAVMs are a dynamic disease which can grow postnatally. Recurrent epileptic seizures may be a possible trigger for de novo cAVMs by upregulating the VEGF expression. The effect of the epileptic seizures on the angiogenesis of cAVMs needs to be further studied.

Acknowledgments This study was supported by a “National science and technology Support Plan” (No.2011BAI08B08, Principle investigator: Professor Shuo Wang) grant from the Ministry of Health of China

Conflict of interest The authors declare that they have no conflict of interest.

References

- Abdulrauf SI, Malik GM, Awad IA (1999) Spontaneous angiographic obliteration of cerebral arteriovenous malformations. *Neurosurgery* 44(280–287):287–288
- Akimoto H, Komatsu K, Kubota Y (2003) Symptomatic de novo arteriovenous malformation appearing 17 years after the resection of two other arteriovenous malformations in childhood: case report. *Neurosurgery* 52(228–231):231–232
- Alvarez H, Perry V, Solle M, Castillo M (2012) De novo cerebral arteriovenous malformation in a child with previous cavernous malformation and developmental venous anomaly. *J Neurosurg Pediatr* 9:327–330
- Bai Y, He C, Zhang H, Ling F (2012) De novo multiple dural arteriovenous fistulas and arteriovenous malformation after embolization of cerebral arteriovenous fistula: case report. *Childs Nerv Syst* 28:1981–1983
- Bendok BR, Getch CC, Ali MJ, Parish T, Batjer HH (2002) Spontaneous thrombosis of a residual arteriovenous malformation in eloquent cortex after surgery: case report. *Neurosurgery* 50(1142–1145):1145–1146
- Bulsara KR, Alexander MJ, Villavicencio AT, Graffagnino C (2002) De novo cerebral arteriovenous malformation: case report. *Neurosurgery* 50(1137–1140):1140–1141
- Choi JH, Mohr JP (2005) Brain arteriovenous malformations in adults. *Lancet Neurol* 4:299–308
- Desal HA, Lee SK, Kim BS, Raoul S, Tymianski M, Terbrugge KG (2005) Multiple de novo vascular malformations in relation to diffuse venous occlusive disease: a case report. *Neuroradiology* 47:38–42
- Fierstra J, Conklin J, Krings T, Slessarev M, Han JS, Fisher JA, Terbrugge K, Wallace MC, Tymianski M, Mikulis DJ (2011) Impaired peri-nidal cerebrovascular reserve in seizure patients with brain arteriovenous malformations. *Brain* 134:100–109
- Friedman JA, Pollock BE, Nichols DA (2000) Development of a cerebral arteriovenous malformation documented in an adult by serial angiography. Case report. *J Neurosurg* 93:1058–1061
- Gonzalez LF, Bristol RE, Porter RW, Spetzler RF (2005) De novo presentation of an arteriovenous malformation. Case report and review of the literature. *J Neurosurg* 102:726–729
- Hashimoto T, Lawton MT, Wen G, Yang GY, Chaly TJ, Stewart CL, Dressman HK, Barbaro NM, Marchuk DA, Young WL (2004) Gene microarray analysis of human brain arteriovenous malformations. *Neurosurgery* 54(410–423):423–425
- Kim H, Su H, Weinsheimer S, Pawlikowska L, Young WL (2011) Brain arteriovenous malformation pathogenesis: a response-to-injury paradigm. *Acta Neurochir Suppl* 111:83–92
- Mahajan A, Manchandia TC, Gould G, Bulsara KR (2010) De novo arteriovenous malformations: case report and review of the literature. *Neurosurg Rev* 33:115–119
- Mast H, Koennecke HC, Meisel J, Osipov A, Hartmann A, Lasjaunias P, Pile-Spellman J, Hacein-Bey L, Young WL, Mohr JP (1998) Therapy of cerebral arteriovenous malformations. *Nervenarzt* 69:287–295
- Mathon B, Blauwblomme T, Bolle S, Dufour C, Nagarra O, Brunelle F, Puget S (2013) De novo arteriovenous malformation after brain radiotherapy for medulloblastoma in a child. *Neurology* 81:398–399
- Mendelow AD, Erfurth A, Grossart K, Macpherson P (1987) Do cerebral arteriovenous malformations increase in size? *J Neurol Neurosurg Psychiatry* 50:980–987
- Morioka T, Nishio S, Hikita T, Chung LH, Soejima T (1988) Marked growth of an angiographically occult arteriovenous malformation: case report. *Neurosurgery* 23:101–103
- Mullan S, Mojtahedi S, Johnson DL, Macdonald RL (1996) Embryological basis of some aspects of cerebral vascular fistulas and malformations. *J Neurosurg* 85:1–8
- Murphy PA, Lu G, Shiah S, Bollen AW, Wang RA (2009) Endothelial Notch signaling is upregulated in human brain arteriovenous malformations and a mouse model of the disease. *Lab Invest* 89:971–982
- Nikitidou L, Kanter-Schlifke I, Dhondt J, Carmeliet P, Lambrechts D, Kokaia M (2012) VEGF receptor-2 (Flk-1) overexpression in mice counteracts focal epileptic seizures. *PLoS One* 7:e40535
- Nilsson I, Rolny C, Wu Y, Pytowski B, Hicklin D, Alitalo K, Claesson-Welsh L, Wennstrom S (2004) Vascular endothelial growth factor receptor-3 in hypoxia-induced vascular development. *FASEB J* 18:1507–1515
- O’Shaughnessy BA, DiPatri AJ, Parkinson RJ, Batjer HH (2005) Development of a de novo cerebral arteriovenous malformation in a child with sickle cell disease and moyamoya arteriopathy. Case report. *J Neurosurg* 102:238–243
- Ozsarac M, Aksay E, Kiyani S, Unek O, Gulec FF (2012) De novo cerebral arteriovenous malformation: Pink Floyd’s song “Brick in the Wall” as a warning sign. *J Emerg Med* 43:e17–e20
- Schmit BP, Burrows PE, Kuban K, Goumnerova L, Scott RM (1996) Acquired cerebral arteriovenous malformation in a child with moyamoya disease. Case report. *J Neurosurg* 84:677–680
- Shweiki D, Itin A, Soffer D, Keshet E (1992) Vascular endothelial growth factor induced by hypoxia may mediate hypoxia-initiated angiogenesis. *Nature* 359:843–845

27. Stevens J, Leach JL, Abruzzo T, Jones BV (2009) De novo cerebral arteriovenous malformation: case report and literature review. *AJNR Am J Neuroradiol* 30:111–112
28. van Beijnum J, van der Worp HB, Buis DR, Al-Shahi SR, Kappelle LJ, Rinkel GJ, van der Sprenkel JW, Vandertop WP, Algra A, Klijn CJ (2011) Treatment of brain arteriovenous malformations: a systematic review and meta-analysis. *JAMA* 306:2011–2019
29. Walker EJ, Su H, Shen F, Choi EJ, Oh SP, Chen G, Lawton MT, Kim H, Chen Y, Chen W, Young WL (2011) Arteriovenous malformation in the adult mouse brain resembling the human disease. *Ann Neurol* 69:954–962