

Case Report

Reduced Smoke-like Echo and Resolved Thrombus in the Left Atrium with Rivaroxaban Therapy in an Acute Cardioembolic Stroke Patient

Shin Saito, MD, PhD,* Hirofumi Tomita, MD, PhD,† Yoshihiro Kimura, MD,†
 Hiroshi Shiroto, MD,* Joji Hagii, MD,* Norifumi Metoki, MD, PhD,*
 Hiroyasu Hitomi, MD,* Takaatsu Kamada, MD,* Tomohiro Osanai, MD, PhD,††
 Ken Okumura, MD, PhD,†† and Minoru Yasujima, MD, PhD*

We report a case of a nonvalvular atrial fibrillation (NVAF) patient with acute cardioembolic stroke in whom rivaroxaban, an oral direct factor Xa inhibitor, reduced a smoke-like echo in the left atrium and resolved a thrombus in the left atrial appendage. A 71-year-old man was admitted because of the sudden onset of right hemiplegia and aphasia and was diagnosed with acute cardioembolic stroke associated with NVAF. The patient had not been treated with warfarin before admission, and rivaroxaban therapy (15 mg once daily) was initiated. Transesophageal echocardiography was performed on day 8 and a mobile thrombus was found in the left atrial appendage, accompanied by a remarkable smoke-like echo in the left atrium. Notably, the thrombus was resolved and the smoke-like echo was reduced on day 40. No recurrent ischemic stroke occurred. We describe favorable effects of rivaroxaban on the reduction of a smoke-like echo and on the resolution of a thrombus in the left atrium in an NVAF patient with acute cardioembolic stroke. **Key Words:** Rivaroxaban—nonvalvular atrial fibrillation—reduction of a smoke-like echo—resolution of a thrombus.

© 2014 by National Stroke Association

Introduction

Warfarin therapy has been shown to be effective in reducing the size of left atrial thrombus.¹ Although novel

oral anticoagulants (NOACs) have been widely used for prevention of ischemic stroke in patients with nonvalvular atrial fibrillation (NVAF),^{2,3} the beneficial effect of NOACs on the resolution of left atrial thrombus still remains undetermined. Here, we report that rivaroxaban, an oral direct factor Xa inhibitor, reduced a smoke-like echo in the left atrium and resolved a thrombus of the left atrial appendage in an NVAF patient with acute cardioembolic stroke.

Case Report

A 71-year-old Japanese man with NVAF and multiple risk factors including hypertension, type 2 diabetes mellitus, dyslipidemia, and arteriosclerosis obliterans was transferred to our Stroke Center because of the sudden onset of right hemiplegia and aphasia. His National

From the *Hirosaki Stroke and Rehabilitation Center, Hirosaki, Japan; †Department of Cardiology, Hirosaki University Graduate School of Medicine, Hirosaki, Japan; and ‡Hypertension and Stroke Medicine, Hirosaki University Graduate School of Medicine, Hirosaki, Japan.

Received December 4, 2013; revision received January 16, 2014; accepted January 16, 2014.

Drs Ken Okumura, Joji Hagii, and Norifumi Metoki received Speakers' Bureau/Honorarium from Bayer Ltd.

Address correspondence to Shin Saito, MD, PhD, Hirosaki Stroke and Rehabilitation Center, 1-2-1, Ougi-machi, Hirosaki 036-8104, Japan. E-mail: shinpompom@gmail.com.

1052-3057/\$ - see front matter

© 2014 by National Stroke Association

<http://dx.doi.org/10.1016/j.jstrokecerebrovasdis.2014.01.014>

Institutes of Health Stroke Scale score was 12 at admission, and the plasma levels of the thrombin–antithrombin (TAT) complex and D-dimer were markedly increased to 30.0 ng/mL (normal range: 0–3.0 ng/mL) and 31.4 μ g/mL (normal range: 0–5 μ g/mL), respectively. Immediate axial diffusion-weighted magnetic resonance imaging and magnetic resonance angiography findings showed hyperintense signal in the left temporal cerebral cortex with chronic occlusion of the left internal carotid artery (ICA) (Fig 1, A,B). The left middle cerebral artery through the cerebral arterial circle of Willis had no major stenotic lesion. The patient was diagnosed with most likely acute cardioembolic stroke associated with NVAF, although artery-to-artery embolism derived from the left ICA lesion might need to be excluded.

The patient had not been treated with warfarin before admission, but with aspirin 100 mg once daily for atherothrombosis such as arteriosclerosis obliterans and the left ICA occlusion. Rivaroxaban therapy (15 mg once daily) was initiated to prevent the recurrence of stroke and aspirin was continued for atherothrombosis treatment. Transesophageal echocardiography was performed on day 8 and a mobile thrombus (13.3 \times 8.7 mm) was found in the left atrial appendage with low blood flow velocity (11.8–21.2 cm/second), accompanied by a remarkable smoke-like echo in the left atrium (Fig 1, C). Most notably, the thrombus was resolved and the smoke-like echo was reduced on transesophageal echocardiography performed on day 40 (Fig 1, D), whereas the blood flow velocity in the left atrial appendage remained still low (13.1–16.8 cm/second). No recurrent ischemic stroke occurred. After sufficient rehabilitation program, the patient was discharged from our Stroke Center on day 87 with a modified Rankin scale score of 3.

Discussion

In the present case report, we showed a favorable effect of rivaroxaban therapy on the resolution of left atrial thrombus in an NVAF patient with acute cardioembolic stroke. Rivaroxaban treatment also exhibited a reduction of smoke-like echo in the left atrium, despite no change in the blood flow velocity in the left atrial appendage. These provide important clinical implications of NOACs aimed at resolving thrombus and preventing thrombus formation in the left atrium.

There have been few case reports showing beneficial effects of NOACs on the reduction of size and the resolution of thrombus in the left atrium.^{4–6} Furthermore, the inhibitory effect of rivaroxaban on a smoke-like echo has not been reported previously. It is believed that a smoke-like echo is because of stasis of blood and red blood cell aggregation as a result of sluggish blood flow. Also, higher plasma TAT values have been reported to be associated with the presence of a smoke-like echo.⁷ Consistent with this, we observed higher plasma levels of TAT and D-dimer accompanied by the smoke-like echo before rivaroxaban treatment. Although lack of the data on the plasma levels of TAT and D-dimer after rivaroxaban treatment limits further consideration, anticoagulant activity of rivaroxaban is likely to improve the hypercoagulability.⁸ Therefore, rivaroxaban may exert its inhibitory effect on a smoke-like echo, at least in part, through the anticoagulant activity. Further mechanistic studies are required in this regard. Because the smoke-like echo is closely related to the formation of thrombus in the left atrium,⁹ our finding that the smoke-like echo in the left atrium was reduced after rivaroxaban treatment may contribute to the resolution of thrombus in the left atrium.

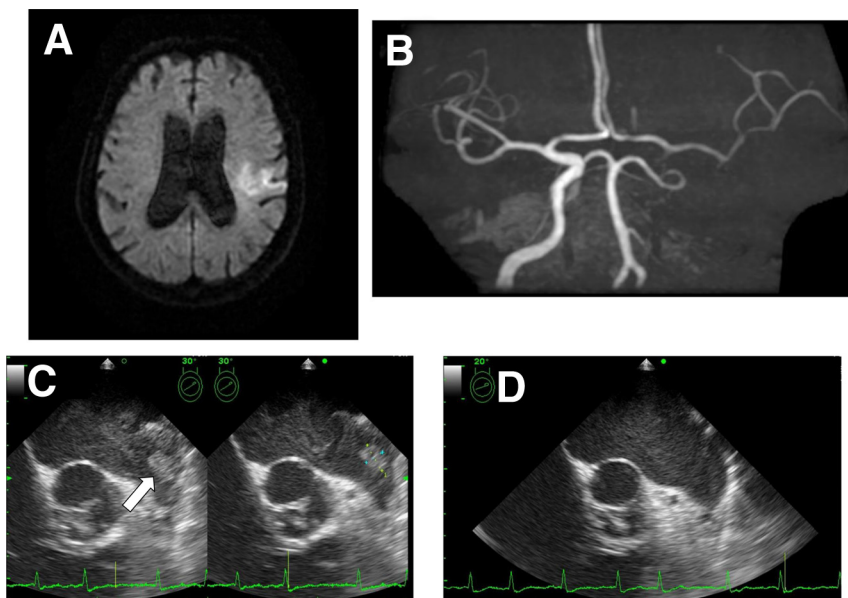


Figure 1. (A) Axial diffusion-weighted magnetic resonance image at admission showing hyperintense signal in the left temporal cerebral cortex. (B) Magnetic resonance angiography at admission showing chronic occlusion of the left internal carotid artery and the left middle cerebral artery through the cerebral arterial circle of Willis. (C) A mobile thrombus (arrow, 13.3 \times 8.7 mm) in the left atrial appendage and a remarkable smoke-like echo in the left atrium detected on TEE performed on day 8. (D) Disappeared thrombus and reduced smoke-like echo on TEE performed on day 40 after rivaroxaban therapy. Abbreviation: TEE, transesophageal echocardiography.

Rivaroxaban inhibits free factor Xa and prothrombinase activity, thereby effectively blocking thrombin generation in a concentration-dependent manner.^{8,10,11} It is commonly accepted that formation and resolution of thrombus are based on the dynamic balance between coagulation and fibrinolysis. The inhibitory effect of rivaroxaban on thrombin generation, therefore, shifts this balance toward fibrinolysis. Furthermore, the reduced thrombin generation forms a looser fibrin clot network that is more degradable by fibrinolytic enzymes.¹² These may partly explain an effect of rivaroxaban on the resolution of thrombus in the left atrium.

The dose of rivaroxaban in the present case (15 mg once daily) is low compared with that in the global ROCKET AF (Rivaroxaban once daily oral direct factor Xa inhibition compared with vitamin K antagonist for prevention of stroke and embolism trial in atrial fibrillation) study (20 mg once daily), but is shown to be a standard dose in the Japanese-ROCKET AF study conducted in the Japanese population.¹³ Further a low dose of rivaroxaban (10 mg once daily) is approved for patients with renal dysfunction in Japan, and is also reported to be effective in the resolution of thrombus.⁶ More accumulating evidence regarding the effectiveness of low dose of rivaroxaban will be needed.

Conclusions

We report favorable effects of rivaroxaban on the reduction of a smoke-like echo and on the resolution of a thrombus in the left atrium, although the effect of concomitant use of aspirin with rivaroxaban on the reduction in the size of the thrombus cannot be completely excluded in the present case. Further clinical and case studies with rivaroxaban are unquestionably required to ascertain its favorable effect on the resolution of thrombus.

Acknowledgment: The authors (S.S., H.T., Y.K., H.S., H.H., T.K., T.O., and M.Y.) have no conflict of interest to disclose.

References

1. Yasaka M, Yamaguchi T, Miyashita T, et al. Regression of intracardiac thrombus after embolic stroke. *Stroke* 1990; 221:1540-1544.
2. Connolly SJ, Ezekowitz MD, Yusuf S, et al. Dabigatran versus warfarin in patients with atrial fibrillation. *N Engl J Med* 2009;361:1139-1151.
3. Patel MR, Mahaffey KW, Garg J, et al. Rivaroxaban versus warfarin in nonvalvular atrial fibrillation. *N Engl J Med* 2011;365:883-891.
4. Vidal A, Vanerio G. Dabigatran and left atrial appendage thrombus. *J Thromb Thrombolysis* 2012; 34:545-547.
5. Hammerstingl C, Pötzsch B, Nickenig G. Resolution of giant left atrial appendage thrombus with rivaroxaban. *Thromb Haemost* 2013;109:583-584.
6. Takasugi J, Yamagami H, Okata T, et al. Dissolution of the left atrial appendage thrombus with rivaroxaban therapy. *Cerebrovasc Dis* 2013;36:322-323.
7. Soncini M, Casazza F, Mattioli R, et al. Hypercoagulability and chronic atrial fibrillation: the role of markers of thrombin generation. *Minerva Med* 1997; 88:501-505.
8. Perzborn E, Roehrig S, Straub A, et al. Rivaroxaban: a new oral factor Xa inhibitor. *Arterioscler Thromb Vasc Biol* 2010;30:376-381.
9. Beppu S, Nimura Y, Sakakibara H, et al. Smoke-like echo in the left atrial cavity in mitral valve disease: its features and significance. *J Am Coll Cardiol* 1985; 6:744-749.
10. Furie B, Furie BC. Mechanisms of thrombus formation. *N Engl J Med* 2008;359:938-949.
11. Perzborn E, Strassburger J, Wilmen A, et al. In vitro and in vivo studies of the novel antithrombotic agent BAY 59-7939—an oral, direct Factor Xa inhibitor. *J Thromb Haemost* 2005;3:514-521.
12. Varin R, Mirshahi S, Mirshahi P, et al. Whole blood clots are more resistant to lysis than plasma clots—greater efficacy of rivaroxaban. *Thromb Res* 2013; 131:e100-e109.
13. Hori M, Matsumoto M, Tanahashi N, et al. Rivaroxaban vs. warfarin in Japanese patients with atrial fibrillation—the J-ROCKET AF study. *Circ J* 2012;76: 2104-2111.