

## CASE REPORT

# Electroconvulsive therapy for catatonia in juvenile neuropsychiatric lupus

T Leon, A Aguirre, C Pesce, P Sanhueza and P Toro

Section of Consultation-Liaison Psychiatry and Psychosomatic Medicine, Department of Psychiatry, Faculty of Medicine, Pontificia Universidad Católica de Chile, Chile

Neuropsychiatric manifestations are serious and frequent complications of systemic lupus erythematosus (SLE). Catatonia is a neuropsychiatric disorder characterized by motor disturbance (including waxy flexibility and catalepsy), stupor, excitement, negativism, mutism, echopraxia and echolalia. Catatonia associated with SLE has been only rarely reported, especially in children. Here we present a case of a 14-year-old patient encountered in consultation-liaison psychiatry who presented catatonia associated with SLE. Her catatonia was refractory to treatment with pulse methylprednisolone, intravenous cyclophosphamide and rituximab. The patient responded to a combined therapy of electroconvulsive therapy and benzodiazepines. The present case suggests that although rarely reported, catatonia seen in the background of SLE should be promptly identified and treated to reduce the morbidity. *Lupus* (2014) 23, 1066–1068.

**Key words:** Neuropsychiatric lupus; systemic lupus erythematosus; catatonia; ECT

### Introduction

Neuropsychiatric (NP) manifestations are serious and frequent complications of systemic lupus erythematosus (SLE).<sup>1</sup> The more prevalent of these include seizures, psychosis, mood disorders, headache, cognitive impairment and anxiety disorders.<sup>2</sup>

Catatonia is an NP disorder characterized by motor disturbance (including waxy flexibility and catalepsy), stupor, excitement, negativism, mutism, echopraxia and echolalia.<sup>3</sup> The most frequent non-psychiatric etiologies are neurological, toxic and metabolic.<sup>4</sup> Catatonia associated with SLE has been only rarely reported, especially in children.<sup>5</sup>

We present the case of a 14-year old female patient referred to consultation-liaison psychiatry who presented catatonia associated to SLE. The patient responded to a combined therapy of electroconvulsive therapy (ECT) and benzodiazepines.

### Case report

The patient is a 14-year-old Latin girl with a history of idiopathic thrombocytopenic purpura, diagnosed at 13 years after severe episodes of epistaxis and alopecia. At the time, the patient's blood tested positive for cardiolipin specific antibodies, Ro antibodies, anti-ribosomal protein P and LA antibodies. The patient was diagnosed with SLE and treated with prednisone and mycophenolate.

The patient was a good student with an appropriate development and social life. There was no prior personal or familial history of psychiatric illnesses.

Two years later, the patient was brought to the emergency room (ER) after a day of psychomotor agitation, visual and auditory hallucinations and involuntary movements. Her mental state in the ER was reported as lucid, alert and anxious, with echolalia and without any focal neurological signs. She was afebrile, tachycardiac and hypertensive. Initial tests indicated normal values for white cell count, reactive protein C, lupus antibody, cardiolipin antibodies complements C3 and C4 as well as for all other antibodies, except for anti-ribosomal protein P.

She was admitted to the pediatric ward with a diagnosis of delirium in the context of a

Correspondence to: P Toro, Section of Consultation-Liaison Psychiatry and Psychosomatic Medicine, Department of Psychiatry, Faculty of Medicine, Pontificia Universidad Católica de Chile, Marcoleta 381, dpto 21, Santiago, Chile.

Email: [ptoro@uc.cl](mailto:ptoro@uc.cl)

Received 2 February 2014; accepted 8 April 2014

neuropsychiatric SLE. She continued to present psychomotor agitation, incoherent language and intermittent connection to her surroundings. She had tachycardia as high as 200 beats/min and little response to antipsychotics.

She was initiated on methylprednisolone, 1 g/day, for three days with no effect. Next, she received cyclophosphamide and rituximab, also with little response.

The liaison psychiatric team arrived to find a patient in catatonic stupor, echolalia, echopraxia, rigidity, catalepsy and tachycardia. We made the diagnosis of catatonia and started with benzodiazepines (lorazepam) 2 mg/8 h. Due to lack of response, four days later, this dose was replaced by a continuous infusion of up to 20 mg/24 h. The patient's tachycardia diminished but her consciousness impairment remained.

Five days after the diagnosis, and given that there was no consistent or significant improvement of catatonia, the liaison psychiatric team made the decision to initiate ECT.

The patient received 11 bilateral ECT treatments, with energy set that started at 15% during the first session and reached 90% during the last session; charge delivered started at 76.1 mC and reached 457.2 mC, mean EEG seizure 27.4 seconds. The patient showed a rapid improvement from the first session (see Figure 1). Lorazepam was reduced progressively until suspension after the 10th session. At this point, the patient's Bush–Francis Catatonia Rating Scale score decreased from 44 immediately before ECT to 4 after ECT. She started to interact with her parents and the medical team; she also

started brushing her teeth and bathing, as well as walking unaided. Hallucinations and agitation disappeared but her eye contact remained a little unsteady until her release from the hospital.

She was released from the hospital in good condition, orientated and calm, without any psychiatric medications.

## Discussion

A recent review found only 22 cases of catatonia in NPSLE patients, eight of them under 18 years of age,<sup>6</sup> five of which were very similar to our patient in age and psychopathological characteristics.

With regard to the treatment of catatonia it is important to mention that catatonia is a medical emergency and it should be treated in conjunction with the etiological disease, in this case SLE. Some cases of SLE-associated catatonia do not respond to lorazepam<sup>7</sup> and, based on our study, we postulate that catatonic patients that are non-responsive to benzodiazepines must be treated with ECT.<sup>8,9</sup> In addition to the use of catatonia-specific interventions, the need to treat the inflammatory illness with steroids and cyclophosphamide has also been recommended in most of the described cases.<sup>10</sup>

## Conclusion

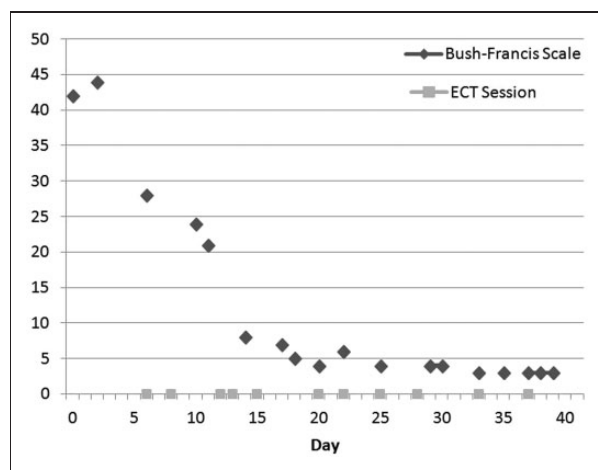
The present case emphasizes that, although rarely reported, catatonia seen in the background of SLE should be promptly identified and treated to reduce patient morbidity. Early identification and treatment such as benzodiazepines and ECT has the potential to avoid poor outcomes and fatalities.<sup>9</sup> In this case, the liaison psychiatry team was a key factor in establishing a fast diagnosis and appropriate treatment of the patient, resulting in an optimum recovery.

## Funding

This research received no specific grant from any funding agency in the public, commercial, or not-for-profit sectors.

## Conflict of interest statement

The authors have no conflicts of interest to declare.



**Figure 1** Clinical course of catatonia and electro convulsive therapy sessions.

## References

- 1 Hanly JG, McCurdy G, Fougere L, *et al.* Neuropsychiatric events in systemic lupus erythematosus: Attribution and clinical significance. *J Rheumatol* 2004; 31: 2156–2162.
- 2 Brey RL, Holliday SL, Saklad AR, *et al.* Neuropsychiatric syndromes in lupus: Prevalence using standardized definitions. *Neurology* 2002; 58: 1214–1220.
- 3 Taylor MA, Fink M. Catatonia in psychiatric classification: A home of its own. *Am J Psychiatry* 2003; 160: 1233–1241.
- 4 Weder ND, Muralee S, Penland H, *et al.* Catatonia: A review. *Ann Clin Psychiatry* 2008; 20: 97–107.
- 5 Muscal E, Brey RL. Neurologic manifestations of systemic lupus erythematosus in children and adults. *Neurol Clin* 2010; 28: 61–73.
- 6 Grover S, Parakh P, Sharma A, *et al.* Catatonia in systemic lupus erythematosus: A case report and review of literature. *Lupus* 2013; 22: 634–638.
- 7 Wang HY, Huang TL. Benzodiazepines in catatonia associated with systemic lupus erythematosus. *Psychiatry Clin Neurosci* 2006; 60: 768–770.
- 8 Mon T, L'Ecuyer S, Farber NB, *et al.* The use of electroconvulsive therapy in a patient with juvenile systemic lupus erythematosus and catatonia. *Lupus* 2012; 21: 1575–1581.
- 9 Nazarian RS, Liebman LS, Kellner CH. Electroconvulsive therapy (ECT) for catatonia: Delay may be risky. *Lupus* 2013; 22: 336.
- 10 Fricchione GL, Kaufman LD, Gruber BL, *et al.* Electroconvulsive therapy and cyclophosphamide in combination for severe neuropsychiatric lupus with catatonia. *Am J Med* 1990; 88: 442–443.