



**Dr. Bivens:** The medical record lists 15 visits for headaches over the past 9 years, with diagnoses of sinusitis. Some of those headaches were associated with nausea and photophobia, others with occasional numbness of her left hand. She has also had visits for neck stiffness and neck strain. The patient and her husband are both physical therapists, and the husband treated some of her neck pains and headaches with massages, spinal manipulation, electrical stimulation, and therapeutic ultrasound. Of note, nearly a decade prior she had had an extensive work-up for headaches associated with blurry vision, and with numbness and paresthesias in her hands and feet, which had included two essentially normal brain magnetic resonance imaging (MRI) studies.

**Dr. John Jesus:** Did her neurological symptoms persist in the ED?

**Dr. Bivens:** Although she continued to complain of a mild frontal headache with pain behind her left eye and in her left neck, she denied any focal weakness, vision changes, dysarthria, dysphagia, vertigo, tinnitus, or mental foginess. She did report a new symptom had developed while in the ED, which was numbness on the medial aspect of her right leg.

**Dr. Madsen:** What was her physical examination?

**Dr. Bivens:** She was cooperative, alert, and articulate. Her neck was supple, lungs clear, heart sounds normal, and she had strong peripheral pulses. Cranial nerves II through XII were intact. Her pupils were equal, round and reactive. Fundoscopy was attempted without a clear view of the optic disk. She had no pronator drift, no cerebellar dysmetria, no tremors, no motor weakness, no sensory deficits (despite the report of medial thigh numbness, she did have sensation in her medial thigh), +2 reflexes at the knees, and a normal gait. She had no focal weakness, and in particular no right-hand clumsiness or problems writing out sentences and numbers.

**Dr. Jesus:** What was your differential diagnosis?

**Dr. Bivens:** This was a 36-year-old woman with a headache, a reassuring neurological examination, and a history of chronic headaches with unremarkable work-ups—including headaches associated with neurological symptoms such as hand numbness and paresthesias. However, the transient hand *clumsiness* and repetitive number writing at today's visit was concerning. The clumsy hand/repetitive number-writing was a new accompanying symptom for her and suggested a stroke—or more precisely, because all neurological deficits had resolved, a transient ischemic attack (TIA). A severe persistent headache associated with neurological symptoms also suggested a central venous sinus thrombosis (CVST) or a subarachnoid hemorrhage. The neck pain, treated with vigorous massage and spinal manipulations, raised the possibility of cervical artery dissection showering

clots as the source of a TIA. Complex migraine, cluster headache, or musculoskeletal neck pain were also possibilities, but could only be entertained after ruling out more concerning etiologies.

**Dr. Madsen:** What was your plan?

**Dr. Bivens:** The plan was to perform a non-contrast head computed tomography (CT) scan, followed by CT angiography (CTA) imaging to evaluate for CVST, stroke, or dissection, and to consult our colleagues from Neurology. Given the possibility of subarachnoid hemorrhage, our plan recognized we would not be completely reassured by negative imaging; so if all imaging was unremarkable, we would go on to perform a lumbar puncture to evaluate for xanthochromia.

**Dr. Carrie Tibbles:** We have the chief of Emergency Radiology with us. Dr. Marc Camacho, could you please tell us what the imaging showed?

**Dr. Marc Camacho:** The non-contrast head CT scan was unremarkable. A contrast-enhanced head CT scan was performed next that demonstrated dissection and subtotal occlusion of the left internal carotid artery (Figures 1, 2).

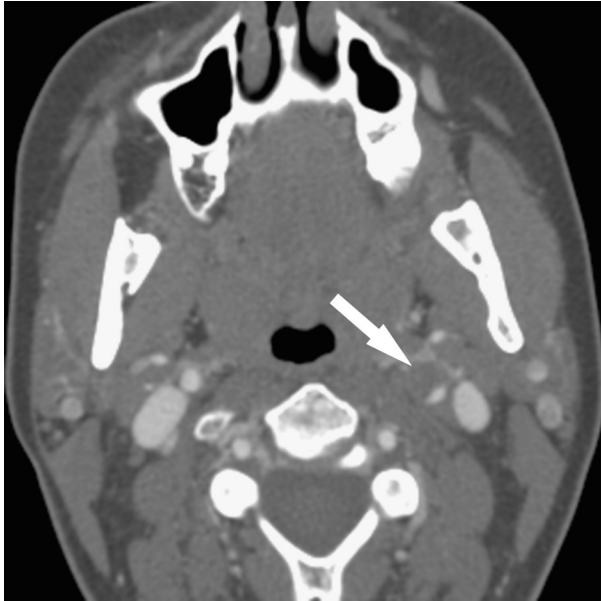
**Dr. Bivens:** I discussed these results with our colleague from Neurology, Dr. Aimee Boegle.

**Dr. Aimee Boegle:** The patient remained asymptomatic except for a mild, resolving frontal headache. We discussed the diagnosis with her, started her on a heparin drip, and admitted her to the Neurology step-down unit for frequent neurological examinations and continued anticoagulation.

**Dr. Jesus:** Please tell us about her hospital course.

**Dr. Boegle:** By arrival to the step-down floor, the patient was therapeutic on a heparin drip. She spent an uneventful night. At 6:30 a.m. she was noted to be well and speaking with family on the telephone. At around 8:00 a.m., she was found to have a dense right-sided hemiparesis with right facial droop, left eye deviation, up-going right toe, and failure to respond to threat on the right. She also had a severe aphasia and could not speak at all. She could occasionally follow one-step commands. A stat MRI/magnetic resonance angiography (MRA) study of the head and neck was performed.

**Dr. Camacho:** The MRI/MRA showed an acute left middle cerebral artery (MCA) infarct, along with occlusion of the left internal carotid, from the cervical region to the petrous and cavernous regions. No flow could be seen in the left MCA. There was no evidence of hemorrhage or severe edema (Figures 3, 4). This imaging, along with a CTA scan of the head and neck some 8 h later, revealed additional dissections involving not only the left internal carotid, but also the right internal carotid and also segments of the left and right vertebral arteries. Only the left internal carotid artery had thrombus in the lumen.

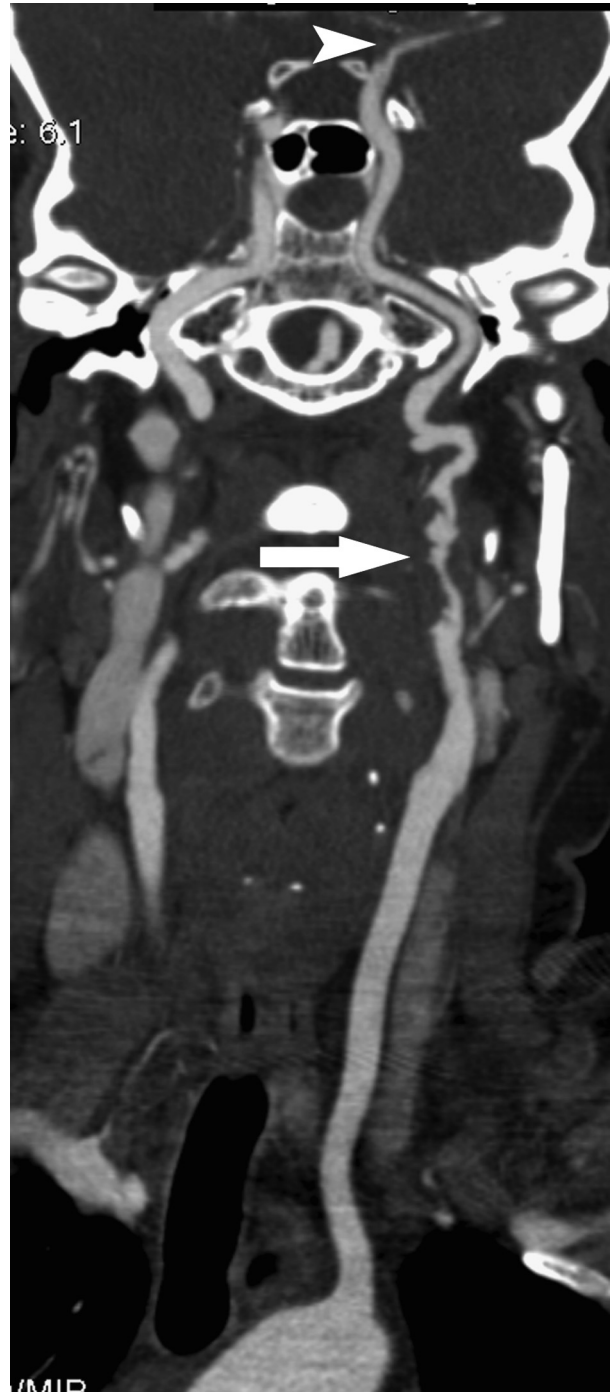


**Figure 1.** Axial image from computed tomography angiogram demonstrates dissection and subtotal occlusion of the left internal carotid artery (white arrow) just proximal to the foramen lacerum.

**Dr. Madsen:** So she had dissected all of her major cervical arteries. Very unusual! How did you manage her ischemic stroke?

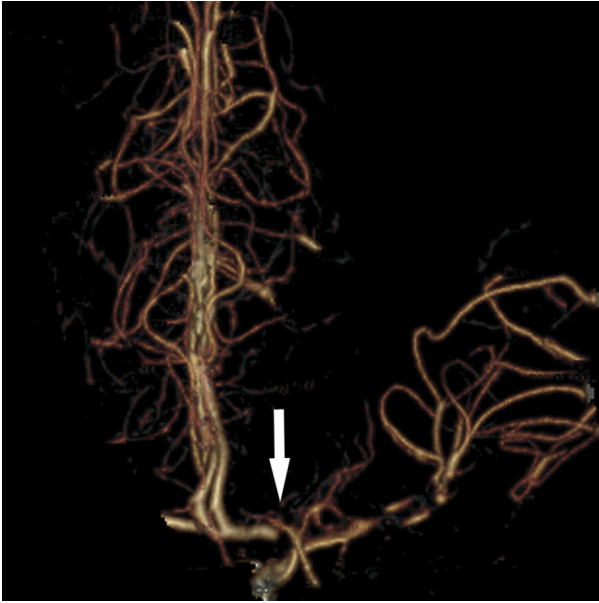
**Dr. Boegle:** Given that she was therapeutic on heparin, she was not felt to be a candidate for intravenous thrombolytics. The interventional Neurology team felt that the dissection was in too tortuous an area of the petrous bone for endovascular stenting to be feasible. Intra-arterial thrombolysis was also considered, but again felt to be of minimal benefit given the extent of infarcted tissue. Neurosurgery was consulted to be ready for potential hemicraniectomy given the high risk of developing a malignant MCA syndrome, with severe cerebral edema. Patients at high risk for this entity include young females with a first-ever large stroke, especially those involving a carotid occlusion (1). The patient was started on pressor agents to keep her blood pressure artificially elevated in a desperate attempt to perfuse the ischemic penumbra, and hypertonic saline to prevent edema formation. Repeat CT scans did not reveal significant edema, but did show small areas of hemorrhagic transformation; given the minimal amount of bleeding, anticoagulation was continued.

**Dr. Madsen:** This was a difficult case. It would have been relatively easy to miss this diagnosis entirely—either by getting no neuroimaging whatsoever in this asymptomatic patient in a busy ED, or to have been comforted by a non-contrast head CT scan, which would have been falsely reassuring. Instead, the correct imaging was obtained, a difficult diagnosis was made, and treatment was initiated. And yet we still have had an unfavorable outcome.



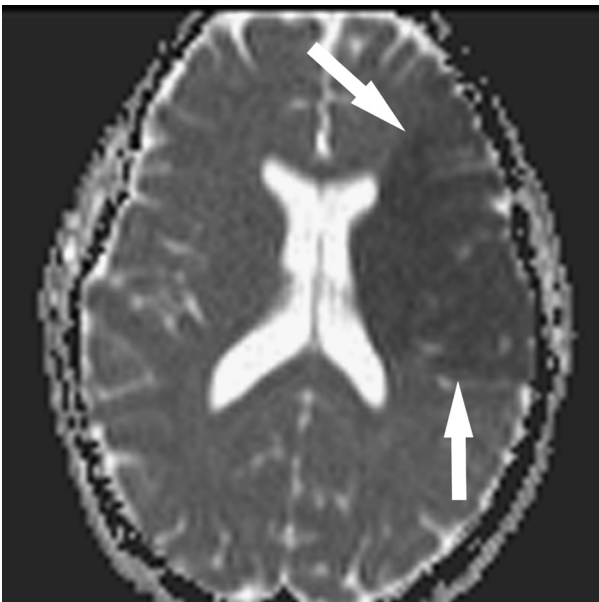
**Figure 2.** Curved planar reformatted image demonstrates a nearly occlusive circumferential thrombus at the proximal left internal carotid artery (ICA, white arrow) with embolus noted at the left ICA terminus and proximal left middle cerebral artery (MCA, arrowhead).

**Dr. Boegle:** The good news is that she has made a remarkable recovery in the year since we saw this patient together. She is young, and she and her husband are both physical therapists, so she has had the tools she needs for excellent post-stroke rehabilitation. She made



**Figure 3.** Three-dimensional volume-rendered image of the circle of Willis demonstrates the filling defect of the left middle cerebral artery (white arrow).

progress during her 10-day hospitalization, but at discharge could still only say “ma, ma, ma” and hum songs, and still had severe right-sided weakness. Today she has almost no motor deficits. Her speech is nearly back to baseline—some occasional hesitation in bringing out a word—and she in fact just got her driver’s license



**Figure 4.** Apparent diffusion coefficient (ADC) map from subsequent magnetic resonance imaging study demonstrates the large territory of ischemia (between white arrows) in the left middle cerebral artery distribution.

back and returned to work. Perhaps the aggressive supportive care she received in-hospital made a difference. More broadly, the case is a reminder of how important post-stroke rehabilitation care can be.

**Dr. Jesus:** What are the current treatment strategies for cervical artery dissections?

**Dr. Boegle:** Management of spontaneous cervical artery dissections is controversial, but is aimed at trying to prevent clot in the artery from either propagating or embolizing and causing downstream ischemic events. The most common regimen used towards this is an intravenous heparin infusion (typically 15 units/kg/h without a preceding bolus), followed by 3–6 months of anticoagulation with warfarin (2,3). One study used ultrasound to monitor for microemboli in patients with cervical dissection, and found that within 24 h of starting heparin, all evidence of microemboli disappeared in 70% of patients (4).

However, risks of anticoagulation do include the possibility of both intracranial hemorrhage and also of large clot burden breaking free and embolizing, which may have been the etiology here. For this reason, and also for cost and convenience issues, some neurologists recommend oral anti-platelet medications such as aspirin or, less commonly, clopidogrel. A handful of systematic reviews, including a Cochrane Review in 2010, have not shown evidence of superiority for one approach over the other, either in risk of death or disability or in rates of intracranial hemorrhage (5–9). The Cervical Artery Dissection in Stroke Study (CADISS) trial in Great Britain is randomizing patients to anti-coagulation or anti-platelet therapies, so we can hope for better quality data in future (10,11).

**Dr. Madsen:** Do we know why our patient developed these cervical dissections in the first place?

**Dr. Bivens:** A minority of cervical artery dissections occur in the context of a connective tissue disorder such as Ehlers-Danlos IV or polycystic kidney disease (12,13). Marfan syndrome is often cited as a risk factor, but no cervical artery dissections were found in a large series of Marfan patients (14). Our patient had no family history of connective tissue disorders, but given the multiple dissections, has been referred to a neurogeneticist. The patient did have a long history of headaches, and it is of note that a history of migraines is itself a strong independent risk factor for cervical artery dissection (15,16).

It is worth noting that dissections have been associated with surprisingly minor precipitating events. There have been “bottoms up” dissections from hyperextending the head to toss back a toast, “beauty parlor strokes” caused by salon sink shampoo treatments, and dissections after riding on a roller coaster or on a turbulent airplane flight (17–20). Dissections have been reported in a healthy fire fighter after 15 min of looking overhead, in ceiling painters, in scuba divers after rapid ascents, and in



office workers after phone conversations cradling the receiver between chin and shoulder (13,21–24).

A major source of dissection may well be chiropractic spinal manipulation, and it has been estimated that one in 20,000 spinal manipulations causes a stroke (25,26). However, it has also been noted that the pre-existing neck pain that brings a patient to a chiropractor may well represent a pre-existing dissection, making causality hard to assign. Our patient had undergone spinal manipulations by her husband, a physical therapist, but again, whether that provoked a dissection or simply represented a response to the pain of a dissection, remains unknown.

**Dr. Madsen:** To summarize, cervical artery dissections are an important cause of stroke in the young. Sometimes the patient will have concerning neurological findings, as in this case, but often there will be only a report of neck pain or headache. Vascular imaging is key to making the diagnosis.

## REFERENCES

- Jaramillo A, Góngora-Rivera F, Labreuche J, et al. Predictors for malignant middle cerebral artery infarctions: a postmortem analysis. *Neurology* 2006;66:815–20.
- Fusco M, Harrigan M. Cerebrovascular dissections—a review part I: spontaneous dissections. *Neurosurgery* 2011;68:242–57.
- Brott T, Halperin J, Abarra S, et al., American College of Cardiology Foundation/American Heart Association Task Force on Practice Guidelines; American Stroke Association; American Association of Neuroscience Nurses; American Association of Neurological Surgeons; American College of Radiology; American Society of Neuro-radiology; Congress of Neurological Surgeons; Society of Atherosclerosis Imaging and Prevention; Society for Cardiovascular Angiography and Interventions; Society of Interventional Radiology; Society of NeuroInterventional Surgery; Society for Vascular Medicine; Society for Vascular Surgery; American Academy of Neurology and Society of Cardiovascular Computed Tomography. 2011 ASA/ACCF/AHA/AANN/AANS/ACR/ASNR/CNS/SAIP/SCAI/SIR/SNIS/SVM/SVS guideline on the management of patients with extracranial carotid and vertebral artery disease. *Stroke* 2011;42:e464–540.
- Molina CA, Alvarez-Sabín J, Schonewille W, et al. Cerebral micro-embolism in acute spontaneous internal carotid artery dissection. *Neurology* 2000;55:1738–40.
- Paciaroni M, Agnelli G, Micheli S, Caso V. Efficacy and safety of anticoagulant treatment in acute cardioembolic stroke: a meta-analysis of randomized controlled trials. *Stroke* 2007;38:423–30.
- Lyrer P, Engelter S. Antithrombotic drugs for carotid artery dissection. *Stroke* 2004;35:613–4.
- Georgiadis D, Arnold M, von Buedingen H, et al. Aspirin vs anticoagulation in carotid artery dissection: a study of 298 patients. *Neurology* 2009;72:1810–5.
- Menon R, Kerry S, Norris JW, Markus H. Treatment of cervical artery dissection: a systematic review and meta-analysis. *J Neurol Neurosurg Psychiatry* 2008;79:1122–7.
- Lyrer P, Engelter S. Antithrombotic drugs for carotid artery dissection. *Cochrane Database Syst Rev* 2010;(10):CD000255.
- Cervical Artery Dissection in Stroke Study Trial Investigators. Anti-platelet therapy vs. anticoagulation in cervical artery dissection: rationale and design of the Cervical Artery Dissection in Stroke Study (CADISS). *Int J Stroke* 2007;2:292–6.
- St George's University of London. CADISS news. Available at: <http://www.sgul.ac.uk/research/ongoing-projects/cadiss>.
- Grond-Ginsbach C, Debette S. The association of connective tissue disorders with cervical artery dissections. *Curr Mol Med* 2009;9:210–4.
- Schievink WI. Spontaneous dissection of the carotid and vertebral arteries. *N Engl J Med* 2001;344:898–906.
- Debette S, Metso T, Pezzini A, et al. CADISP-genetics: an International project searching for genetic risk factors of cervical artery dissections. *Int J Stroke* 2009;4:224–30.
- Arto V, Metso T, Metso A, et al. Migraine with aura is a risk factor for cervical artery dissection: a case-control study. *Cerebrovasc Dis* 2010;30:36–40.
- Rubinstein SM, Peerdeman SM, van Tulder MW, et al. A systematic review of the risk factors for cervical artery dissection. *Stroke* 2005;36:1575–80.
- Trosch R, Hasbani M, Brass L. 'Bottoms up' dissection. *N Engl J Med* 1989;320:1564–5.
- Stratigos J. Beauty Parlor Stroke Syndrome: report of 5 Cases. *JAMA* 1993;269:2085–6.
- Blacker D, Wijdicks E. A ripping roller coaster ride. *Neurology* 2003;61:1255.
- Quinn C, Cooke J, O'Connor M, Lyons D. Cervical artery dissection following a turbulent flight. *Aviat Space Environ Med* 2011;82:995–7.
- Lloyd S. Carotid artery dissection following minimal postural trauma in a firefighter. *Occup Med (Lond)* 2004;54:430–1.
- Gibbs J. Internal carotid artery dissection in stroke from scuba diving: a case report. *Undersea Hyperb Med* 2002;29:167–71.
- Bartsch T, Palaschewski M, Thilo B, et al. Internal carotid artery dissection and stroke after SCUBA diving: a case report and review of the literature. *J Neurol* 2009;256:1916–9.
- Mourad J, Girerd X, Safar M. Carotid artery dissection after a prolonged telephone call. *N Engl J Med* 1997;336:518.
- Hufnagel A, Hammers A, Schönle P, et al. Stroke following chiropractic manipulation of the cervical spine. *J Neurol* 1999;246:683–8.
- Vickers A, Zollman C. The manipulative therapies: osteopathy and chiropractic. *BMJ* 1999;319:1176–9.