

explain why ICI and ICF showed contrasting behaviors in our CD patients; moreover, ICF mechanisms are still not fully understood.¹⁵

Because of the small number of patients, these results should be taken cautiously, but they demonstrate that changes occur within the motor cortex excitability when sensory tricks are being performed. One could raise the question of whether this is a primary cortical mechanism or just an epiphenomenon of dystonic muscle activity fluctuations, either spontaneous or induced by botulinum therapy. The inhibitory effect of the sensory tricks on the overactivity of the motor cortex was already supported by an H₂¹⁵O positron emission tomography study, reporting decreased activity of the supplementary motor area and primary motor cortex contralateral to the head turn, as well as increased activity of the ipsilateral parietal cortex.¹⁶ These new insights on the exteroceptive inhibition of dystonic spasms could have positive therapeutic outcomes in lower cranial as well as cervical dystonia.^{17,18} ■

References

1. Hallett M. Is dystonia a sensory disorder? *Ann Neurol* 1995;38:139-140.
2. Ridding MC, Sheean G, Rothwell JC, Inzelberg R, Kujirai T. Changes in the balance between motor cortical excitation and inhibition in focal, task specific dystonia. *J Neurol Neurosurg Psychiatry* 1995;59:493-498.
3. Rona S, Berardelli A, Vacca L, Inghilleri M, Manfredi M. Alterations of motor cortical inhibition in patients with dystonia. *Mov Disord* 1998;13:118-124.
4. Bütefisch CM, Boroojerdi B, Chen R, Battaglia F, Hallett M. Task-dependent intracortical inhibition is impaired in focal hand dystonia. *Mov Disord*. 2005;20:545-551.
5. Beck S, Richardson SP, Shamim EA, Dang N, Schubert M, Hallett M. Short intracortical and surround inhibition are selectively reduced during movement initiation in focal hand dystonia. *J Neurosci* 2008;28:10363-10369.
6. Kanovsky P, Bares M, Streitová H, Klajblová H, Daniel P, Rektor I. Abnormalities of cortical excitability and cortical inhibition in cervical dystonia: evidence from somatosensory evoked potentials and paired transcranial magnetic stimulation recordings. *J Neurol* 2003;250:42-50.
7. Consky ES, Basinki A, Belle L, Ranawaya R, Lang AE. The Toronto Western Spasmodic Torticollis Rating Scale (TWSTRS): assessment of validity and inter-rater reliability. *Neurology* 1990;40(suppl 1):445.
8. Wissel J, Müller J, Ebersbach G, Poewe W. Trick maneuvers in cervical dystonia: investigation of movement- and touch-related changes in polymyographic activity. *Mov Disord* 1999;14:994-999.
9. Gilio F, Currà A, Lorenzano C, Modugno N, Manfredi M, Berardelli A. Effects of botulinum toxin type A on intracortical inhibition in patients with dystonia. *Ann Neurol* 2000;48:20-26.
10. Stinear CM, Byblow WD. Elevated threshold for intracortical inhibition in focal hand dystonia. *Mov Disord* 2004;19:1312-1317.
11. Ziemann U, Rothwell JC, Ridding MC. Interaction between intracortical inhibition and facilitation in human motor cortex. *J Physiol* 1996;496(Pt 3):873-881.
12. Werhahn KJ, Kunesch E, Noachtar S, Benecke R, Classen J. Differential effects on motor cortical inhibition induced by blockade of GABA uptake in humans. *J Physiol* 1999;517(Pt 2):591-597.
13. Ziemann U, Lönnecker S, Steinhoff BJ, Paulus W. Effects of antiepileptic drugs on motor cortex excitability in humans: a transcranial magnetic stimulation study. *Ann Neurol* 1996;40:367-378.

14. Schwenkreis P, Liepert J, Witscher K, Fischer W, Weiller C, Malin JP, Tegenthoff M. Riluzole suppresses motor cortex facilitation in correlation to its plasma level: a study using transcranial magnetic stimulation. *Exp Brain Res* 2000;135:293-299.
15. Di Lazzaro V, Pilato F, Oliviero A, et al. Origin of facilitation of motor evoked potentials after transcranial magnetic stimulation: direct recording of epidural activity in conscious humans. *J Neurophysiol* 2006;96:1765-1761.
16. Naumann M, Magyar-Lehmann S, Reiners K, Erbguth F, Leenders KL. Sensory tricks in cervical dystonia: perceptual dysbalance of parietal cortex modulates frontal motor programming. *Ann Neurol*. 2000;47:322-328.
17. Lo SE, Gelb M, Frucht SJ. Geste antagonists in idiopathic lower cranial dystonia. *Mov Disord* 2007;22:1012-1017.
18. Bhidayasiri R, Bronstein JM. Improvement of cervical dystonia: possible role of transcranial magnetic stimulation simulating sensory tricks effect. *Med Hypotheses* 2005;64:941-945.

Dystonia and Tremor Secondary to Thalamic Infarction Successfully Treated With Thalamotomy of the Ventralis Intermedius Nucleus

Mario Álvarez, MD,^{1*} Nelson Quintanal, MD,² Amado Díaz, MD,¹ José Prince, MD,² Ivan García, MD,² Maylen Carballo, Lic,³ Rafael Rodríguez, MSc,³ Carlos Maragoto, MD,¹ Ivonne Pedrosa, MD¹ and Raul Macías, MD⁴

¹Movement Disorders Unit, International Center for Neurological Restoration (CIREN), Habana, Cuba ²Neurosurgery Service, Centro Internacional de Restauración Neurológica (CIREN), Habana, Cuba ³Brain Images Processing Group, Centro Internacional de Restauración Neurológica (CIREN), Habana, Cuba ⁴Neurophysiology Service, Centro Internacional de Restauración Neurológica (CIREN), Habana, Cuba



ABSTRACT

Background: Focal thalamic lesions have been associated with a variety of involuntary movements such as tremor, dystonia, and chorea-ballism.

Methods: We describe a patient with severe hyperkinesias of the right arm secondary to a thalamic infarction in the left postero-ventral region of the thalamus.

Results: The dystonia and tremor of the right upper limb were subsequently controlled with another surgical lesion of the ventralis intermedius nucleus of the thalamus.

Conclusion: This observation suggests that ablative surgery might be applied to treat a movement disorder induced by the lesion of the same nucleus, which in

addition lead to interesting pathophysiological conjectures. © 2014 International Parkinson and Movement Disorder Society

Key Words: thalamic infarction; dystonia; tremor; VIM; thalamotomy

Focal thalamic lesions have been associated with a variety of involuntary movements such as tremor, dystonia, and chorea-ballism. The most common movement disorder associated with thalamic lesions (i.e., posterolateral thalamus) is focal hand dystonia and postural tremor of the affected limb.^{1,2} This report describes a patient with severe hyperkinesia of the arm secondary to thalamic infarction that was markedly improved by another surgically controlled lesion of the ventralis intermedius nucleus (VIM) of the thalamus.

Case Report

A 38-year-old man had a history of renal disease since childhood. The patient presented at our hospital because of intractable right upper limb dyskinesias, which had ensued several years ago after a stroke, during a hypertensive crisis (blood pressure 200/130 mmHg on admission), which caused hemiparesis and sensory loss on the right body side. A computed tomography brain scan at that time showed a left thalamic infarct. The paresis and sensory loss improved, but severe involuntary movements in the right arm developed within 4 months after the stroke. Our examination indicated a residual mild right hemiparesis and right upper limb dysmetria. A 5 Hz tremor in the right arm, particularly involving the wrist and index finger at rest and the proximal musculature when extending the arm against gravity, was noticed (video segments 1 and 2). This postural tremor, which did not abate during action, made it impossible to use the right upper limb for any activity. With the patient in the supine position, a mild resting tremor in the right foot was seen (video segment 2). A mild dystonic flexor posture of the hand and fingers, with ulnar deviation when outstretching the arm, was also present on the right side. Magnetic resonance imaging of the head confirmed a hypo intense signal of 5 mm in diameter located in the ventral, posterolateral region of the left thalamus (Fig. 1A). Atrophy of the hemisphere and the left cerebral peduncle were seen, possibly related to the extended time elapsed after the infarction. Several drug treatments, including trihexyphenidyl, clonazepam, tetrabenazine, and carbamazepine were tried. All failed to produce an effect against the tremor and hand dystonia.

zepam, tetrabenazine, and carbamazepine were tried. All failed to produce an effect against the tremor and hand dystonia.

In view of the extent and intensity of the tremor of the right arm, the resistance to drug treatment, and the interference with daily activities, surgical treatment was decided on, and the VIM was chosen as the target. A VIM thalamotomy was conducted with the usual protocol in our center with semi-micro recording intraoperatively to verify the target.^{3,4} The stereotactic coordinates of the right VIM were 4 mm anterior to the posterior commissure, 15 mm lateral to the midline, and at the level of the intercommissural line. Intraoperative electrical stimulation of the right VIM attenuated tremor amplitude. Two radiofrequency lesions were made, with an approximate volume of 60 to 80 mm³ (Fig. 1B). Lesions were completed, keeping the temperature at 70°C for 60 seconds with a power of 8 watts. There was a clear amelioration of the hyperkinesias of the right upper limb within the operating room, once the lesions were completed.

Follow-up evaluations at 1 month and 1 year (video segments 3 and 4) indicated almost complete elimination of the dystonia and tremor, with functional recovery of the right arm and without adverse effects related to surgery. Mild hemiparesis persisted.

Discussion

This observation has some practical and pathophysiological interest. From a practical point of view, it implies that dyskinesias associated with a thalamic lesion requiring surgical treatment might be treated with a thermolytic lesion of the VIM, particularly if deep brain stimulation is not available or advisable. Deep brain stimulation and ablative surgery of the globus pallidus pars interna (GPi) can be equally effective to treat chorea-ballism secondary to a subthalamic lesion, dystonia, and levodopa-induced dyskinesias. However, we are not aware that surgery of the GPi or

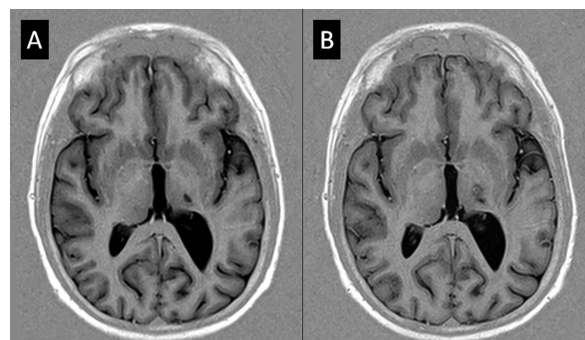


FIG. 1. Magnetic resonance imaging turbo inversion recovery axial slices. (A) Before surgery, the infarction in the ventral posterolateral left thalamus is observed. Some ipsilateral cerebral hemisphere atrophy with enlarged lateral ventricle is also present. (B) One week after VIM thalamotomy. The surgical lesion was located dorsally, medially, and anteriorly to the thalamic infarction.

*Correspondence to: Dr. M. Álvarez; Neurología, CIREN, Avenida 25, Playa, Habana, Cuba, E-mail: drmariaolvarez@gmail.com

Relevant conflicts of interest/financial disclosures: Nothing to report.

Received: 5 August 2013; **Revised:** 10 March 2014;

Accepted: 17 March 2014

Published online 17 May 2014 in Wiley Online Library (wileyonlinelibrary.com). DOI: 10.1002/mds.25889

thalamus had been applied to treat movement disorders secondary to a lesion of the same structure. This gives rise to some intriguing speculations.

First, how does a lesion of the ventro-postero-lateral thalamus produced tremors (all 3 presentation types) and hand dystonia? The lesion may disconnect the cortical sensory-motor areas, or have an impact on other thalamic nuclei or modify basal ganglia neuronal activity via the thalamo-striatal and thalamo-subthalamic projections.⁵ The movement disorders appeared several months after our patient suffered a stroke, suggesting some plastic changes or possible maladaptive rearrangements. This opens up the possibility that distant areas and circuits could become abnormally recruited as part of the process.

Second, the fact that a VIM lesion essentially eliminated the mixed movement disorders present in our patient indicates that the abnormal neuronal activity underlying these manifestations course via the cerebello-thalamo-cortical projection, but how this pathway could become dysfunctional by the thalamic infarction is not obvious to us. The VIM was chosen because we believed that the other typical surgical targets for movement disorders, that is, the GPi, were upstream from the causative site. However, we had no prior reason to believe the thalamic lesion could be as beneficial as it turned out to be. Thus, we must conclude that we have no valid explanation for the radical effect of surgery in this case. Further experience and thoroughly studied cases are needed to better understand the case reported here.

Legends to the Videos

Segments 1 and 2. Patient in the operating room before surgery. The tremor and dystonia of the right upper limb as seen here just before the surgery were similar to what the patient experienced normally.

Segments 3 and 4. Patient 1 year after surgery. Right upper limb dysmetria was present, but a significant improvement of dystonia and tremor was clearly present. No newer motor deficits are observed. ■

References

1. Obeso JA, Gimenez-Roldan S. Clinicopathological correlation in symptomatic dystonia. *Adv Neurol* 1988;50:113-122.
2. Lera G, Scipioni O, Garcia S, Cammarota A, Fischbein G, Gershanik O. A combined pattern of movement disorders resulting from posterolateral thalamic lesions of a vascular nature: a syndrome with clinico-radiologic correlation. *Mov Disord* 2000;15:120-126.
3. Lopez-Flores G, Miguel-Morales J, Teijeiro-Amador J, et al. Anatomic and neurophysiological methods for the targeting and lesioning of the subthalamic nucleus: Cuban experience and review. *Neurosurgery* 2003;52:817-830.
4. Teijeiro J, Macias RJ, Morales JM, et al. Personal-computer-based system for three-dimensional anatomic-physiological correlations during stereotactic and functional neurosurgery. *Stereotact Funct Neurosurg* 2000;75:176-187.

5. Lanciego JL, Gonzalo N, Castle M, Sanchez-Escobar C, Aymerich MS, Obeso JA. Thalamic innervation of striatal and subthalamic neurons projecting to the rat entopeduncular nucleus. *Eur J Neurosci* 2004;19:1267-1277.

Supporting Data

Additional Supporting Information may be found in the online version of this article at the publisher's web-site.

De Novo Mutation in the *GNAL* Gene Causing Seemingly Sporadic Dystonia in a Serbian Patient

Valerija Dobričić, PhD,^{1,2} Nikola Kresojević, MD,¹ Ana Westenberger, PhD,² Marina Svetel, MD,¹ Aleksandra Tomić, MD,¹ Vesna Ralić, BSc,¹ Igor Petrović, MD, MSc,¹ Milica Ječmenica Lukić, MD,¹ Katja Lohmann, PhD,² Ivana Novaković, MD, PhD,³ Christine Klein, MD,^{2*} and Vladimir S. Kostić, MD, PhD¹

¹Neurology Clinic CCS, School of Medicine, University of Belgrade, Belgrade, Serbia ²Institute of Neurogenetics, University of Lübeck, Lübeck, Germany ³Institute for Human Genetics, Faculty of Medicine, University of Belgrade, Belgrade, Serbia

ABSTRACT

Background: Mutations in *GNAL* (DYT25) have recently been established as the first confirmed cause of focal or segmental adult-onset dystonia. Mutation carriers show craniocervical involvement; however, the *GNAL* mutational and phenotypic spectrum remain to be further characterized, and guidelines for diagnostic testing need to be established.

Methods: The authors used Sanger sequencing to test for changes in the *GNAL* coding or splice-site regions in 236 Serbian patients suffering from isolated dystonia with craniocervical involvement.

Results: One novel likely pathogenic substitution (c.1061T>C; p.Val354Ala) in *GNAL* was detected in a sporadic cervical dystonia patient (mutation frequency: 0.4%). This mutation was not present in the DNA of either parent, despite confirmed parentage.

Conclusions: This is the first report of a de novo *GNAL* mutation causing genetically proven, seemingly sporadic DYT25 dystonia. Our finding highlights the importance of genetic testing for *GNAL* mutations in establishing the molecular diagnosis even for patients with a negative family history. © 2014 International Parkinson and Movement Disorder Society

Key Words: *GNAL*; DYT25; de novo mutation; isolated dystonia