

Pediatric dural arteriovenous malformations

Report of 3 cases

SHAUN P. APPADURAY, M.B.B.S., JAMES A. J. KING, F.R.A.C.S., ALISON WRAY, F.R.A.C.S.,
PATRICK LO, F.R.A.C.S., AND VIRGINIA MAIXNER, F.R.A.C.S.

Department of Neurosurgery, The Royal Children's Hospital Melbourne, Parkville, Victoria, Australia

Pediatric dural arteriovenous malformations (dAVMs) are rare lesions that have a high mortality rate and require complex management. The authors report 3 cases of pediatric dAVMs that presented with macrocrania and extracranial venous distension. Dural sinus thrombosis developed in 2 of the cases prior to any intervention, which is an unusual occurrence for this particular disease. All 3 cases were treated using staged endovascular embolization with a favorable outcome in 1 case and a poor outcome in the other 2 cases. Complications developed in all cases and included dural sinus thrombosis, parenchymal hemorrhage, intracranial venous hypertension, and seizures. The strategies and challenges used in managing these patients will be presented and discussed, along with a review of the literature. While outcomes remain poor, the authors conclude that prompt treatment with endovascular embolization provides the best results for children with these lesions. A well-established venous collateral circulation draining directly to the internal jugular veins may further improve the rate of favorable outcome after embolization.
(<http://thejns.org/doi/abs/10.3171/2014.4.PEDS13695>)

KEY WORDS • dural arteriovenous malformation • sinus thrombosis •
vascular disorders • endovascular embolization

PEDIATRIC dural arteriovenous malformations (dAVMs) are extremely rare, with only 59 cases reported in the literature as of 2010.¹⁰ In a review by Barbosa et al. of 620 cases of intracranial pediatric AVMs reported from 1985 to 2003, only 52 (8.4%) were dAVMs,¹ with the infantile subtype as the most frequent subtype.^{7,9,12,15} Pediatric dAVMs tend to be multifocal, with the transverse and sigmoid sinuses the most common sites of involvement. Pediatric dAVMs have a more aggressive clinical course relative to adult dAVMs, with a reported mortality rate greater than 25%.^{7,9,10} In this paper we report 3 cases of pediatric dAVMs that involved the transverse sinus associated with anomalous cerebral venous drainage, and describe their common presentation and clinical features.

Case Reports

Case 1

History and Examination. A 14-month-old boy presented with macrocrania and a 4-week history of progres-

sive facial venous distension. His antenatal history was remarkable for preterm delivery at 36 weeks gestation. At presentation, his head circumference was tracking along the 97th percentile. Marked dilation of the facial veins was noted bilaterally. Neurological and developmental examinations were normal, and cardiology, ophthalmology, and hematology assessments were unremarkable.

Magnetic resonance imaging of the brain revealed a complex dAVM involving the right mastoid and petrous apex regions (Fig. 1A). The dAVM was fed by branches of the right middle meningeal artery (MMA) and the occipital and posterior auricular branches of the right external carotid artery (ECA). Cerebral venous outflow was anomalous, with complete occlusion of the sigmoid sinus–internal jugular vein (IJV) junction on the right and significant narrowing on the left. Venous drainage thereby occurred via enlarged cortical veins over the right hemisphere and thus into the right superior and inferior ophthalmic veins. Direct arterial fistulas from the right ECA to the right sigmoid sinus and cavernous sinus were also demonstrated. Subsequent digital subtraction angiography (DSA) confirmed the MRI findings and demonstrated retrograde flow along the right sigmoid and transverse sinuses (Fig. 1B).

First Endovascular Embolization and Postoperative Course. While under investigation the patient re-presented with focal seizures and tonic eye deviation, and 2 weeks

Abbreviations used in this paper: dAVM = dural arteriovenous malformation; dAVS = dural arteriovenous shunt; DSA = digital subtraction angiography; ECA = external carotid artery; ICA = internal carotid artery; IJV = internal jugular vein; IOP = intraocular pressure; MMA = middle meningeal artery; OA = occipital artery.

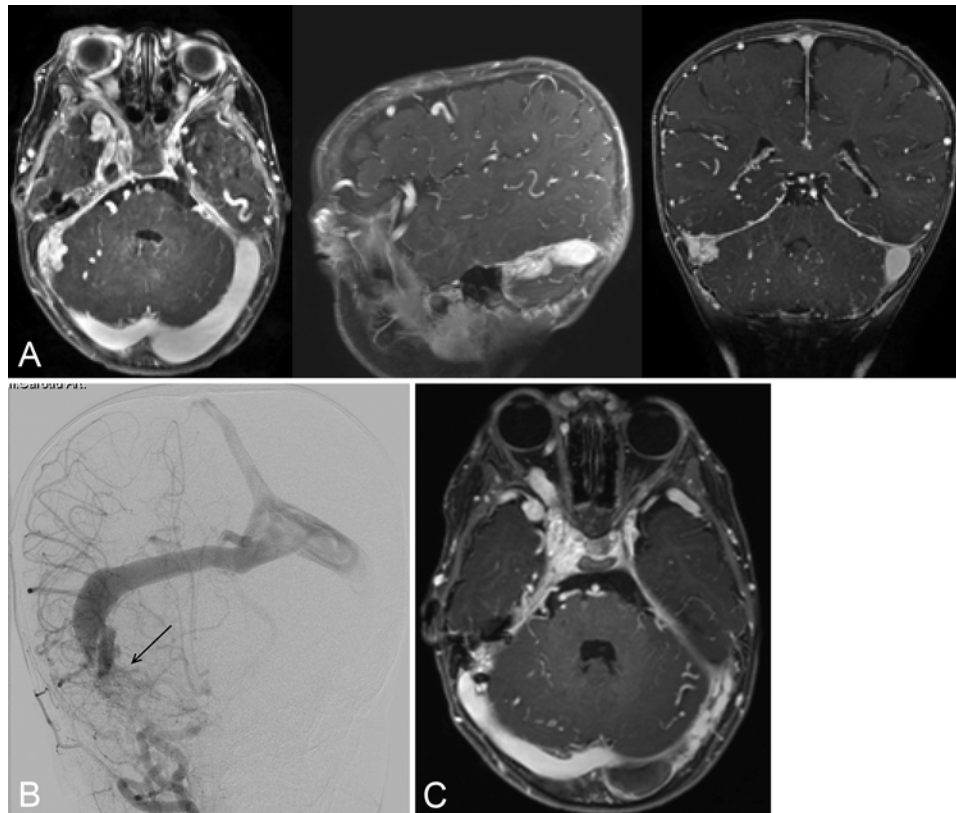


Fig. 1. Case 1. **A:** Axial (left), sagittal (center), and coronal (right) T1-weighted MR images after contrast administration show a dAVM at the right petrous apex with venous engorgement of cortical veins. **B:** Right common carotid angiogram showing a dAVM (arrow) draining to the right transverse sinus and demonstrating retrograde flow of the superior sagittal sinus. **C:** Axial T1-weighted postcontrast MR image showing left transverse sinus thrombosis.

later with irritability and vomiting following an unwitnessed fall with head strike. Repeat imaging studies revealed acute thrombosis of the left sigmoid sinus extending to the transverse sinus. Given the significant venous hypertension induced by the thrombosis on a compromised venous outflow, the patient underwent emergency endovascular embolization of the right MMA and occipital artery (OA) feeders of the dAVM, with a combination of the embolic agent Onyx (ev3 Neurovascular) and polyvinyl alcohol. Anticoagulation with enoxaparin (Sanofi) was begun and continued for 3 months to prevent further thrombosis and to encourage recanalization of the left sigmoid sinus. His right intraocular pressure (IOP) at the time was noted to be elevated and was managed with latanoprost (Pfizer).

Over the next 6 months, repeat MRI studies demonstrated decreased flow in the dAVM. The left sigmoid sinus thrombosis initially recanalized, but later rethrombosed with extension to the transverse sinus and torcular herophili. The right sigmoid sinus became partially occluded and venous collaterals (dural and extracranial) draining to the IJVs bilaterally were noted. These changes were presumed to be related to altered vascular dynamics induced by the endovascular embolization (Fig. 1C).

Second Endovascular Embolization and Postoperative Course. Two years after embolization, repeat DSA demonstrated occlusion of the left transverse sinus, with venous drainage now maintained by the cavernous sinus

and ophthalmic veins. New feeders to the dAVM from the right OA and meningeal branch of the right internal carotid artery (ICA) were observed. These findings, along with increasing IOP despite treatment and a rapidly enlarging head circumference, prompted additional intervention. He therefore underwent embolization of the right OA and the meningeal branches of the right ICA using Onyx. Anticoagulation was begun at this time for a duration of 2 weeks after embolization. His postoperative course was uneventful. At last review, 12 months after his last embolization, he was clinically well with reduced head circumference, IOP, and facial venous distension. He has mild developmental delay.

Case 2

History and Examination. A 23-month-old boy presented with macrocrania and a 4-week history of right-sided pulsatile proptosis on a medical history background of recent viral infection associated with dehydration. His antenatal history was unremarkable. Clinical examination was significant for the above finding with a baseline head circumference tracking along the 97th percentile. There were no other ophthalmological findings. Neurological and developmental examinations were normal and cardiology and hematology assessments were unremarkable.

A brain MR image revealed a complex dAVM with bilateral arterial feeders from the ECA (posterior auricu-

lar and occipital arteries) and posterior cerebral artery, which was subsequently confirmed on DSA. Fistulous arterial feeders were located adjacent to the left transverse sinus and drained directly into it at the level of the torcular herophili. Normal venous outflow was significantly impaired due to subacute occlusive thrombosis of the left sigmoid sinus, superimposed on presumed congenital bilateral sigmoid sinus outflow stenoses. The majority of venous outflow therefore occurred in a retrograde manner via the superior sagittal sinus and cortical veins bilaterally, eventually draining into the right cavernous sinus (Fig. 2A and B).

First Endovascular Embolization and Postoperative Course. In view of his poor venous drainage and progressive proptosis, endovascular therapy was recommended to reduce arteriovenous shunting. Embolization of the left ECA feeders was performed using the embolic agent Onyx. Anticoagulation was not believed to be indicated due to the subacute nature of the sigmoid sinus thrombosis and the potential for hemorrhage, given the significant venous hypertension. His postoperative course was uneventful. At the 4-week review the child was clinically well with significant improvement of the proptosis. Decreased flow of the dAVM was noted on MRI.

Six months later he re-presented with complex partial seizures. A CT scan of his brain with contrast administration showed thrombosis of the left cortical veins and acute right sigmoid sinus thrombosis extending to the tor-

cular herophili. Further endovascular treatment was not deemed appropriate at this stage due to the complexity of the dAVM and the presumptive risk of aggravation of the sinus thrombosis. He was started on anticoagulation therapy using enoxaparin in an attempt to recanalize the thromboses to improve venous outflow, which was partially successful.

Subsequent Endovascular Embolizations and Postoperative Course. Over the next 30 months, his seizure disorder increased in severity, with several admissions for status epilepticus. He developed unprovoked cortical venous thromboses. Radiographic studies during this time demonstrated chronic venous ischemic changes with atrophy of the left temporoparietal region and bilateral hippocampal sclerosis (Fig. 2C). These changes were associated with developmental, cognitive, and behavioral decline. Repeat DSA revealed new arterial feeders contributing to the dAVM at the level of the torcular herophili, originating from the posterior cerebral artery and temporal and occipital branches of the ECA bilaterally. Although he underwent 2 further embolization procedures to reduce the inflow to his venous system, these procedures were complicated by seizures, extensive venous sinus thromboses, and ventriculomegaly, despite the use of transient anticoagulation therapy. The last embolization was complicated by delayed intraparenchymal hemorrhage with intraventricular extension. In the setting of significant neurological decline with intractable seizures and poor

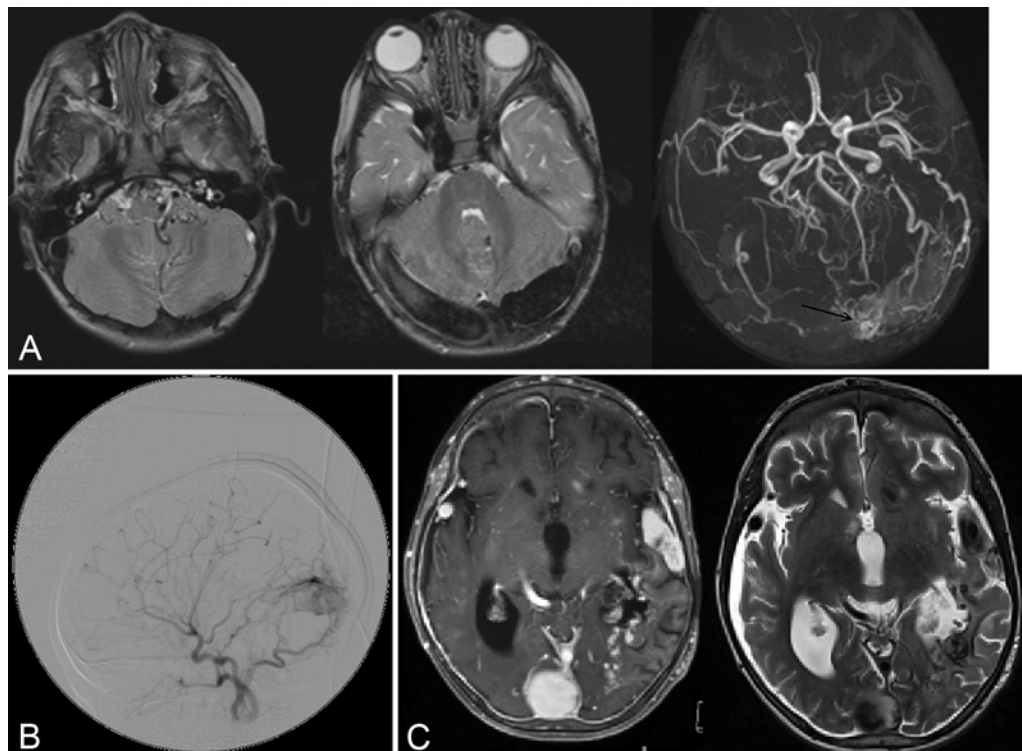


FIG. 2. Case 2. **A:** Axial T2-weighted MR images show occlusive thrombus of the left sigmoid sinus (left) and early thrombosis of the right sigmoid sinus (center). An MR angiogram (right) shows a dAVM (arrow) adjacent to the left transverse sinus. **B:** Left common carotid angiogram showing a dAVM arising from branches of the left ECA and ICA. **C:** Axial T1-weighted postcontrast MR image (left) and T2-weighted MR image (right) show left temporoparietal chronic venous ischemic changes, enlarged cortical veins, and dilated torcular herophili.

Pediatric dural arteriovenous malformations

conscious state, the patient's family opted for palliative care, with subsequent death of the child 4 days later.

Case 3

History and Examination. This 3-year-old girl presented with macrocrania and gross-motor delay. Her antenatal history was significant for maternal systemic lupus erythematosus, for which her mother received azathioprine, hydroxychloroquine, prednisolone, aspirin, and enoxaparin throughout the pregnancy. At presentation the patient's head circumference was tracking along the 97th percentile. Distended scalp veins were noted. She had gross-motor developmental delay. Her neurological examination was remarkable for hypertonicity, hyperreflexia, and nonsustained clonus bilaterally. Ophthalmological assessment revealed bilateral papilledema. Cardiology and hematology assessments were unremarkable.

A brain MR image demonstrated a dAVM in the left posterior fossa, adjacent to the torcular herophili. A Type I Chiari malformation was also demonstrated. Of note, there was no syringomyelia (Fig. 3A). Subsequent DSA confirmed the MRI findings and demonstrated bilateral feeders from the OA and posterior communicating arteries, with additional feeders from the right superficial temporal and vertebral arteries. Venous drainage occurred via a dominant right transverse sinus and IJV, and ret-

rogradely via the straight sinus and superficial and deep cortical veins. There was reduced venous outflow via the left sigmoid sinus and IJV, secondary to narrowing of the left sigmoid sinus–IJV junction (Fig. 3B).

Endovascular Embolizations and Postoperative Course. In view of her clinical status, the patient underwent 2 endovascular embolization procedures over the next 2 months to reduce arteriovenous shunting. The left and subsequently right OA and MMA feeders were embolized using Onyx. Her postoperative course was uncomplicated in both instances. Follow-up brain MRI showed decreased flow in the dAVM.

One month after embolization, she presented with a transient episode of vomiting and lethargy that resolved spontaneously over 24 hours. Repeat imaging demonstrated no evidence of hemorrhage or dural sinus thrombosis. She re-presented the following month with sudden-onset vomiting, bradycardia, and obtundation. Imaging revealed an occlusive right-sided thrombus extending from the sigmoid sinus to the IJV, resulting in acute hydrocephalus and requiring emergency extraventricular drain insertion (Fig. 3C). In retrospect, her initial presentation after embolization may have been due to altered vascular dynamics with sluggish flow within the right transverse sinus. She was started on heparin; however, 2 weeks later, she developed significant intraparenchymal hemorrhage

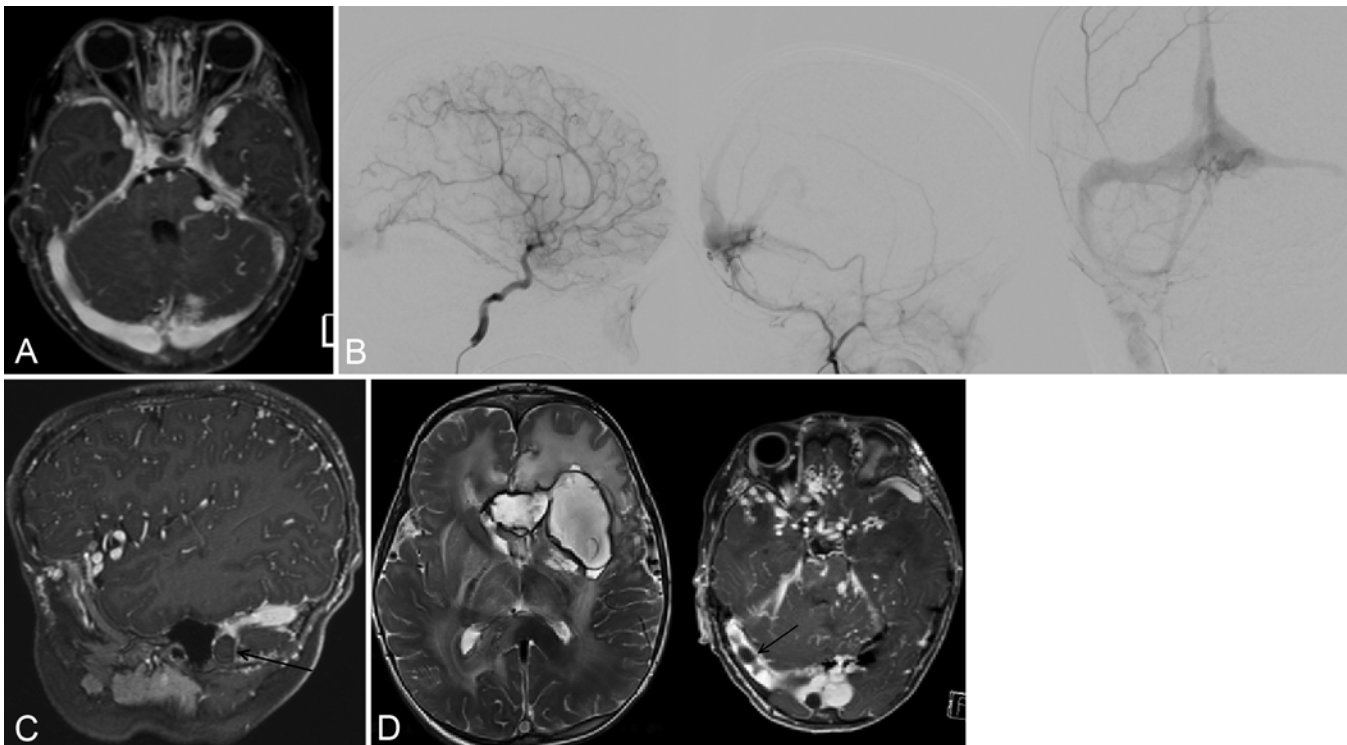


FIG. 3. Case 3. **A:** Axial T1-weighted postcontrast MR image showing a dAVM in the left posterior fossa, adjacent to the torcular herophili. Dilated cortical veins are noted. **B:** Angiograms of the right ICA (*left*) and right ECA (*center*) show a dAVM nidus fed by branches of the right ICA and ECA. Anteroposterior view of a right ECA angiogram (*right*) demonstrates retrograde flow and narrowing of the left sigmoid sinus. **C:** Sagittal T1-weighted postcontrast MR image shows occlusive thrombosis of the right sigmoid sinus (*arrow*). **D:** Axial T2-weighted MR image (*left*) shows a large intraparenchymal hemorrhage associated with cerebral edema in the bilateral frontal lobes and basal ganglia. An axial T1-weighted postcontrast MR image (*right*) shows extension of the right transverse sinus thrombosis (*arrow*).

with bilateral intraventricular extension, leading to immediate cessation of anticoagulation therapy and insertion of a new extraventricular drain.

Over the next 2 months, seizures and multifocal intraparenchymal hemorrhages contributed to the patient's declining neurological status despite additional drainage attempts. Repeat MRI during this time showed evolution of the existing hematomas, progression of the thrombosis into the right transverse sinus, and diffuse cerebral edema in the frontal, temporal, and parietal regions bilaterally. Early signs of cortical liquefaction consistent with subacute ischemia were also present (Fig. 3D). Despite the inherent risk, anticoagulation was re-trialed in an attempt to restore venous outflow. Her neurological status, however, did not improve and her family elected for palliative care, with subsequent death of the child 3 days later.

Discussion

Pediatric dAVMs are commonly attributed to a disorder of venous sinus formation, with sinus wall overgrowth and abnormal venous space development in the sigmoid and transverse sinuses and torcular herophili.^{3,6,8,11,14,18} The embryology of cerebral venous development as described by Padget,^{19,20} Okudera et al.,¹⁸ and Raybaud²³ can be divided into 7 stages.^{19,20,23} In stage 7A (week 12 of gestation), the conglomerate of channels that constitute the tentorial plexus of the primitive cerebrum merge to form the torcular herophili.^{19,20,23} This posterior dural plexus persists after birth. The increase in venous flow from the rapidly growing cerebral hemispheres leads to ballooning of the transverse sinuses between the fourth and sixth months of gestation. In pediatric dAVMs, it is believed that expansion and remodeling of the posterior sinuses persist beyond this time frame.^{3,6,8,11,14,18,23} In contrast, most cases of adult dAVMs are believed to be caused by thrombosis of a dural venous sinus, typically secondary to head trauma or a hypercoagulable state. The resulting occlusion and venous hypertension causes dilation of capillaries, which open direct shunts between dural arteries and veins.^{4,17,22} We believe that the dAVMs in all 3 of our cases developed from abnormal venous sinus formation, as the lesions were already well established on initial investigation and there was no evidence of a hypercoagulable state or significant head trauma prior to presentation. Regardless of the actual mechanism, the key factor in the development of adult or pediatric dAVMs appears to be decreased blood flow and subsequent occlusion and shunting within the dural venous sinus.^{4,5} The presence of anomalous sigmoid sinus–IJV outflow noted in all our cases would support this hypothesis.

Pediatric dAVMs have been classified into 3 types: dural sinus malformations, infantile dural arteriovenous shunts (dAVSs), and adult-type dAVSs.^{10,11,13} Dural sinus malformations are further divided into two subtypes: 1) those involving the posterior sinuses with or without the torcular herophili, with giant dural lakes and slow-flow mural arteriovenous shunting; and 2) those involving the jugular bulb with otherwise normal sinuses, but associated with a high-flow sigmoid sinus dAVM. Patients with dural sinus malformations typically present with

high-output cardiac failure, venous sinus thrombosis, and consumptive coagulopathy in the antenatal or neonatal period.^{3,10,11,13} Infantile dAVSs are high-flow, low-pressure systems with patent sinuses and no venous lakes. Meningeal and occipital vessels are often directly involved. Clinically, infantile dAVSs manifest in early childhood with macrocrania, seizures, hydrocephalus, and progressive neurological deficits.^{7–11,13} Adult dAVSs present in older children and are nearly always located in the cavernous sinus. These are generally secondary to trauma, venous sinus thrombosis, or surgery, and present with venous hypertension, proptosis, and chemosis.^{7,9,10,13} Patients may also present with significant intracranial hemorrhage and neurological deficits if cortical venous hypertension is present.⁴ The arterial supply, venous drainage, sites of the dAVM, and clinical presentation of the cases in this series were similar to those reported in the literature with respect to infantile dAVSs. Interestingly, Cases 1 and 2 developed dural sinus thrombosis in early childhood prior to any intervention, which is atypical for this subtype of dAVM. We postulate that the thrombosis was precipitated by dehydration due to vomiting after concussion in Case 1, and a viral illness in Case 2.

Treatment of pediatric dAVMs is primarily via endovascular embolization, both transarterial and transvenous. Transumbilical embolization has been rarely used. Embolization has often been performed in stages to achieve gradual closure of the shunt in an attempt to maintain the patency of the abnormally enlarged dural sinus, allowing it time to undergo remodelling.^{6,8–11,13–15} Medical treatment with anticoagulants, diuretics, and inotropic agents have been used in this process to prevent dural sinus thrombosis and hyperdynamic cardiac failure.^{9,14} Radiation therapy has been used to treat adult dAVMs, but its role in pediatric dAVMs is less clear due to the young ages of the patients.^{9,12,14,15} Surgical treatment alone without previous embolization carries the risk of significant intraoperative blood loss with high rates of mortality and morbidity.^{6,9,10,13–15} Direct surgical intervention has only rarely been reported, such as by Monges et al.¹⁶ Our initial management decisions in Cases 1 and 2 were affected by the coexisting venous sinus thromboses, due to the significant risk of causing further thrombosis and obstruction of an already compromised drainage system. While clinical and radiological improvement was achieved in the immediate postoperative period using transarterial embolization, additional thromboses did eventually develop in both cases. The management of pediatric dAVMs in the context of coexisting dural sinus thrombosis is poorly documented due to the rarity of these lesions.

Outcomes of treatment for pediatric dAVMs are poor. Morita et al.¹⁷ reported an overall mortality rate of 38% in a literature review up to 1995. This was consistent with the findings of Barbosa et al.¹ who reported a mortality rate of 37.9% in 2003. As of 2010, the overall rate has dropped to 26%,¹⁰ but it is unclear if this was due to better embolization techniques or a lack of follow-up in these cases. Dural sinus malformations are reported to be associated with a better prognosis when there is unilateral dural sinus involvement remote from the torcular herophili or superior sagittal sinus, due to adequate al-

Pediatric dural arteriovenous malformations

ternate cerebral venous drainage in the event of involved sinus thrombosis or occlusion. The presence of bilateral cavernous sinus drainage and the absence of jugular bulb dysmaturation or occlusion are also favorable factors in the prognosis of dural sinus malformations.^{1,6,14} We are unaware of any previous reports in the literature that suggest these factors apply to infantile dAVSs, but we note that while the torcular herophili was involved only marginally in Case 1, it was extensively involved in the other cases as the site of the dAVM. Venous outflow obstruction secondary to occlusive dural sinus thrombosis was present in all cases, but only Case 1 developed collaterals draining directly to the IJVs. These factors may have accounted for the favorable outcome of Case 1.

Transarterial embolization often results in the recruitment of secondary arterial feeders, which may lead to a recurrence of symptoms. This was consistent with our series, in which Cases 1 and 2 developed significant recruitment subsequent to endovascular therapy. Excessive tortuosity of the affected vessels has also been reported to hamper attempts at transarterial embolization.^{8,9,11,15} Transvenous embolization is typically only used when there is sufficient venous collateral circulation, as it usually results in complete occlusion of the affected sinus. The rerouting of blood through cortical veins and deep venous sinuses to ultimately drain into the superior ophthalmic and facial veins has been described previously in the literature and was well demonstrated in our series.^{2,9,11,15}

All 3 of our cases experienced aggravation or formation of dural sinus thrombosis within 9 months of embolization, which resulted in increased venous hypertension. This in turn led to progressively increasing IOP in Case 1 and complex seizure disorders in Cases 2 and 3. Additionally, Cases 2 and 3 were further complicated by the development of intracerebral hemorrhages likely secondary to anticoagulation therapy. While anticoagulation therapy for dural sinus thrombosis improves outcomes even in the presence of intracranial hemorrhage,²¹ the guidelines for management of these lesions in the context of coexisting infantile dAVSs are unclear.

Conclusions

In this paper we report 3 cases of pediatric dAVMs in children illustrating the pathogenesis, clinical subtypes, and current management of this rare disease. We also note the atypical development of dural sinus thrombosis in 2 of our cases prior to intervention, which made subsequent management significantly more challenging. While outcomes remain poor for children with these lesions, prompt treatment with endovascular embolization provides the best results.^{6,8–10,14} Our experience suggests that a well-established venous collateral circulation draining directly to the IJV may further improve the rate of favorable outcome after embolization.

Disclosure

The authors report no conflict of interest concerning the materials or methods used in this study or the findings specified in this paper.

Author contributions to the study and manuscript preparation include the following. Conception and design: Appaduray, Maixner. Acquisition of data: Appaduray. Analysis and interpretation of data: Appaduray. Drafting the article: Appaduray. Critically revising the article: all authors. Reviewed submitted version of manuscript: all authors. Approved the final version of the manuscript on behalf of all authors: Appaduray. Study supervision: Maixner.

References

1. Barbosa M, Mahadevan J, Weon YC, Yoshida Y, Ozanne A, Rodesch G, et al: Dural sinus malformations (DSM) with giant lakes, in neonates and infants. Review of 30 consecutive cases. *Interv Neuroradiol* **9**:407–424, 2003
2. Buchanan TAS, Harper DG, Hoyt WF: Bilateral proptosis, dilatation of conjunctival veins, and papilloedema: a neuro-ophthalmological syndrome caused by arteriovenous malformation of the torcular herophili. *Br J Ophthalmol* **66**:186–189, 1982
3. Byrd SE, Abramowicz JS, Kent P, Kimura RE, Elias D, Heydeman PT: Fetal MR imaging of posterior intracranial dural sinus thrombosis: a report of three cases with variable outcomes. *Pediatr Radiol* **42**:536–543, 2012
4. Chaichana KL, Coon AL, Tamargo RJ, Huang J: Dural arteriovenous fistulas: epidemiology and clinical presentation. *Neurosurg Clin N Am* **23**:7–13, 2012
5. Chaudhary MY, Sachdev VP, Cho SH, Weitzner I Jr, Puljic S, Huang YP: Dural arteriovenous malformation of the major venous sinuses: an acquired lesion. *AJNR Am J Neuroradiol* **3**:13–19, 1982
6. de Haan TR, Padberg RD, Hagebeuk EEO, Aronica E, van Rijn RR, Majoie CBLM, et al: A case of neonatal dural sinus malformation: clinical symptoms, imaging and neuropathological investigations. *Eur J Paediatr Neurol* **12**:41–45, 2008
7. Geibprasert S, Krings T, Pereira V, Lasjaunias P: Infantile dural arteriovenous shunt draining into a developmental venous anomaly. *Interv Neuroradiol* **13**:67–74, 2007
8. Herman TE, Siegel MJ: Congenital dural arteriovenous fistula at torcular Herophili. Endovascular embolization. *J Perinatol* **27**:730–731, 2007
9. Kincaid PK, Duckwiler GR, Gobin YP, Viñuela F: Dural arteriovenous fistula in children: endovascular treatment and outcomes in seven cases. *AJNR Am J Neuroradiol* **22**:1217–1225, 2001
10. Ko A, Filardi T, Giussani C, Ghodke R, Browd SR: An intracranial aneurysm and dural arteriovenous fistula in a newborn. *Pediatr Neurosurg* **46**:450–456, 2010
11. Komiyama M, Nishikawa M, Kitano S, Sakamoto H, Miyagi N, Kusuda S, et al: Transumbilical embolization of a congenital dural arteriovenous fistula at the torcular herophili in a neonate. Case report. *J Neurosurg* **90**:964–969, 1999
12. Lanzino G, Jensen ME, Kongable GL, Kassell NF: Angiographic characteristics of dural arteriovenous malformations that present with intracranial hemorrhage. *Acta Neurochir (Wien)* **129**:140–145, 1994
13. Lasjaunias P, Maguifis G, Goulao A, Piske R, Suthipongchai S, Rodesch R, et al: Anatomoclinical aspects of dural arteriovenous shunts in children. Review of 29 cases. *Interv Neuroradiol* **2**:179–191, 1996
14. Liu CA, Chen HC, Luo CB, Guo WY, Mu-Huo Teng M, Chen HH, et al: Dural sinus malformation with arteriovenous fistulae in a newborn: positive outcome following endovascular management. *J Chin Med Assoc* **75**:43–46, 2012
15. Liu HM, Kuo MF, Tu YK: Embolization of a giant torcular dural arteriovenous fistula in a neonate. *Pediatr Neurosurg* **30**:258–262, 1999
16. Monges JA, Galarza M, Sosa FP, Ceiliano A: Direct surgical approach of a congenital dural arteriovenous fistula at the torcular herophili in a neonate. Case illustration. *J Neurosurg (4 Suppl)* **102**:440, 2005

17. Morita A, Meyer FB, Nichols DA, Patterson MC: Childhood dural arteriovenous fistulae of the posterior dural sinuses: three case reports and literature review. **Neurosurgery** **37**:1193–1200, 1995
18. Okudera T, Huang YP, Ohta T, Yokota A, Nakamura Y, Maehara F, et al: Development of posterior fossa dural sinuses, emissary veins, and jugular bulb: morphological and radiologic study. **AJNR Am J Neuroradiol** **15**:1871–1883, 1994
19. Padget DH: The cranial venous system in man in reference to development, adult configuration, and relation to the arteries. **Am J Anat** **98**:307–355, 1956
20. Padget DH: The development of the cranial venous system in man from the viewpoint of comparative anatomy. **Contrib Embryol** **36**:81–140, 1957
21. Paner A, Jay WM, Nand S, Michaelis LC: Cerebral vein and dural venous sinus thrombosis: risk factors, prognosis and treatment—a modern approach. **Neuroophthalmology** **33**:237–247, 2009
22. Pierot L, Chiras J, Duyckaerts C, Jason M, Martin N: Intracranial dural arteriovenous fistulas and sinus thrombosis. Report of five cases. **J Neuroradiol** **20**:9–18, 1993
23. Raybaud C: Normal and abnormal embryology and development of the intracranial vascular system. **Neurosurg Clin N Am** **21**:399–426, 2010

Manuscript submitted December 30, 2013.

Accepted April 15, 2014.

Please include this information when citing this paper: published online May 9, 2014; DOI: 10.3171/2014.4.PEDS13695.

Address correspondence to: Shaun P. Appaduray, M.B.B.S., Department of Neurosurgery, The Royal Children's Hospital Melbourne, 50 Flemington Rd., Parkville, VIC 3052, Australia. email: shaunprevin88@gmail.com.