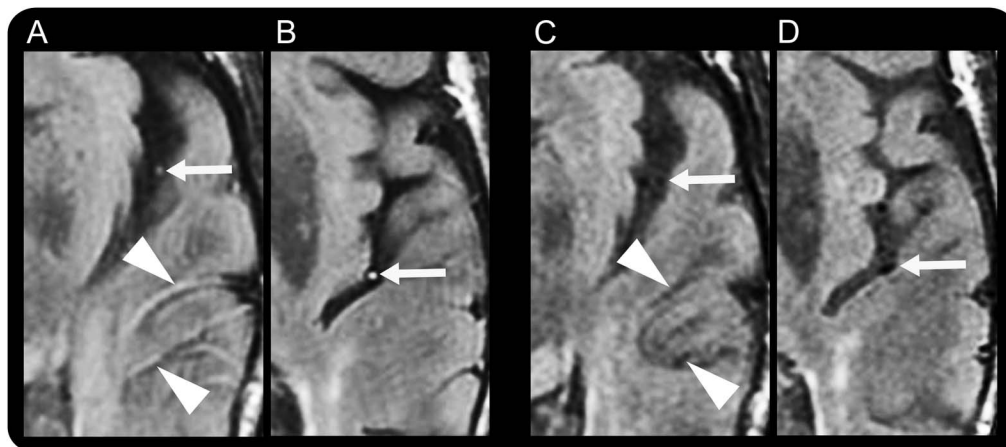


# FLAIR vascular hyperintensity resolution in a TIA patient

## Clinical–radiologic correlation

**Figure** Vascular intensity changes on fluid-attenuated inversion recovery during and after resolution of symptoms in our TIA patient



Fluid-attenuated inversion recovery vascular hyperintensities (FVH) during aphasia, including dot-like (arrows in A and B) and serpentine (arrowheads in A) hyperintensities, were seen in the middle cerebral artery branches. There were no abnormalities on diffusion-weighted or gradient echo images or magnetic resonance angiography. After aphasia resolution, the MRI showed FVH disappearance (C, D).

An 83-year-old woman presented with acute aphasia. Brain MRI, performed 3 hours after symptom onset, showed isolated fluid-attenuated inversion recovery vascular hyperintensities (FVH) in the left middle cerebral artery, including dot-like and serpentine hyperintensities (figure). Immediately after this first MRI (i.e., 3 hours and 15 minutes after symptom onset), aphasia resolved. A second MRI performed 15 minutes later showed FVH disappearance.

Only 20% of TIA patients showed FVH when MRI was performed within 24 hours.<sup>1</sup> Because FVH in this case were transient and correlated with symptom resolution, the prior report may have underestimated the true frequency of their occurrence.

*Guillaume Taieb, MD, Dimitri Renard, MD, Francesco Macri, MD*

From CHU Nîmes, Hôpital Caremeau, Nîmes, France.

*Author contributions:* Guillaume Taieb: drafting/revising the manuscript, study concept or design, analysis or interpretation of data. Dimitri Renard: drafting/revising the manuscript, analysis or interpretation of data. Francesco Macri Gerasoli: drafting/revising the manuscript, study concept or design, analysis or interpretation of data.

*Study funding:* No targeted funding reported.

*Disclosure:* The authors report no disclosures relevant to the manuscript. Go to [Neurology.org](http://Neurology.org) for full disclosures.

*Correspondence to Dr. Taieb:* [taiebguillaume@gmail.com](mailto:taiebguillaume@gmail.com)

1. Kobayashi J, Uehara T, Toyoda K, et al. Clinical significance of fluid-attenuated inversion recovery vascular hyperintensities in transient ischemic attack. *Stroke* 2013;44:1635–1640.