

Published in final edited form as:

Neurobiol Aging. 2014 October ; 35(10): 2419.e23–2419.e25. doi:10.1016/j.neurobiolaging.2014.04.010.

Homozygous *TREM2* mutation in a family with atypical frontotemporal dementia

Isabelle Le Ber^{#a,b,c,d,e}, Anne De Septenville^{#a,b,c}, Rita Guerreiro^{#f}, José Bras^f, Agnès Camuzat^{a,b,c}, Paola Caroppo^{a,b,c}, Serena Lattante^{a,b,c}, Philippe Couarch^{a,b,c}, Edor Kabashi^{a,b,c}, Kawtar Bouya-Ahmed^{a,b,c}, Bruno Dubois^{a,b,c,d,e}, and Alexis Brice^{a,b,c,e,g,*}

^aInstitut National de la Santé et de la Recherche Médicale, Unité Mixte de Recherche_S1127, Centre de Recherche de l'Institut du Cerveau et de la Moelle, Paris, France ^bUniversité Pierre et Marie Curie Univ, Unité Mixte de Recherche_S975, Centre de Recherche de l'Institut du Cerveau et de la Moelle, Paris, France ^cCentre National de Recherche Scientifique, Unité Mixte de Recherche_S7225, Paris, France ^dAssistance Publique-Hôpitaux de Paris, Hôpital de la Pitié-Salpêtrière, Centre de Référence des Démences Rares, Paris, France ^eAssistance Publique-Hôpitaux de Paris, Hôpital de la Pitié-Salpêtrière, Département de Neurologie, Paris, France ^fReta Lilla Weston Laboratories and Department of Molecular Neuroscience, Institute of Neurology London, London, England ^gAssistance Publique-Hôpitaux de Paris, Hôpital de la Pitié-Salpêtrière, Département de Génétique et Cytogénétique, Unité Fonctionnelle de Neurogénétique Moléculaire et Cellulaire, Paris, France

[#] These authors contributed equally to this work.

Abstract

TREM2 mutations were first identified in Nasu-Hakola disease, a rare autosomal recessive disease characterized by recurrent fractures because of bone cysts and presenile dementia. Recently, homozygous and compound heterozygous *TREM2* mutations were identified in rare families with frontotemporal lobar degeneration (FTLD) but without bone involvement. We identified a p.Thr66Met heterozygous mutation in a new consanguineous Italian family. Two sibs had early onset autosomal recessive FTLD without severe bone disorders. Atypical signs were present in this family: early parietal and hippocampus involvement, parkinsonism, epilepsy, and corpus callosum thickness on brain magnetic resonance imaging. This study further demonstrates the implication of *TREM2* mutations in FTLD phenotypes. It illustrates the variability of bone phenotype and underlines the frequency of atypical signs in *TREM2* carriers. This and previous studies evidence that *TREM2* mutation screening should be limited to autosomal recessive FTLD with atypical phenotypes characterized by: (1) a very young age at onset (20–50 years); (2) early parietal and hippocampal deficits; (3) the presence of seizures and parkinsonism; (4) suggestive

© 2014 Elsevier Inc. All rights reserved.

*Corresponding author at: Centre de Recherche de l'Institut du Cerveau et de la Moelle, Institut National de la Santé et de la Recherche Médicale, Unité Mixte de Recherche_S1127, Hôpital de la Salpêtrière, Paris, France. Tel.: +33 1 57 27 46 82; fax: +33 1 57 27 47 95. alexis.brice@upmc.fr (A. Brice).

Disclosure statement: The authors declare no conflict of interest.

extensive white matter lesions and corpus callosum thickness on brain magnetic resonance imaging.

Keywords

FTLD; FTD; TREM2; Nasu-Hakola; PLOSL; Dementia; Alzheimer's disease

1. Introduction

TREM2 (triggering receptor expressed on myeloid cells 2 protein) mutations have been first identified in polycystic lipomembranous osteodysplasia with sclerosing leukoencephalopathy (PLOSL, MIM 605086), a rare autosomal recessive disease also known as Nasu–Hakola disease (Bianchin et al., 2004). Main symptoms are recurrent fractures because of bone cysts and a progressive presenile dementia. Recently, homozygous and compound heterozygous *TREM2* mutations have been identified in rare families of Turkish and Colombian origin with autosomal recessive behavioral variant of frontotemporal lobar degeneration (FTLD) but without any clinical or radiological evidence of bone involvement (Giraldo et al., 2013; Guerreiro et al., 2013a, 2013b). Moreover, the presence of a rare *TREM2* polymorphism, p.R47H, has been strongly associated to an increased risk of developing Alzheimer's disease (Guerreiro et al., 2013c; Pottier et al., 2013). In this study, we report a new consanguineous Italian family presenting atypical autosomal recessive FTLD caused by homozygous *TREM2* mutation.

2. Methods

Two sibs (001, 025) from a consanguineous Italian family (Fig. 1A) affected by autosomal recessive FTLD have been sampled. This study was approved by the Ethics Committee of “AP-HP, Paris”; both patients have signed an informed consent. The whole exome has been sequenced on DNA samples of both sibs, after exclusion of mutations in the main FTLD genes (*C9ORF72*, *PGRN*, *MAPT*, *VCP*, *SQSTM1*, *TARDBP*, *CHMP2B*). Briefly, genomic DNA of patients was prepared according to Illumina's TruSeq Sample Preparation v3 (Illumina, CA, USA) and sequence capture, enrichment, and elution was performed according to manufacturer's protocols (Illumina's TruSeq Exome Enrichment). Sequencing was performed on Illumina's HiSeq2000 using 100 bp paired-end reads. Sequence alignment and variant calling were performed against the reference human genome (UCSC hg19) using BWA and the Genome Analysis Toolkit. We assumed an autosomal recessive mode of inheritance. Homozygous and compound heterozygous variants shared by the 2 patients were selected. Polymorphisms found in the 1000Genomes project (www.1000genomes.org/), in the exome variant server database (evs.gs.washington.edu/), in 50 in-house exomes of controls and in dbSNP (<http://www.ncbi.nlm.nih.gov/projects/SNP/>, Build 132) were excluded.

3. Results

3.1. Genetic analyses

A homozygous missense mutation, c.197C>T, p.Thr66Met in exon 2 of *TREM2* gene (NM_018965.3) has been identified in patients 001 and 025. It was validated by the Sanger method in both patients. This mutation has been previously identified in a family with FTLN (Guerreiro et al., 2013a). Furthermore, homozygous p.Thr66Met mutation was absent from control databases and was predicted to be deleterious by Polyphen (score: 1.0) and MuTaster (*p*-value: 0.947) softwares, thus strongly supporting its causative role in the disease.

3.2. Phenotype of the patients

The patient 001 had no bone disorders. He developed disinhibition, excessive spendings, environmental adherence, stereotypies, and alien limb phenomena at the age of 35 years. Neuropsychological tests revealed predominant frontal syndrome (Table 1). Temporal and spatial disorientation, visuoconstructive deficit with closing-in, reflexive and ideomotor apraxia were also present. Akinetic-rigid parkinsonism, upper limb myoclonus, and tetrapyramidal syndrome were present at the age of 42 years. At that time, brain magnetic resonance imaging (MRI) and ECD-SPECT showed predominant frontal involvement also affecting parietal lobes and hippocampus to a lesser degree. Severe corpus callosum thickness and white matter hypersignals were present (Fig. 1B). Two years later, a severe diffuse cortical atrophy and hypoperfusion were present (Fig. 1C). Epileptic seizures occurred at the age of 44 years. Blood phosphorus and calcium levels were normal. He died at the age of 47 years.

His sib 025 had a left ankle and a right foot fractures secondary to a trauma, but no other history of bone disorders. At the age of 34 years, he developed behavioral disorders, apathy, joviality, familiarity, and coarseness. Neuropsychological tests revealed frontal cognitive syndrome associated with visuoconstructive deficit. Orientation and praxies were normal. Brain MRI revealed frontal and parietal atrophy, associated with remarkable corpus callosum thickness. He died at the age of 49 years. Their parents were neurologically healthy at the age of 74 years.

4. Discussion

We describe two sibs with early onset behavioral variant of FTLN associated with parkinsonism and epilepsy caused by an homozygous *TREM2* mutation. The patients had no severe bone disorders, thus illustrating the variability of bone phenotype that can be moderate or absent in *TREM2* families.

TREM2 protein is mainly expressed in osteoclasts, myeloid cells, and in microglia. It is a transmembrane receptor of the immunoglobulin (Ig) family, consisting of an extracellular Ig-like domain and a cytoplasmic tail, which associates with DAP12 for its signaling function. *TREM2* plays a role in osteoclast differentiation, in the activation of the immune response, and controls phagocytosis by microglia (Turnbull et al., 2006). The functional effect of *TREM2* loss of function mutations in Nasu–Hakola disease and in FTLN is not completely elucidated so far. The p.Thr66Met mutation is located in the Ig domain of the

protein and could abrogate the function of the receptor at the homozygous state, but this hypothesis remains to be confirmed by functional studies.

This study presents 3 main interests. First, it further demonstrates the implication of *TREM2* mutations in FTLN phenotypes with no bone phenotype. Second, the early parietal deficit in both patients and marked parietal and hippocampus involvement on neuroimaging in patient 001 must be underlined, given the role of *TREM2* heterozygous variants as strong genetic risk factor of Alzheimer's disease (Guerreiro et al., 2013c; Pottier et al., 2013). Third, this study and other reports (Giraldo et al., 2013; Guerreiro et al., 2013a, 2013b) highlight the frequency of atypical signs in *TREM2* mutation carriers: epilepsy (75%), parkinsonism (63%), white matter hypersignals (89%), and corpus callosum thickness (89%). Previously, we did not find any mutations in a French cohort of patients with typical FTLN (Lattante et al., 2013). This study demonstrates that *TREM2* mutation screening should be focused on autosomal recessive form of FTLN with atypical phenotype characterized by: (1) a very young age at onset (20–50 years); (2) possible association with early parietal and hippocampal deficits; (3) the presence of seizures and parkinsonism; (4) and suggestive white matter lesions and corpus callosum thickness on brain MRI.

Acknowledgments

This work was funded by the Neuromics FP7 contract E12009DD (to Alexis Brice), the France Alzheimer association contract R12091DD (to Alexis Brice), “The Programme Hospitalier de Recherche Clinique” (PHRC) (to Isabelle Le Ber), and from the program “Investissements d’avenir” ANR-10-IAIHU-06. Anne De Septenville is funded by the program “Investissements d’avenir” ANR-10-IAIHU-06. Dr Paola Caroppo received a PhD Fellowship from Carlo Besta Institute, Milano, Italy. The exome sequencing work was supported in part by the Alzheimer's Research UK (ARUK), by an anonymous donor, by the Wellcome Trust/MRC Joint Call in Neurodegeneration award (WT089698) to the UK Parkinson's Disease Consortium whose members are from the UCL/Institute of Neurology, the University of Sheffield, and the MRC Protein Phosphorylation Unit at the University of Dundee, and by a fellowship from ARUK to Dr Guerreiro. The authors thank Ms. Lydia Guennec, Isabelle Lagroua, Sylvie Forlani, and Christelle Dussert (DNA and cell bank of CR-ICM, Hôpital de la Salpêtrière, Paris) for their excellent technical assistance.

References

- Bianchin MM, Capella HM, Chaves DL, Steindel M, Grisard EC, Ganey GG, da Silva Júnior JP, Neto Evaldo S, Poffo MA, Walz R, Carlotti Júnior CG, Sakamoto AC. Nasu-Hakola disease (polycystic lipomembranous osteodysplasia with sclerosing leukoencephalopathy-PLOSL): a dementia associated with bone cystic lesions. From clinical to genetic and molecular aspects. *Cell Mol. Neurobiol.* 2004; 24:1–24. [PubMed: 15049507]
- Giraldo M, Lopera F, Siniard AL, Corneveaux JJ, Schrauwen I, Carvajal J, Muñoz C, Ramirez-Restrepo M, Gaiteri C, Myers AJ, Caselli RJ, Kosik KS, Reiman EM, Huentelman MJ. Variants in triggering receptor expressed on myeloid cells 2 are associated with both behavioral variant frontotemporal lobar degeneration and Alzheimer's disease. *Neurobiol. Aging.* 2013; 34:2077. [PubMed: 23582655]
- Guerreiro RJ, Lohmann E, Brás JM, Gibbs JR, Rohrer JD, Gurunlian N, Dursun B, Bilgic B, Hanagasi H, Gurvit H, Emre M, Singleton A, Hardy J. Using exome sequencing to reveal mutations in *TREM2* presenting as a frontotemporal dementia-like syndrome without bone involvement. *JAMA Neurol.* 2013a; 70:78–84. [PubMed: 23318515]
- Guerreiro R, Bilgic B, Guven G, Brás J, Rohrer J, Lohmann E, Hanagasi H, Gurvit H, Emre M. A novel compound heterozygous mutation in *TREM2* found in a Turkish frontotemporal dementia-like family. *Neurobiol. Aging.* 2013b; 34:2890. [PubMed: 23870839]
- Guerreiro R, Wojtas A, Bras J, Carrasquillo M, Rogaeva E, Majounie E, Cruchaga C, Sassi C, Kauwe JS, Younkin S, Hazrati L, Collinge J, Pocock J, Lashley T, Williams J, Lambert JC, Amouyel P,

- Goate A, Rademakers R, Morgan K, Powell J, St George-Hyslop P, Singleton A, Hardy J. Alzheimer genetic analysis group. TREM2 variants in Alzheimer's disease. *N. Engl. J. Med.* 2013c; 368:117–127. [PubMed: 23150934]
- Lattante S, Le Ber I, Camuzat A, Dayan S, Godard C, Van Bortel I, De Septenville A, Ciura S, Brice A, Kabashi E. French Research Network on FTD and FTD-ALS, 2013. TREM2 mutations are rare in a French cohort of patients with frontotemporal dementia. *Neurobiol. Aging.* 34:2443. [PubMed: 23759145]
- Pottier C, Wallon D, Rousseau S, Rovelet-Lecrux A, Richard AC, Rollin-Sillaire A, Frebourg T, Campion D, Hannequin D. TREM2 R47H variant as a risk factor for early-onset Alzheimer's disease. *J. Alzheimer's Dis.* 2013; 1:45–49. [PubMed: 23380991]
- Turnbull IR, Gilfillan S, Cella M, Aoshi T, Miller M, Piccio L, Hernandez M, Colonna M. Cutting edge: TREM-2 attenuates macrophage activation. *J. Immunol.* 2006; 177:3520–3524. [PubMed: 16951310]

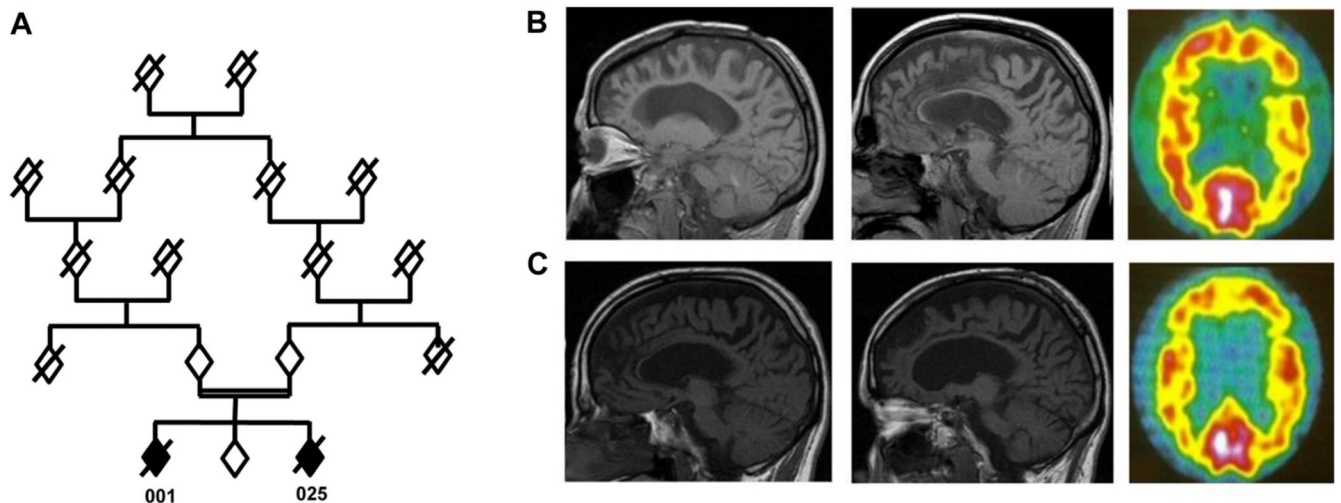


Fig. 1.

(A) Pedigree of the family. Genders are masked for confidentiality. Affected individuals are represented by a black diamond; unaffected individuals are represented by a white diamond. (B) Brain MRI (T1 sagittal) and ECD-SPECT (right) of patient 001 at the age of 42 years. Brain MRI showed marked frontal and parietal atrophy and corpus callosum thickness. ECD-SPECT revealed severe hypoperfusion of frontal and parietal lobes. (C) Brain MRI (T1 sagittal) and ECD SPECT (right) of patient 001 at the age of 44 years. Brain imaging follow-up revealed increased frontal and parietal atrophy (MRI) and hypoperfusion (SPECT). Abbreviations: ECD-SPECT, ^{99m}Tc -ethyl cysteinate dimer-single photon emission computed tomography; MRI, magnetic resonance imaging.

Table 1

Neuropsychological results of patient 001 at the age of 39 and 42 years

Age (y)	39	42
Disease duration (y)	4	7
Mini mental status examination (/30)	12	5
Frontal assessment battery (/18)	ND	1
Mattis dementia rating scale		
Total (/144)	73	20
Attention (/37)	29	11
Initiation (/37)	13	4
Construction (/6)	3	1
Concepts (/39)	17	0
Memory (/25)	11	4
Wisconsin card sorting test		
Number of criteria (/6)	1	0
Visuoconstructive abilities (/5)	2	0
Attention (/15)	6	4

The maximal score of each test is indicated in brackets.

Key: ND, not done.