

## Accepted Manuscript

Acute psychosis presenting as a sole manifestation of left atrial myxoma: A new paradigm

Rajendra Singh Jain M.D, D.M., Kadam Nagpal M.D., Rahul Jain M.D., Swayam Prakash M.D., Rahul Handa M.D.

PII: S0735-6757(14)00325-8  
DOI: doi: [10.1016/j.ajem.2014.05.006](https://doi.org/10.1016/j.ajem.2014.05.006)  
Reference: YAJEM 54289

To appear in: *American Journal of Emergency Medicine*

Received date: 18 April 2014  
Accepted date: 4 May 2014

Please cite this article as: Jain Rajendra Singh, Nagpal Kadam, Jain Rahul, Prakash Swayam, Handa Rahul, Acute psychosis presenting as a sole manifestation of left atrial myxoma: A new paradigm, *American Journal of Emergency Medicine* (2014), doi: [10.1016/j.ajem.2014.05.006](https://doi.org/10.1016/j.ajem.2014.05.006)

This is a PDF file of an unedited manuscript that has been accepted for publication. As a service to our customers we are providing this early version of the manuscript. The manuscript will undergo copyediting, typesetting, and review of the resulting proof before it is published in its final form. Please note that during the production process errors may be discovered which could affect the content, and all legal disclaimers that apply to the journal pertain.



**Type of manuscript:** Case report

**Title of manuscript:** Acute psychosis presenting as a sole manifestation of left atrial myxoma: A new paradigm

**Short Title:** Acute psychosis with left atrial myxoma

**Contributors:**

1. Rajendra Singh Jain, M.D, D.M(Neurology), Professor, Department of Neurology, SMS Medical College, Jaipur, Rajasthan, India
2. Kadam Nagpal ,M.D(Medicine), Resident ,Department of Neurology, SMS Medical College, Jaipur, Rajasthan, India
3. Rahul Jain, M.D(Medicine), Resident ,Department of Neurology, SMS Medical College, Jaipur, Rajasthan, India
- 4.Swayam Prakash,M.D(Medicine), Resident ,Department of Neurology, SMS Medical College, Jaipur, Rajasthan, India
- 5.Rahul Handa M.D(Medicine), Resident ,Department of Neurology, SMS Medical College, Jaipur, Rajasthan, India

Department(s) and institution(s): Department of Neurology, SMS Medical College, Jaipur, Rajasthan, India

**Corresponding author:** Dr Rajendra Singh Jain; drrsjain@yahoo.com

Address of corresponding author: 126,Janakpuri II,Imli Ka Phatak, Jaipur, Rajasthan, India 302005

Phone number:+919414073579

**Co-authors** :Dr Kadam Nagpal; kadamnagpal@gmail.com

Dr Rahul Jain; drrahulneuro@gmail.com

Dr Swayam Prakash; vanswayam@rediffmail.com

Dr Rahul Handa;pratibha\_doc2000@yahoo.co.in

Total number of pages: 9

Total number of words:970

Total number of photographs: 2

Source(s) of support: NIL

Conflicts of interest: NIL

Acknowledgement: NONE

Presentation at meeting: NONE

**Acute psychosis presenting as a sole manifestation of left atrial myxoma: A new paradigm**

**ABSTRACT**

Atrial myxomas are the most common benign cardiac tumors. Neurological manifestations associated with left atrial myxoma are seen infrequently, in form of embolic stroke or intracranial hemorrhage. Psychiatric manifestations are however exceedingly rare. We hereby present a case who presented with acute psychosis as a sole manifestation of an underlying left atrial myxoma.

**INTRODUCTION**

Atrial myxomas being the commonest benign tumor of mesenchymal origin represent roughly 50% of all cardiac tumors, occurring mainly in 3<sup>rd</sup>-6<sup>th</sup> decade of life.<sup>[1]</sup> It is a well described and a treatable cause of stroke. Patients with atrial myxoma present characteristically with a triad of constitutional symptoms (60%), embolic phenomenon (30–40%) and obstructive symptoms (30%).<sup>[2]</sup> Constitutional symptoms include weight loss, fever, arthralgia or Raynaud's phenomenon. Embolic symptoms include stroke, pulmonary or paradoxical embolism. The embolization of thrombotic material covered with tumor cells

occurs in upto 30-45% cases, out of which half of them generally present as an embolic stroke.<sup>[3]</sup> Obstructive symptoms include atrioventricular valve obstruction resulting in tachypnoea, dyspnoea, syncope or sudden cardiac death. Neurological manifestations of atrial myxoma may vary widely ranging from recurrent embolic stroke progressing to multi-infarct dementia, seizures and cerebral haemorrhage. The proposed mechanism for haemorrhagic stroke involves rupture of cerebral aneurysms that results from myxomatous embolization damaging the vessel walls.<sup>[4,5]</sup> Psychiatric manifestations are however seen very infrequently, and further to the best of our knowledge, there has been no mention of acute psychosis as a sole manifestation of left atrial myxoma, which we hereby highlight in our case.

### **CASE REPORT**

A 35 year old female presented with acute onset psychosis of 10 days duration. Patient had anger spells, intense rage, irrelevant talking with delusions, mood changes and was verbally abusive as well. She was hospitalized in a peripheral setup initially, prescribed tranquilizers and was referred thereafter. She was taken over by neurology department and on further enquiry, it was revealed that she also had suffered right hemiparesis with dysarthria 1 year back, from which she

recuperated within 3 weeks. She had no history of recurrent headaches, seizures, fever, vomitings, visual symptoms, palpitation or dyspnea. She was neither taking any drugs nor was she treated for any chronic illnesses in past. Her family history for a similar illness was also unremarkable. On examination, patient was afebrile, normotensive and all peripheral pulses were well palpable. She was conscious but agitated and was talking irrelevantly. She had a tendency to run away from bedside and was difficult to curtail. She was having no apparent focal weakness but her right plantar was extensor. No meningeal signs were present. Curiously, her cardiac examination revealed a loud S1 and 'plop'. All her routine hematological and biochemical parameters and electroencephalograph were normal. Her X-ray chest revealed straightening of left heart border while electrocardiogram was normal. Her thyroid profile, serum ammonia levels, vasculitis markers were normal. Her NCCT head showed hypodensities in right high parietal and left internal capsular regions suggestive of chronic infarcts(Figure 1A). MRI brain with diffusion weighted images showed multiple chronic infarcts in right parietal and left internal capsular region and an acute infarct with restricted diffusion in left periventricular region(Figure 1B&C). Considering the clinical profile with infarcts in multiple vascular territory, a possibility of CNS vasculitis was there. A cerebrospinal fluid examination was

undertaken, which was normal. Subsequently, carotid doppler and CT angiography of brain were also done which were normal(Figure 1D). We confirmed our finding on cardiac examination with a transthoracic echocardiography which interestingly revealed a pedunculated left atrial mass (Figure 2A)attached to interatrial septum prolapsing through mitral valve with an ejection fraction of 55%. Subsequently,excision of left atrial mass was done under cardiopulmonary bypass and was subjected to biopsy. Interestingly, the biopsy was suggestive of atrial myxoma(Figure 2B). Patient showed a dramatic recovery in her psychosis following the surgery and did well on anticoagulants which were titrated as per prothrombin time and antiplatelets during follow-up visits. There was no recurrence of a stroke like episode or any behavioral change.

## **DISCUSSION**

Atrial myxomas may remain asymptomatic in 10-20% of cases and can be only found as an incidental finding on echocardiography. Further auscultation abnormalities may be absent in upto 36% of cases<sup>[6]</sup> and overall neurological complications may be seen in 26- 45% of cases; out of which only 0.5% of cases present with ischemic stroke.<sup>[7]</sup> Our patient did not have any cardiac symptoms

whatsoever, but auscultation findings guided us to the diagnosis, which was later proved by echocardiography and subsequently confirmed by tissue diagnosis. There has been a mention only in the report by Ekinci and Donnan et al where they reported that psychiatric manifestations such as acute confusional states, chronic cognitive impairment or behavioral abnormalities were seen in around 23% of the cases.<sup>[8]</sup> However, acute psychosis as a sole presenting feature has never been described to the best of our knowledge. Differentiating it from other disorders such as infections of central nervous system, CNS vasculitis, reversible cerebral vasoconstriction syndrome or toxin exposure is prudent. Investigational techniques such as preferably trans-esophageal echocardiography combined with neuroimaging is essential to diagnose left atrial myxoma in case of clinical suspicion. Surgery in such cases should not be delayed, even if patients are asymptomatic because a complication of systemic embolisation is always there. Neurological sequelae after resection is rare, but recurrences of myxoma have been reported in various reports.<sup>[9]</sup> Our patient however, has been on regular follow-up for three years and repeated echocardiography studies have been normal and there has been no deterioration in her neurological status either. Otherwise, annual review to detect for myxoma recurrence is advised upto 3-4 years during which the risk is greatest.<sup>[10]</sup>



Psychiatric manifestations as presenting feature can always pose a challenge for the treating clinician, masquerading the underlying illness. A thorough clinical examination is of paramount importance, even if the presenting manifestation is primarily a psychiatric symptom, as it may herald to an occult disorder in its incipient stage with grave implications.

#### **REFERENCES:**

1. Reynen Klaus. Cardiac myxomas. New England Journal of Medicine . 1995;333 (24):1610-1617.
2. McCarthy PM, Piehler JM, Schaff HV, Pluth JR, Orszulak TA, Vidaillet Jr HJ et al. The significance of multiple, recurrent, and " complex" cardiac myxomas. The Journal of thoracic and cardiovascular surgery 1986;91(3):389-396.
3. Pinede L, Duhaut P, Loire R. Clinical presentation of left atrial cardiac myxoma: a series of 112 consecutive cases. Medicine(Baltimore) 2001;80(3):159-172.

4. Damasio H, Seabra-Gomes R, Da Silva JP, Damasio AR, Antunes JL. Multiple cerebral aneurysms and cardiac myxoma. *Archives of Neurology* 1975;32(4):269.
5. Herbst M, Wattjes MP, Urbach H, Inhetvin-Hutter C, Becker D, Klockgether T et al. Cerebral embolism from left atrial myxoma leading to cerebral and retinal aneurysms: a case report. *American journal of neuroradiology* 2005;26(3):666-669.
6. O'Rourke F, Dean N, Mouradian MS, Akhtar N, Shuaib A. Atrial myxoma as a cause of stroke: case report and discussion. *Canadian Medical Association Journal* 2003;169(10):1049-1051.
7. Knepper LE, Biller J, Adams HP, Bruno A. Neurologic manifestations of atrial myxoma. A 12-year experience and review. *Stroke* 1988;19(11):1435-1440.
8. Ekinci EI, Donnan GA. Neurological manifestations of cardiac myxoma: a review of the literature and report of cases. *Internal medicine journal* 2004;34(5):243-249.

9. Desousa AL, Muller J, Campbell RL, Batnitzky S, Rankin L. Atrial myxoma: a review of the neurological complications, metastases, and recurrences. *Journal of Neurology, Neurosurgery & Psychiatry* 1978;41(12):1119-1124.
10. Semb BKH. Surgical considerations in the treatment of cardiac myxoma. *Journal of thoracic and cardiovascular surgery* 1984;87(2):251-259.

**Legends:**

Figure 1A: Non contrast CT head showing hypodensities in left caudate, globus pallidus and right temporo-parietal cortex suggestive of chronic infarcts.

Figure 1B: MRI brain showing multiple hyperintense signals in left thalamus, left caudate and right internal capsular region suggestive of chronic infarcts.

Figure 1C: Diffusion weighted image showing hyperintense signals in left periventricular region suggestive of acute infarct(Black arrow).

Figure 1 D: Normal intracranial CT angiography of the patient.

Figure 2A: 2-D echocardiography showing a pedunculated left atrial mass attached to interatrial septum prolapsing through mitral valve.

Figure 2B: High magnification histopathology section showing elongated fusiform cells in an abundant myxoid background suggestive of atrial myxoma.

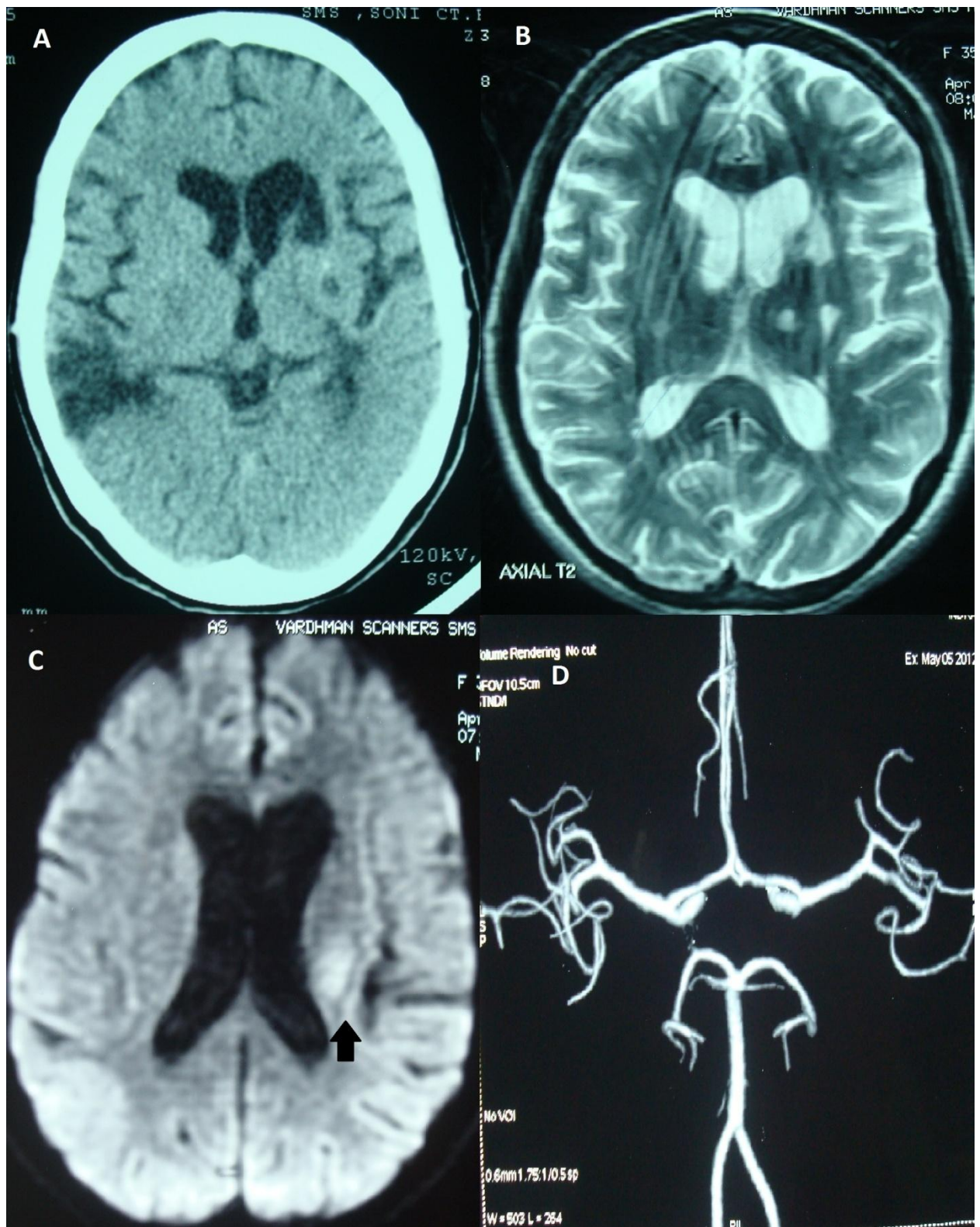


Fig. 1

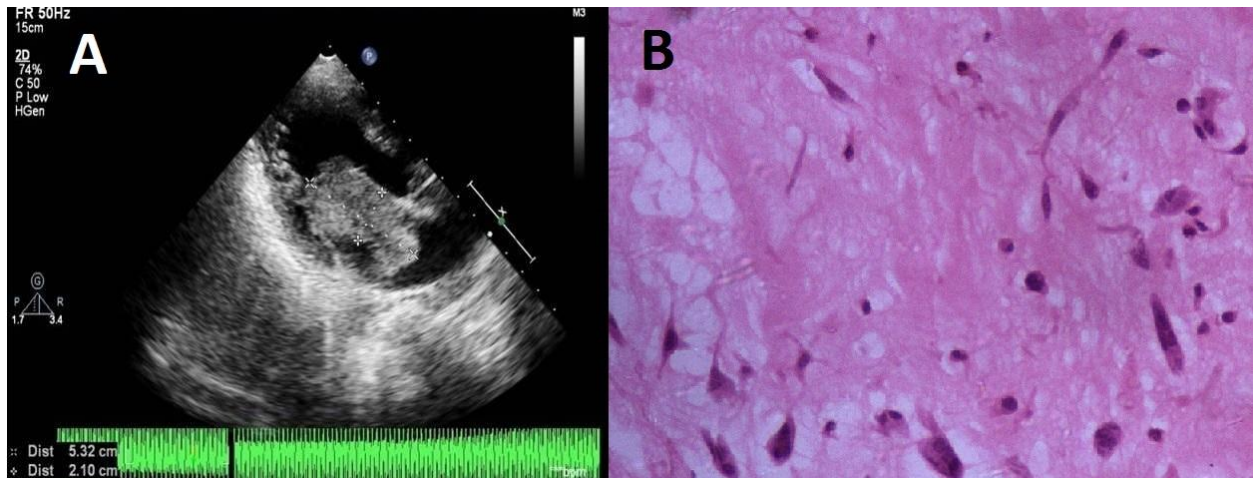


Fig. 2