

Accepted Manuscript



Posterior Cerebral artery stroke presenting as Alexia without Agraphia

Bhawna Sharma DM, Rahul Handa MD, Swayam Prakash MD, Kadam Nagpal MD, Indu Bhana MD, Pankaj Kumar Gupta MD, Sunil Kumar MD, Mahendra Singh Sisodiya

PII: S0735-6757(14)00312-X
DOI: doi: [10.1016/j.ajem.2014.04.046](https://doi.org/10.1016/j.ajem.2014.04.046)
Reference: YAJEM 54276

To appear in: *American Journal of Emergency Medicine*

Received date: 15 April 2014
Accepted date: 18 April 2014

Please cite this article as: Sharma Bhawna, Handa Rahul, Prakash Swayam, Nagpal Kadam, Bhana Indu, Gupta Pankaj Kumar, Kumar Sunil, Sisodiya Mahendra Singh, Posterior Cerebral artery stroke presenting as Alexia without Agraphia, *American Journal of Emergency Medicine* (2014), doi: [10.1016/j.ajem.2014.04.046](https://doi.org/10.1016/j.ajem.2014.04.046)

This is a PDF file of an unedited manuscript that has been accepted for publication. As a service to our customers we are providing this early version of the manuscript. The manuscript will undergo copyediting, typesetting, and review of the resulting proof before it is published in its final form. Please note that during the production process errors may be discovered which could affect the content, and all legal disclaimers that apply to the journal pertain.

Title page**1. Case report**

2. **Title:** Posterior Cerebral artery stroke presenting as Alexia without Agraphia

3. **Short title:** Alexia without Agraphia

4. **Department and institution where work was performed:** Neurology Department, SMS Medical College, Jaipur, Rajasthan, India.

5. **Authors:**

Bhawna Sharma, DM Neurology, Professor, Department of Neurology, SMS Medical College, Jaipur, Rajasthan

Rahul Handa, MD Medicine, Senior Resident, Department of Neurology, SMS Medical College, Jaipur, Rajasthan

Swayam Prakash, MD Medicine, Senior Resident, Department of Neurology, SMS Medical College, Jaipur, Rajasthan

Kadam Nagpal, MD Medicine, Senior Resident, Department of Neurology, SMS Medical College, Jaipur, Rajasthan

Indu Bhana, MD Medicine, Senior Resident, Department of Neurology, SMS Medical College, Jaipur, Rajasthan

Pankaj Kumar Gupta, MD Medicine, Senior Resident, Department of Neurology, SMS Medical College, Jaipur, Rajasthan

Sunil Kumar: MD Medicine, Senior Resident, Department of Neurology, SMS Medical College, Jaipur, Rajasthan

Mahendra Singh Sisodiya, Senior Resident, Department of Neurology, SMS Medical College, Jaipur, Rajasthan

6. **Corresponding author:** Dr Rahul Handa, Address: Department of Neurology, SMS Medical College, Jaipur, Rajasthan, India; Phone number: +918696363322
e-mail: rahulhanda0411@gmail.com
7. No grant was available for this case.
8. No author has any conflict of interest

Abstract:

Alexia without agraphia (pure alexia) was the first of the disconnection syndromes to be described by Dejerine who reported a patient of alexia without agraphia secondary to an embolic occipital lobe infarct. We herein report a 55-years-old male who presented with alexia without agraphia with magnetic resonance imaging suggestive of left posterior cerebral artery infarct involving left occipital lobe and splenium of corpus callosum. Alexia without agraphia is a relatively uncommon clinical condition which should always be thought in a patient presenting with difficulty in reading with normal visual acuity. Ophthalmologists should also be aware of this disconnection syndrome as many patients initially take their advice due to predominant visual complaints. Early diagnosis and treatment of this condition helps in ensuring the patient and attendants about non-progressive nature of the disease, and may prevent further episodes of stroke.

Introduction

Alexia is an acquired loss of reading ability in a literate person secondary to brain lesion in left occipital lobe and adjacent splenium which disconnects visual input from language area [1]. Alexia without agraphia (pure alexia) was the first of the disconnection syndromes to be described by Dejerine who reported a patient of alexia without agraphia secondary to an embolic occipital lobe infarct [2]. We herein report a 55-years-old male who presented with alexia without agraphia with magnetic resonance imaging (MRI) suggestive of left posterior cerebral artery (PCA) infarct involving left occipital lobe and splenium of corpus callosum (CC).

Case report

A 55-years-old right handed male, graduate presented with three months history of sudden onset non-progressive difficulty in reading newspaper and in operating ATM machine as he was not able to understand the instructions which were displayed on the screen. Patient's attendants initially thought of refractory error and took multiple ophthalmological consultations but vision was found to be normal. Thus, the patient was referred to the Neurology department of our medical college hospital for further management.

On examination, the patient was conscious and oriented to time, place, and person. His general physical examination was normal. His cardiovascular, gastrointestinal and respiratory system examination was normal. Neurological examination revealed right homonymous hemianopia. Language testing revealed normal fluency, comprehension,

and repetition. The patient was asked to read letters/characters which he read successfully but he was unable to pronounce words. Thus his reading comprehension was found to be impaired. When patient was asked to write about his problems he wrote that, "I am able to write but unable to read". He was unable to read even what he wrote himself. Thus, a final diagnosis of alexia without agraphia with right homonymous hemianopia was kept and the patient was advised MRI brain which revealed left PCA infarct involving left occipital lobe and splenium of CC (Figure 1A, 1B, 2A and 2B).

Patient's blood sugar (fasting and post prandial), lipid profile, renal function and liver function tests were within normal range. Carotid artery Doppler and trans-thoracic echocardiography were normal. Patient was advised CT angiography of neck and brain vessels but due to financial constraints was denied by the patient. Patient was managed conservatively with antiplatelet and atorvastatin with regular monitoring of blood pressure (BP) and blood sugar and was advised good compliance.

Discussion

Alexia without agraphia was first described by Dejerine in 1892 followed by Geschwing. They reported an interesting situation in which patients were able to write but were unable to read what they wrote themselves. These patients had stroke with right homonymous hemianopia with or without other neurological deficits [3]. The pathways involved in this syndrome are believed to be localized to the inferior portion of the splenium of the CC on the side of dominant cerebral hemisphere [4]. Both the occipital lobe and splenium are supplied by PCA. Since splenium connects two occipital lobes across the midline, splenial infarction blocks all the visual stimuli traversing the midline to reach the angular gyrus of the dominant hemisphere which is the visual word form area, important for word recognition [3,1]. Information from left side of visual field which is received by right visual cortex in right occipital lobe must be transferred to the angular gyrus in the left hemisphere (dominant hemisphere) [1]. Since this transfer is through splenium of CC, infarction of splenium leads to its interruption. These patients do not have difficulty in writing as writing depends on intact angular gyrus which is supplied by MCA and does not depend on intactness of splenium of CC [3].

Alexia without agraphia usually occurs in patients with infarction of left PCA territory, but other causes include Toxoplasma encephalitis, ring enhancing lesions in left posterior white matter, temporal lobe lesions due to herpes encephalitis, mitochondrial myopathy with lactic acidosis and acute demyelinating encephalomyelitis [5,6,7,8].

Our patient had sudden onset non-progressive alexia without agraphia with right homonymous hemianopia with MRI suggestive of left PCA territory infarct involving left occipital lobe and splenium of corpus callosum.

Conclusion:

Alexia without agraphia is a relatively uncommon clinical condition which should always be thought in a patient presenting with difficulty in reading with normal visual acuity. Ophthalmologists should also be aware of this disconnection syndrome as many patients initially take their advice due to predominant visual complaints. Early diagnosis and treatment helps in ensuring the patient and attendants about non-progressive nature of the disease, and may prevent further episodes of stroke.

References:

1. Verma A, Singh NN, Misra S. Transitory alexia without agraphia: a disconnection syndrome due to neurocysticercosis. *Neurol India*. 2004 Sep;52(3):378-9.
2. Mulroy E, Murphy S, Lynch T. Alexia without agraphia. *Ir Med J*. 2011 Apr;104(4):124.
3. DGC. Alexia Without Agraphia, and the Splenium. 1965;73(1):2-3.
4. Quint DJ, Gilmore JL. Alexia without agraphia. *Neuroradiology*. 1992;34(3):210-4.
5. Lüscher C, Horber FF. Transitory alexia without agraphia in an HIV-positive patient suffering from toxoplasma encephalitis: a case report. *Eur Neurol*. 1992;32(1):26-7.
6. Erdem S1, Kansu T. Alexia without either agraphia or hemianopia in temporal lobe lesion due to herpes simplex encephalitis. *J Neuroophthalmol*. 1995 Jun;15(2):102-4.
7. Skoglund RR. Reversible alexia, mitochondrial myopathy, and lactic acidemia. *Neurology*. 1979 May;29(5):717-20.
8. Little RD, Goldstein JL. Alexia without agraphia in a child with acute disseminated encephalomyelitis. *Neurology*. 2006 Aug 22;67(4):725.

Legends:

Figure 1A and 1B: MRI Brain T1W images showing hypointensity in left occipital lobe and splenium of corpus callosum suggestive of left PCA territory infarct.

Figure 2A and 2B: MRI Brain T2W images showing hyperintensity in left occipital lobe and splenium of corpus callosum suggestive of left PCA territory infarct.

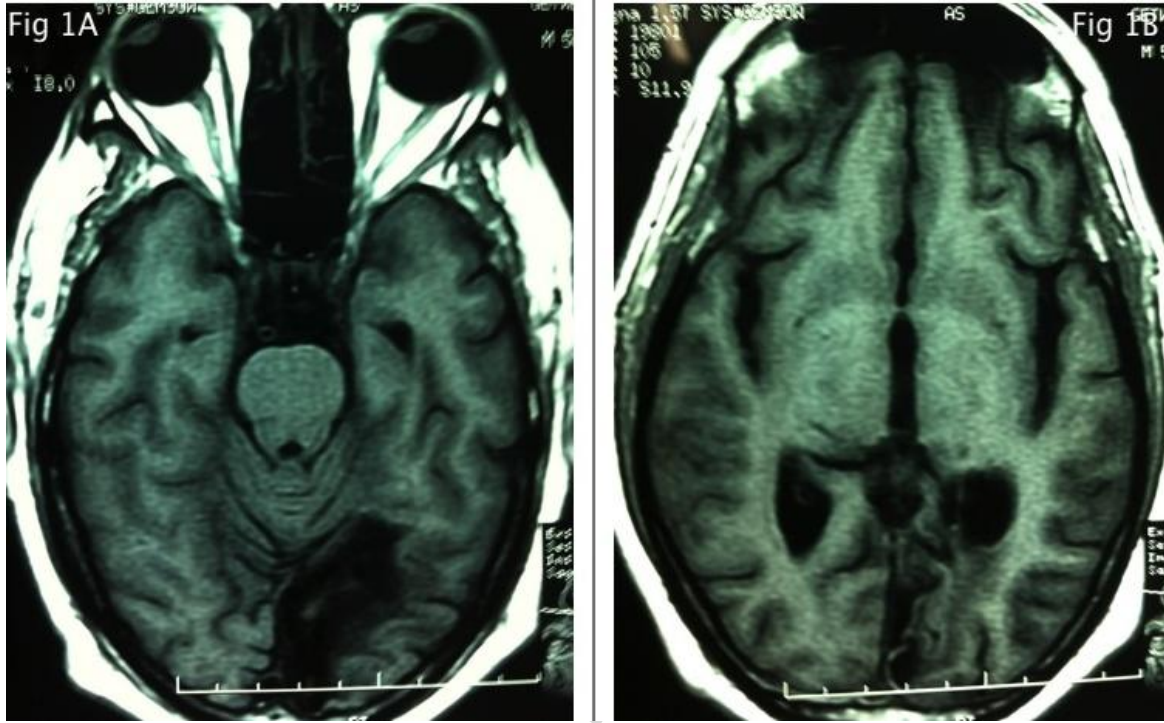


Fig. 1

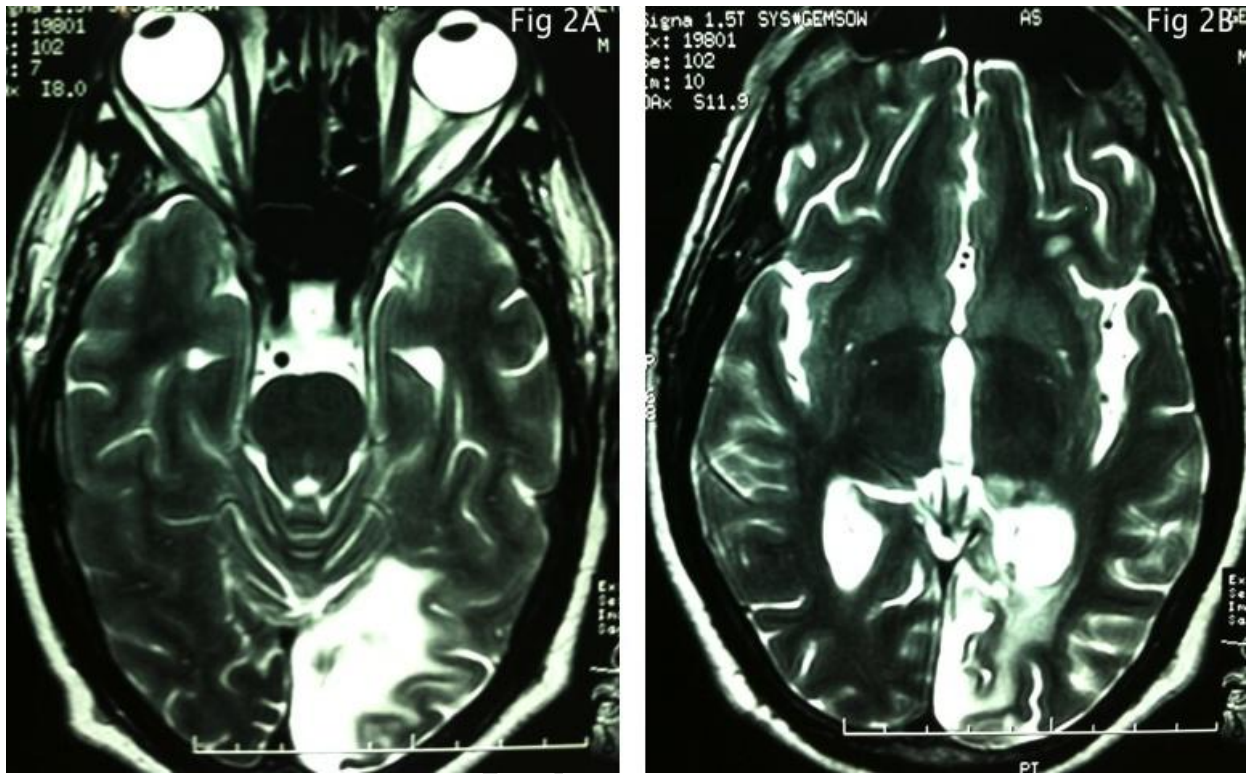


Fig. 2

ACCEPTED