

Fetal intracranial hemorrhage related to maternal autoimmune thrombocytopenic purpura

Mehmet Serdar Kutuk · Laure Croisille ·
Sureyya Burcu Gorkem · Ebru Yilmaz ·
Levent Korkmaz · Philippe Bierling · Ekrem Unal

Received: 13 June 2014 / Accepted: 13 June 2014
© Springer-Verlag Berlin Heidelberg 2014

Abstract

Background Maternal autoimmune thrombocytopenic purpura (AITP) can cause fetal intracranial hemorrhage.

Case report A 19-year-old primigravida was referred to our institution for prenatally detected ventriculomegaly at 30th week of gestation. Her personal and family histories were unremarkable. Her platelet count was $54 \times 10^9/L$. Fetal neurosonography showed intraparenchymal hemorrhage. AITP was diagnosed in the mother and platelet count decreased at $34 \times 10^9/L$. Patient was treated with methylprednisolone and intravenous immunoglobulin. She delivered a 2,340-g infant at 37 weeks with elective cesarean section. The platelet count of the newborn was $181 \times 10^9/L$ and

coagulation tests were normal. No antiplatelet specific antibodies were detected in cord blood. Postnatal MRI evaluation confirmed grade IV intracranial hemorrhage. The newborn baby has suffered from mild spasticity and seizures.

Conclusions Clinicians must be vigilant about the catastrophic fetal complications of maternal AITP; a close follow-up with a multidisciplinary cooperation between obstetricians, hematologists, and neonatologists must be warranted.

Keywords Intracranial hemorrhage · Prenatal diagnosis · Thrombocytopenia

The abstract of this paper was submitted as poster presentation for the 24th World Congress on Ultrasound in Obstetrics and Gynecology that will be held in Barcelona, Spain on 14–17 September 2014.

M. S. Kutuk

Division of Perinatology, Faculty of Medicine, Department of Obstetrics and Gynecology, Erciyes University, Kayseri, Turkey

L. Croisille · P. Bierling

Etablissement Francais du Sang (EFS-Ile-de-France), Hopital Henri Mondor, Inserm U955, Creteil, France

S. B. Gorkem

Faculty of Medicine, Department of Radiology, Division of Pediatric Radiology, Erciyes University, Kayseri, Turkey

E. Yilmaz · E. Unal (✉)

Faculty of Medicine Department of Pediatrics, Division of Pediatric Hematology and Oncology, Erciyes University, Kayseri, Turkey
e-mail: drekremunal@yahoo.com.tr

E. Unal

e-mail: ekremunal@erciyes.edu.tr

L. Korkmaz

Faculty of Medicine, Department of Pediatrics, Division of Neonatology, Erciyes University, Kayseri, Turkey

Introduction

Intracranial hemorrhage (ICH) refers to hemorrhage anywhere within the cranium and is most commonly identified prenatally as intraventricular hemorrhage [2, 13]. The incidence of fetal ICH is unclear, although an estimate of 0.46 per 1,000 deliveries and 0.9 per 1,000 pregnancies has been reported [2, 11]. Predisposing factors of fetal ICH include fetal coagulation disorders, thrombocytopenia, maternal trauma, hereditary coagulation factor deficiency, and genetic disorders [12, 15]. However, the exact cause cannot be explained in half of the cases [2, 15]. Fetal thrombocytopenias, including those due to maternal autoimmune thrombocytopenic purpura (AITP) and fetal and neonatal alloimmune thrombocytopenia (FNAIT), can cause neonatal ICH. Contrasting to severe FNAIT, a predictable cause of ICH, the fetal ICH secondary to AITP is exceptional, and few cases have been reported [8, 9, 20, 21].

Herein, we report a case of prenatally diagnosed fetal ICH secondary to maternal AITP, and review of the related literature.

Case report

A 19-year-old primigravida was referred to our institution for fetal ventriculomegaly, and intracranial lesion suspicious for ICH at 30th gestational week. She had no history of trauma, bleeding disorders, or drug use. Initial screening ultrasonography (US) at 20th week was normal. Laboratory tests for perinatal infections were negative. Total blood count showed a platelet count at $54 \times 10^9/L$, hemoglobin at 11 g/L, and white blood cell (WBC) at $12 \times 10^9/L$. Fetal US at 30th week showed a single, viable fetus concordant with its week at breech presentation. On neurosonography, a hyperechoic mass with a size of 16×19 mm located at the left periventricular parietal lobe, suggestive of intraparenchymal hemorrhage was demonstrated (Fig. 1a). Hydrocephaly resulting from dilatation of bilateral lateral, third and fourth ventricles, and cisterna magna was observed. The inner walls of all ventricles were seemed to be thickened with an increased echogenicity (Fig. 1b). Uteroplacental Doppler US of fetal and maternal vessels was normal. Fetal nonstress test was nonreactive. Fetal magnetic resonance imaging revealed the left frontoparietal hemorrhage extending into dilated lateral ventricle (grade IV) with tetra-ventricular hydrocephaly (Fig. 2).

The patient was sent to the hematology clinic for thrombocytopenia evaluation, and AITP was diagnosed. Since her platelet count decreased to $30 \times 10^9/L$, methylprednisolone (1 g/kg) and intravenous immunoglobulin (IVIG) (1 g/kg) were administered. Her platelet count progressively reached up to $130 \times 10^9/L$ at the seventh day of treatment. Her treatment was discontinued, and platelets count remained between $120 \times 10^9/L$ and $137 \times 10^9/L$ without additional treatment. Her antenatal follow-up was uneventful, albeit fetal hydrocephaly, and cortical thinning progressed. At 37th gestational week, she gave birth to a 2,340-g boy with APGAR scores of 8 and 10 at the first and fifth minutes, respectively, with elective cesarean section. Aside from bulging fontanel, physical examination of the infant was unremarkable. The platelet count of the newborn at birth was $181 \times 10^9/L$. WBC and hemoglobin were $9.26 \times 10^9/L$ and 148 g/L, respectively. The direct

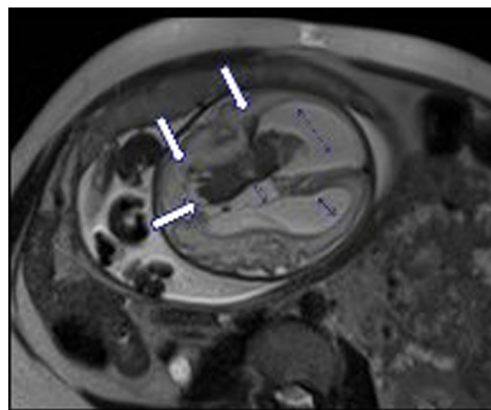


Fig. 2 T2-W HASTE axial image at 30 gestational weeks shows hypointense parenchymal hemorrhage on the left frontoparietal white matter and intraventricular hemorrhage (arrows) in the left lateral ventricle with hydrocephaly (small arrows)

Coombs test was negative. Peripheral blood smear showed normal leukocyte differentiation. The prothrombin time, activated partial thromboplastin time, in vitro bleeding time with PFA-100, and factor XIII levels were within normal limits. No antiplatelet antibodies including antiplatelet auto antibodies and alloantibodies were detected in cord blood. In addition, human platelet antigen (HPA) genotype studies in parents showed that the mother's platelets were HPA-1aa/HPA-3bb/HPA-5 aa/HPA-15bb, and the father's platelets were HPA-1aa/HPA-3ab/HPA-5 aa/HPA-15aa. Therefore, the fetus had 50 % risk to be HPA-3 incompatible and 100 % risk to be HPA-15 incompatible with its mother. Nevertheless, no HPA-3 or HPA-15 alloantibodies were identified in maternal serum 2 weeks after delivery and 1.5 months later. Postnatal MRI examination confirmed the prenatal diagnosis by showing left frontoparietal grade IV hemorrhage with hydrocephaly (Fig. 3).

One-month-old baby underwent a ventriculoperitoneal shunt operation due to worsening symptoms of hydrocephaly. The patient had mild spasticity and seizures on neurological examination with abnormalities on electroencephalogram. He was treated with antiepileptic drugs. The maternal platelet

Fig. 1 **a** Transabdominal US of the 30-week fetus shows hyperechoic intraparenchymal hemorrhage at left frontoparietal region on coronal image. **b** Transabdominal US of the 30-week fetus shows bilateral lateral and third ventricular dilation and hyperechoic subependymal areas. The arrow indicates blood clot in the third ventricle

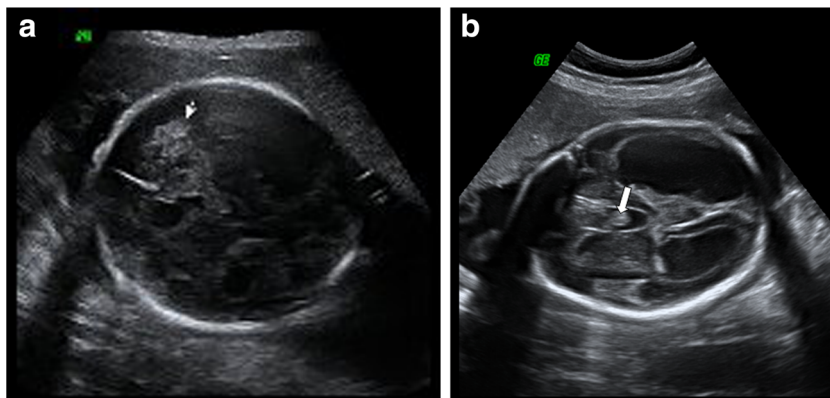
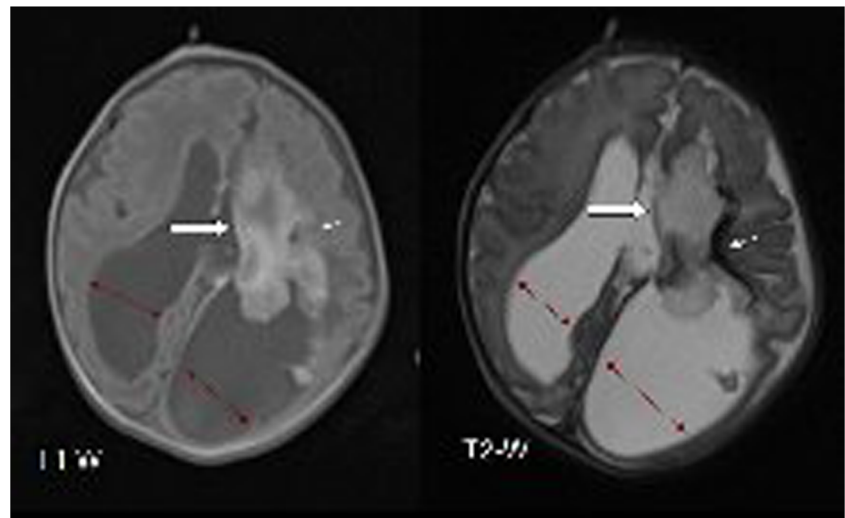


Fig. 3 Postnatal brain MRI of 1-day-old boy: grade IV hemorrhage is shown with late subacute intraventricular hemorrhage (white arrows) with hydrocephaly (black arrows) which is hyperintense on T1-W and hypointense on T2-W axial image with chronic parenchymal hemorrhage on left frontoparietal periventricular region (small arrows)



counts at postpartum varied between $119 \times 10^9/L$ and $149 \times 10^9/L$.

Discussion

Mild thrombocytopenia which is a common problem during pregnancy has been reported many harmful effects on both mother and fetus [4]. The main goal of managing thrombocytopenia during pregnancy is to make an accurate differential diagnosis between gestational thrombocytopenia and other etiological factors including AITP, preeclampsia, and systemic lupus erythematosus. Gestational thrombocytopenia is the most common anomaly which accounts for 70–80 % of the cases of thrombocytopenia during pregnancy [19]. It generally occurs in the mid-second to the third trimester, with an unclear pathogenesis. No confirmatory laboratory tests are available, and the diagnosis is one of exclusion [4]. It has been postulated that the diagnosis of gestational thrombocytopenia is unlikely when the platelet count is lower than $50 \times 10^9/L$ [4].

AITP is a relatively common autoimmune disease among women of child-bearing age and is characterized by a low platelet count and minor bleeding disorder at an estimated frequency of 1–10 of every 10,000 pregnancies [1]. AITP is caused by IgG antiplatelet autoantibodies that recognize platelet membrane glycoproteins. During pregnancy, maternal antiplatelet antibodies can cross the placenta and induce fetal and neonatal thrombocytopenia [1]. Clinical experience regarding fetal/neonatal ICH associated with AITP has largely been derived from neonatal series. Payne et al. [16] reviewed six previously reported cases of neonatal ICH in pregnancy complicated by AITP, and Gill and Kelton [5] also reviewed 11 cases. Total of 22 neonatal ICH cases with maternal ITP had been previously reported. The overall incidence of neonatal ICH in infants of mother with AITP is reported in the range of 0 to 2.9 % [3]. Neonatal ICH secondary to maternal AITP

generally occurs after the second day of life when the platelet count reaches its nadir. This suggests that the incidence of ICH occurring in utero seems to be extremely low. Although, catastrophic ICH may be rarely observed, there is no maternal serological test and clinical features that can reliably predict neonatal counts [10]. Koyama et al. [10] analyzed a total of 127 pregnancies in 88 women with AITP and found that the only strong predictor of FNAIT is the occurrence of FNAIT with previous sibling.

The fetal ICH secondary to maternal AITP is an extremely rare event. One of the documented cases has been reported recently by Koyama et al. [9] in a 38-year-old woman. Rios et al. [18] describe a case of prenatally diagnosed subdural hematoma in pregnant woman with a hidden maternal autoimmune thrombocytopenia. In Koyama's report, despite intravenous immunoglobulin and steroid treatment, the infant had severe thrombocytopenia ($9 \times 10^9/L$). Similarly, the infant presented in the Rios et al.'s publication had severe thrombocytopenia and widespread purpura [18]. In contrast, the platelet count of the infant in our case was normal at birth and thereafter. This observation probably reflects unpredictable response of fetal platelet count to maternal IVIG therapy. IVIG can cross the placenta and interact with fetal antibodies, and Fc receptors on the placental surface [14, 17]. Kaplan et al. [7] evaluated the effect of IVIG on fetal platelet count and found no benefit. In contrast, Howman et al. [6] reported a case of AITP with an affected infant successfully treated with weekly intravenous immunoglobulin. Despite the encouraging results with IVIG in fetus with alloimmune thrombocytopenia with a near 100 % success rate, the role of the therapy in AITP for preventing ICH is yet to be determined.

The presented case seems to be misdiagnosed as gestational thrombocytopenia before referring to us. There was no evidence for a diagnosis of anti-HPA alloimmunization according to laboratory results, since no antiplatelet alloantibodies were identified in maternal serum 2 weeks after delivery and

1.5 months later, despite possible HPA-3 and HPA-15 incompatibilities (both system being known for their possible association with severe FNAIT). Nevertheless, such negative results cannot totally exclude this differential diagnosis although this would not explain the mother's thrombocytopenia.

The antenatal management of fetus suspicious of having AITP-induced thrombocytopenia is not well established. Since the determination of fetal platelet levels with umbilical cord sampling is discouraged due to the fact that risk of procedure outweighs the benefits; the effect of maternal treatment on the fetal platelet levels remains speculative. As mentioned before, the role of corticosteroids and IVIG in increasing fetal platelet count is inconclusive. As our case implied, maternal administration of IVIG may have salutary effect, since it increases both maternal and fetal platelet count. Evidence for a protective effect of caesarean section reducing the risk of ICH is lacking. However, in women with a previous child with an ICH, elective caesarean section at near term is usually offered.

As a conclusion clinicians must be vigilant about the catastrophic fetal complications of maternal AITP; a close follow-up with a multidisciplinary cooperation between obstetricians, hematologists, and neonatologists must be warranted.

References

1. ACOG practice bulletin: thrombocytopenia in pregnancy. Number 6, September 1999. Clinical management guidelines for obstetrician-gynecologists. American College of Obstetricians and Gynecologists. *Int J Gynaecol Obstet.* 1999 67:117-28
2. Elchalal U, Yagel S, Gomori JM et al (2005) Fetal intracranial hemorrhage [fetal stroke]: does grade matter? *Ultrasound Obstet Gynecol* 26:233-243
3. Fujimura K, Harada Y, Fujimoto T, Kuramoto A, Ikeda Y, Akatsuka J, Dan K, Omine M, Mizoguchi H (2002) Nationwide study of idiopathic thrombocytopenic purpura in pregnant women and the clinical influence on neonates. *Int J Hematol* 75:426-433
4. Gernsheimer T, James AH, Stasi R (2013) How I treat thrombocytopenia in pregnancy. *Blood* 121:38-47
5. Gill KK, Kelton JG (2000) Management of idiopathic thrombocytopenic purpura in pregnancy. *Semin Hematol* 37:275-289
6. Howman RA, Barr AL, Shand AW, Dickinson JE (2009) Antenatal intravenous immunoglobulin in chronic immune thrombocytopenic purpura: case report and literature review. *Fetal Diagn Ther* 25:93-97
7. Kaplan C (2001) Immune thrombocytopenia in the fetus and the newborn: diagnosis and therapy. *Transfus Clin Biol* 8:311-314
8. Kim MW, Choi HM (2006) Fetal hydrocephalus in a pregnancy complicated by idiopathic thrombocytopenic purpura. *J Ultrasound Med* 25:777-780
9. Koyama S, Tomimatsu T, Kanagawa T, Kumasawa K, Tsutsui T, Kimura T (2012) Reliable predictors of neonatal immune thrombocytopenia in pregnant women with idiopathic thrombocytopenic purpura. *Am J Hematol* 87:15-21
10. Koyama S, Tomimatsu T, Sawada K, Kanagawa T, Isobe A, Taniguchi Y, Wada T, Kimura T, Arahori H, Kitabatake Y, Wada K (2010) Prenatal diagnosis of fetal intracranial hemorrhage in pregnancy complicated by idiopathic thrombocytopenic purpura. *Prenat Diagn* 30:489-491
11. Kutuk MS, Yikilmaz A, Ozgun MT, Dolanbay M, Canpolat M, Uludag S, Uysal G, Tas M, Musa K (2014) Prenatal diagnosis and postnatal outcome of fetal intracranial hemorrhage. *Childs Nerv Syst* 30:411-418
12. Kutuk MS, Balta B, Koder H, Matsumoto N, Saito H, Doganay S, Canpolat M, Dolanbay M, Unal E, Dundar M (2014) Is there relation between COL4A1/A2 mutations and antenatally detected fetal intraventricular hemorrhage? *Childs Nerv Syst* 30:419-424
13. Lynch JK, Hirtz DG, DeVeber G, Nelson KB (2002) Report of the National Institute of Neurological Disorders and Stroke workshop on perinatal and childhood stroke. *Pediatrics* 109:116-123
14. Ni H, Chen P, Spring CM, Sayeh E, Semple JW, Lazarus AH, Hynes RO, Freedman J (2006) A novel murine model of fetal and neonatal alloimmune thrombocytopenia: response to intravenous IgG therapy. *Blood* 107:2976-2983
15. Patisroglu T, Ozdemir MA, Unal E, Altuner Torun Y, Coskun A, Menku A, Mutlu FT, Karakukcu M (2011) Intracranial hemorrhage in children with congenital factor deficiencies. *Childs Nerv Syst* 27:1963-1966
16. Payne SD, Resnik R, Moore TR, Hedriana HL, Kelly TF (1997) Maternal characteristics and risk of severe neonatal thrombocytopenia and intracranial hemorrhage in pregnancies complicated by autoimmune thrombocytopenia. *Am J Obstet Gynecol* 177:149-155
17. Radder CM, Roelen DL, van de Meer-Prins EM et al (2004) The immunologic profile of infants born after maternal immunoglobulin treatment and intrauterine platelet transfusions for fetal/neonatal alloimmune thrombocytopenia. *Am J Obstet Gynecol* 191:815-820
18. Rios LT, AraujoJúnior E, Nardozza LM et al (2012) Hidden maternal autoimmune thrombocytopenia complicated by fetal subdural hematoma-case report and review of the literature. *Childs Nerv Syst* 28:1113-1116
19. Sainio S, Kekomaki R, Riikonen S, Teramo K (2000) Maternal thrombocytopenia at term: a population-based study. *Acta Obstet Gynecol Scand* 79:744-749
20. Tampakoudis P, Bili H, Lazaridis E et al (1995) Prenatal diagnosis of intracranial hemorrhage secondary to maternal idiopathic thrombocytopenic purpura: a case report. *Am J Prenat* 12:268-270
21. Weber KE, Mittal R, Sigouin C et al (2003) A retrospective 11-year analysis of obstetric patients with idiopathic thrombocytopenic purpura. *Blood* 102:4306-4311