

## Case report

## Pure word deafness after resection of a Vein of Galen aneurysm and arteriovenous malformation: Report of a case

David Bervini <sup>a,b,\*</sup>, Vincent Oxenham <sup>a,c,d</sup>, Michael Kerin Morgan <sup>a</sup><sup>a</sup> Australian School of Advanced Medicine, Macquarie University, Sydney, NSW, Australia<sup>b</sup> Centre Hospitalier Universitaire Vaudois, Lausanne University, Switzerland<sup>c</sup> Prince of Wales Hospital, Sydney, NSW, Australia<sup>d</sup> Royal Rehab Private Hospital, Sydney, NSW, Australia

## ARTICLE INFO

## Article history:

Received 10 February 2014

Received in revised form 4 May 2014

Accepted 3 June 2014

Available online 11 June 2014

## Keywords:

Pure word deafness

Auditory verbal agnosia

Vein of Galen aneurysm

Brain arteriovenous malformation

Brain

## 1. Introduction

Pure word deafness (PWD), or auditory verbal agnosia, is characterized by the inability to understand or repeat spoken language, sparing the discrimination and recognition of environmental sounds, speaking, reading and writing. Because of its rarity and the variety of its possible aetiologies, PWD remains an incompletely understood condition. We report the unique case of a patient developing PWD after surgical resection of a Vein of Galen aneurysm and arteriovenous malformation (VOGA). Clinical and surgical details are presented. Aetiology and pathophysiologic features of PWD in this specific case are discussed and the literature is reviewed.

## 2. Case report

## 2.1. History

A 31-year-old right-handed English speaking female was diagnosed with a VOGA, which was surgically treated by partial

clipping at the age of one year. At the age of 21 years-old she was further diagnosed with a recurrence, for which she underwent an attempted endovascular ablation via a transtorcular venous approach. Two years later, an asymptomatic arteriovenous malformation draining into the galenic system was diagnosed (Fig. 1A–F). The neurological examination prior to surgery was normal, including normal Rinne and Weber test.

## 2.2. Operation

Surgery was performed via an interhemispheric approach, securing the arterial feeders along the tentorial edge. The straight sinus was then cross-clamped and divided. The previously coiled VOGA was in contact with the mesencephalic tectum, occupying the quadrigeminal cistern. Because of difficulty in achieving a reduction in mass effect, it was necessary to remove the previously coiled VOGA en-masse in order to access all of the feeding arteries.

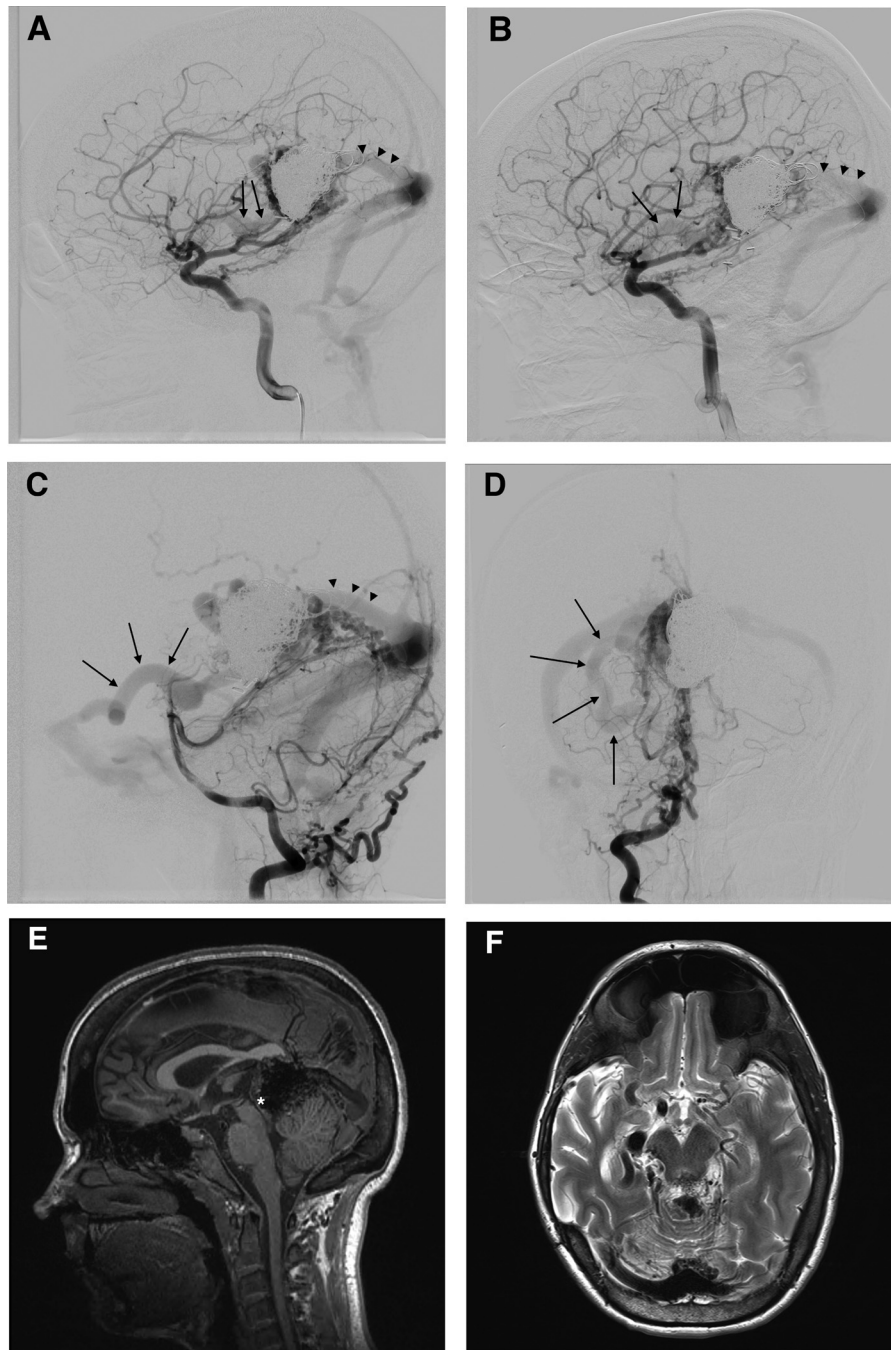
## 2.3. Postoperative course

Our patient was kept in metabolic coma for strict blood pressure control for the first seven postoperative days. Complete VOGA resection was confirmed by cerebral angiography (Fig. 2A and B). She did not develop any postoperative intracranial hypertension or hydrocephalus. At the time of sedation reduction, PWD was noticed but the patient was otherwise able to recognise

\* Corresponding author at: Service de Neurochirurgie, Département des Neurosciences cliniques, Centre Hospitalier Universitaire Vaudois (CHUV), Rue du Bugnon 21, CH-1011 Lausanne, Switzerland.

Tel.: +41 79 195 43 60; fax: +41 21 314 11 99.

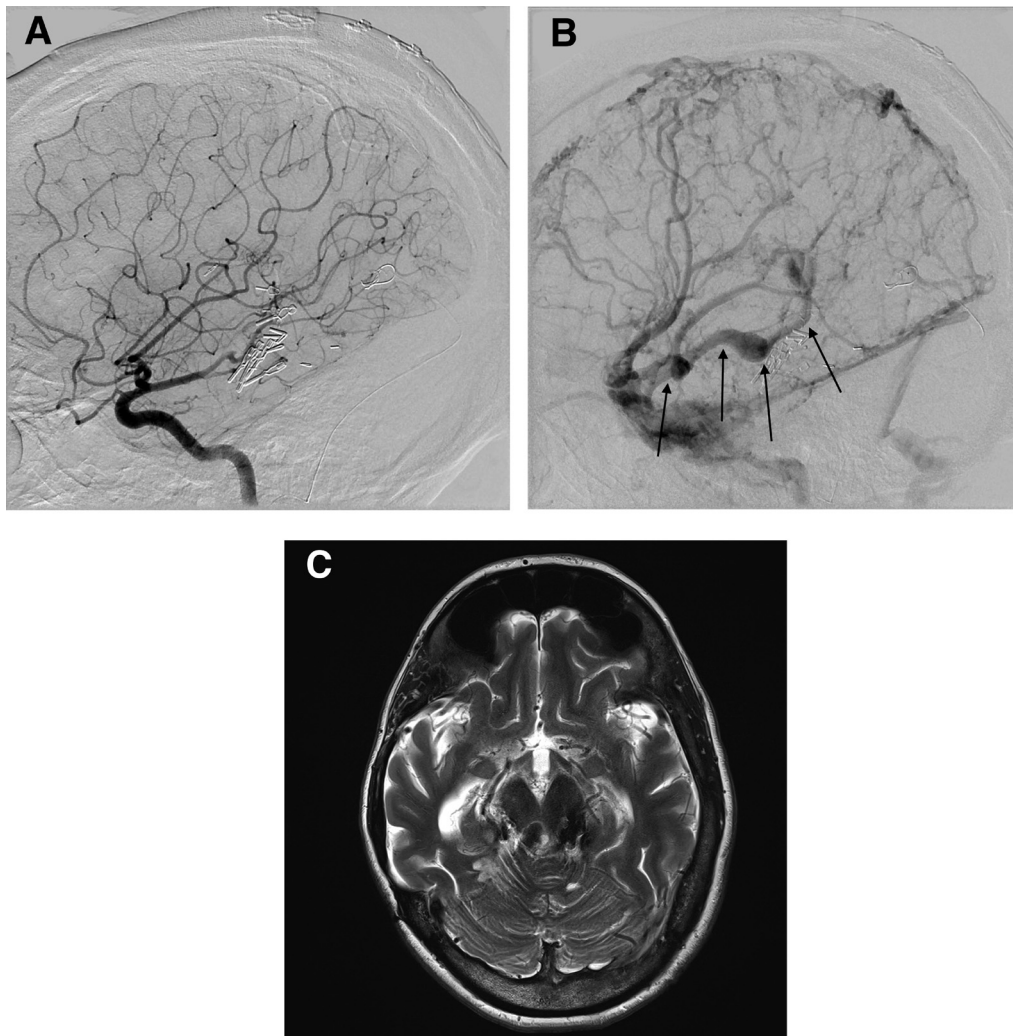
E-mail addresses: [bervinidavid@hotmail.com](mailto:bervinidavid@hotmail.com), [david.bervini@chuv.ch](mailto:david.bervini@chuv.ch) (D. Bervini).



**Fig. 1.** Preoperative images. Lateral left internal carotid artery (A), lateral right internal carotid artery (B), lateral right vertebral artery (C) and antero–posterior right vertebral artery (D) cerebral angiogram images, showing previously coiled Vein of Galen aneurysm and arteriovenous malformation with deep venous drainage into the straight sinus (arrowheads) and anterior drainage (arrows) into the right sphenoparietal sinus. Sagittal T1-weighted (E) and axial T2-weighted (F) cerebral MRI images demonstrating previously coiled Vein of Galen aneurysm and arteriovenous malformation, in contact with the mesencephalic quadrigeminal plate (\*).

nonverbal sounds and music, to name objects, to read and write. There was no evidence of a thought disorder and early postoperative limitation of upward gaze and retraction nystagmus progressively improved. On hearing assessment, impedance tympanometry, acoustic reflexes and distortion product otoacoustic emission testing were preserved bilaterally. Pure tone audiogram (PTA) carried out one month after surgery confirmed only moderate hearing loss. Three frequency average hearing loss (3FAHL) were of 48 dB in the left ear and of 58 dB in the right ear, respectively. Eighth nerve MRI was normal. The findings at surgery, supported by postoperative MRI (Fig. 2C), suggested mesencephalic tectum damage, including bilateral inferior colliculi (IC)

lesions, related to surgical manipulation. One year after surgery, PTA confirmed minor hearing loss (3FAHL of 22 dB bilaterally), while speech audiometry showed very poor speech discrimination in the right ear (25 words speech discrimination score of 47% at 45 dB) and poor to fair discrimination in the left ear (25 words speech discrimination score of 84% at 45 dB). A neuropsychological assessment was performed one year following surgery. This included her ability to retrieve and verbalise semantic information from memory, for instance on the Boston Naming Test (57/60; SD: 0.67), or make abstract semantic associations on a subtest of the Wechsler Adult Intelligence Scale-IV (WAIS-IV; Similarities subtest-SD: 1.50). Her generation of words (expressive language skills)



**Fig. 2.** Postoperative images. Lateral right internal carotid artery arterial-phase (A) and venous-phase (B) cerebral angiogram images, showing Vein of Galen aneurysm and arteriovenous malformation resection and straight sinus occlusion, with preserved anterior venous drainage (arrows) into the right sphenoparietal sinus. T2-weighted cerebral MRI postoperative images (C) showing postoperative changes and clip artefacts at the level of the mesencephalic quadrigeminal plate.

that were prompted by phonetically or semantically related cues was intact as assessed by the Delis–Kaplan Executive Function System (D–KEFS) verbal fluency task (phonetic fluency; SD: 0.33, semantic fluency; SD: –0.33). Spontaneous writing and reading of regular and irregular words were preserved. In contrast, repetition and verbal comprehension of instructions were impaired (Addenbrooke’s Cognitive Examination-Revised; Language Raw Score 20/26: Comprehension of verbal instruction 1/3 and repetition 0/4). This performance was against a background of intact attentional (WAIS-IV Digit Span subtest; SD: –0.33) and information processing abilities (WAIS-IV Coding subtest; SD: –0.33), visuo-spatial skills (copy of Rey figure: >16th percentile), executive functioning (Brixton Spatial Anticipation Task; SD: 0.67; WAIS-IV Similarities subtest and D–KEFS Verbal Fluency mentioned above) and subtly reduced learning and memory (California Verbal Learning Test-II; learning-SD: –0.75, and delayed recall-SD: –1).

### 3. Discussion

After undergoing surgical treatment of a VOGA, our patient presented with selective speech comprehension impairment. Her hearing impairment could not be explained by pure tone audiometric tests, suggesting selective agnosia of sounds. Since

her clinical and speech audiologic assessment confirmed selective hearing impairment for spoken language, the diagnosis of PWD was retained. This differs from more general “auditory agnosia”, which refers to intact auditory acuity without the ability to comprehend verbal as well as nonverbal auditory stimuli, or from “cortical deafness” which designates apparent unawareness of auditory stimuli combined with abnormal pure tone threshold in the absence of peripheral or brainstem damage. PWD is a rare neurological condition. Despite the fact that PWD has been mostly documented in association with cerebrovascular accidents [1], other causes such as intracranial tumor [2–4], intracranial surgery [3,4], head injury [5], neurodegenerative disease, infection and drug toxicity have also been reported. The syndrome was first described in patients with deep dominant temporal lobe lesions, which are responsible for a disconnection of the Wernicke’s area from the auditory input by disrupting the left geniculocortical auditory pathways and callosal fibers from the right auditory cortex. Bilateral superior temporal gyrus damage has also been reported in association with PWD. Hearing impairment due to lesions in the vicinity of the IC accounts for a third and much less common mechanism associated with PWD [1–5]. In our case, intraoperative findings and postoperative images suggest isolated mesencephalic tectal damage. This association of selective PWD

with lesions restricted to both IC has been reported in isolated cases [1,2,4,5]. Of those, only one presented with severe sensorineural hearing loss [1], whilst in the others, PWD was surprisingly associated with normal to moderately impaired pure tone audiogram and preserved sensorineural functions [2,4,5]. No case of PWD complicating VOGA surgery has been reported before.

The IC contain third order neurons and serve as the central relay in the auditory pathway, including ascending and descending input, while the medial geniculate bodies receive projections from IC and are the starting points of geniculocortical fibers that reach the lamina IV of the primary auditory cortex (gyri of Heschl, Brodmann area 41). If the hypothesis stating that all ascending and descending auditory pathways synapse at the level of IC is true, then severe IC damage should theoretically result in complete deafness. This hypothesis was not supported by this current and previously reported cases [1–5].

The study of the association between punctual hearing impairment, like PWD, and discrete hearing pathway lesions is important, because it contributes to our understanding of the complex auditory physiology. Usually, neurological lesions tend to be more extensive, leading to more than an isolated neurological deficit. The current findings not only outline the ongoing discussion about the neural generators of BAEPs, but also reinforce the hypothesis supported by others [2,4] that: (1) a diffuse second auditory “extralemniscal” brain stem pathway might exist, (2) the

auditory processing mechanism for verbal and non verbal sounds might be different, even at a subcortical level, and (3) IC could be part of a complex neuronal network that underlines the processing of speech comprehension.

### Funding source

Dr. Bervini was supported by a scholarship funded by Johnson and Johnson Medical, Pty Limited.

### References

- [1] Kimiskidis VK, Lalaki P, Papagiannopoulos S, Tsitouridis I, Tolika T, Serasli E, et al. Sensorineural hearing loss and word deafness caused by a mesencephalic lesion: clinicoelectrophysiologic correlations. *Otol Neurotol* 2004;25(2):178–82.
- [2] Hoistad DL, Hain TC. Central hearing loss with a bilateral inferior colliculus lesion. *Audiol Neurootol* 2003;8(2):111–3.
- [3] Masuda S, Takeuchi K, Tsuruoka H, Ukai K, Sakakura Y. Word deafness after resection of a pineal body tumor in the presence of normal wave latencies of the auditory brain stem response. *Ann Otol Rhinol Laryngol* 2000;109(12 Pt 1):1107–12.
- [4] Meyer B, Kral T, Zentner J. Pure word deafness after resection of a tectal plate glioma with preservation of wave V of brain stem auditory evoked potentials. *J Neurol Neurosurg Psychiatry* 1996;61(4):423–4.
- [5] Vitte E, Tankere F, Bernat I, Zouaoui A, Lamas G, Soudant J. Midbrain deafness with normal brainstem auditory evoked potentials. *Neurology* 2002;58(6):970–3.