

Neurocase: The Neural Basis of Cognition

Publication details, including instructions for authors and subscription information:

<http://www.tandfonline.com/loi/nncs20>

Ipsilesional and contralesional regions participate in the improvement of poststroke aphasia: a transcranial direct current stimulation study

Vanessa Costa^a, Giuseppe Giglia^a, Filippo Brighina^a, Serena Indovino^a & Brigida Fierro^a

^a Department of Experimental BioMedicine and Clinical Neurosciences (BioNeC), University of Palermo, Palermo, Italy

Published online: 24 Jun 2014.



[Click for updates](#)

To cite this article: Vanessa Costa, Giuseppe Giglia, Filippo Brighina, Serena Indovino & Brigida Fierro (2015) Ipsilesional and contralesional regions participate in the improvement of poststroke aphasia: a transcranial direct current stimulation study, *Neurocase: The Neural Basis of Cognition*, 21:4, 479-488, DOI: [10.1080/13554794.2014.927508](https://doi.org/10.1080/13554794.2014.927508)

To link to this article: <http://dx.doi.org/10.1080/13554794.2014.927508>

PLEASE SCROLL DOWN FOR ARTICLE

Taylor & Francis makes every effort to ensure the accuracy of all the information (the "Content") contained in the publications on our platform. However, Taylor & Francis, our agents, and our licensors make no representations or warranties whatsoever as to the accuracy, completeness, or suitability for any purpose of the Content. Any opinions and views expressed in this publication are the opinions and views of the authors, and are not the views of or endorsed by Taylor & Francis. The accuracy of the Content should not be relied upon and should be independently verified with primary sources of information. Taylor and Francis shall not be liable for any losses, actions, claims, proceedings, demands, costs, expenses, damages, and other liabilities whatsoever or howsoever caused arising directly or indirectly in connection with, in relation to or arising out of the use of the Content.

This article may be used for research, teaching, and private study purposes. Any substantial or systematic reproduction, redistribution, reselling, loan, sub-licensing, systematic supply, or distribution in any form to anyone is expressly forbidden. Terms & Conditions of access and use can be found at <http://www.tandfonline.com/page/terms-and-conditions>

Ipsilesional and contralesional regions participate in the improvement of poststroke aphasia: a transcranial direct current stimulation study

Vanessa Costa^{*†}, Giuseppe Giglia[†], Filippo Brighina, Serena Indovino and Brigida Fierro

Department of Experimental BioMedicine and Clinical Neurosciences (BioNeC), University of Palermo, Palermo, Italy

(Received 27 April 2013; accepted 19 May 2014)

In the past few years, noninvasive cerebral stimulations have been used to modulate language task performance in healthy and aphasic patients. In this study, a dual transcranial direct current stimulation (tDCS) on anterior and posterior language areas was applied for 2 weeks to a patient with a possible crossed aphasia following a right hemisphere stroke. Inhibitory cathodal stimulation of the right Brodmann areas (BA) 44/45 and simultaneous anodal stimulation of the left BA 44/45 improved the patient's performance in picture naming. Conversely, the same bilateral montage on BA 39/40 did not produce any significant improvement; finally, electrode polarity inversion over BA 39/40 yielded a further improvement compared with the first anterior stimulation. Our findings suggest that ipsilesional and contralesional areas could be useful in poststroke functional reorganization and provide new evidences for the therapeutic value of tDCS in aphasia.

Keywords: aphasia; transcranial direct current stimulation; stroke; language network; language recovery

As indicated by some functional studies (Crinion & Leff, 2007; Fridriksson, Bonilha, Baker, Moser, & Rorden, 2010; Postman-Caucheteux et al., 2010; Rosen et al., 2000; Warburton, Price, Swinburn, & Wise, 1999), a more effective and long-term recovery from aphasia is determined by recruitment of perilesional areas, whereas the role and the functional relevance of the contralesional areas are not well established yet, although activation of both right hemisphere and left hemisphere associated with aphasia recovery has been reported (Calvert et al., 2000; Crosson et al., 2005; Fernandez et al., 2004; Vitali et al., 2007). Typically, right hemisphere regions, recruited during linguistic tasks, are homologous to damaged language areas of the left hemisphere (Abo et al., 2004; Thompson, 2004; Xu et al., 2004).

The issues concerning the compensatory mechanisms in aphasia recovery have been addressed through the application of noninvasive cerebral stimulation methods (for recent reviews, see Cotelli et al., 2011; Hamilton, Chrysikou, & Coslett, 2011).

Transcranial direct current stimulation (tDCS) acts by altering membrane potential of cortical neurons. The effects are determined by the stimulation polarity: anodal stimulation increases excitability and cathodal stimulation decreases it (Liebetanz, Nitsche, Tergau, & Paulus, 2002; Nitsche & Paulus, 2000). tDCS has principally been used to study motor, visual (for a recent review, see Antal, Paulus, & Nitsche, 2011), and cognitive functions (for a recent review, see Jacobson, Koslowsky, & Lavidor, 2012)

and to evaluate its potential in therapeutic applications for different neurological diseases (Miniussi et al., 2008; Sparing & Mottaghy, 2008).

tDCS has been applied over frontoparietal and temporoparietal areas to promote a linguistic improvement, and different results have been obtained (Monti et al., 2013; Schlaug, Marchina, & Wan, 2011). For example, after 5 days of anodal tDCS to the damaged hemisphere, paired with anomia treatment, better performance in naming was detected (Baker, Rorden, & Fridriksson, 2010; Fiori et al., 2011). Similarly, using anodal stimulation of the left Broca's area in patients with speech apraxia, Marangolo et al. (2011) obtained an improvement in a repetition task. However, in contrast, Monti et al. (2008), after a single session of cathodal stimulation of the left Broca's area in a group of aphasic patients, found an increase in accuracy in picture naming compared to sham and anodal stimulation. Finally, applying cathodal stimulation on the homologous Wernicke's area, You, Kim, Chun, Jung, and Park (2011) reported an improvement in a verbal comprehension task for a group of 21 subacute aphasic patients.

It was hypothesized that if cathodal tDCS provokes hyperpolarization of the cellular membranes and anodal tDCS produces their depolarization (Liebetanz et al., 2002) (but see Jacobson et al., 2012), then a cumulative and synergic effect of both could be possible (Vines, Cerruti, & Schlaug, 2008). Bihemispheric montage involves an electrode being placed on the target area, whereas the opposite electrode is positioned on the

*Corresponding author. Email: vanessa.costa@unipa.it

[†]These authors contributed equally to this work.

homologous contralateral area. In some studies, an additive effect of dual tDCS was obtained with respect to the montage with a single active electrode (Giglia et al., 2011; Vines et al., 2008). For example, a significantly greater impairment of performance in a visuospatial task was obtained in *normal subjects* using dual tDCS on the posterior parietal cortex (PPC) (anode on left PPC and cathode on right PPC) compared to isolated cathodal tDCS on right PPC (Giglia et al., 2011). Dual tDCS was also used in studies regarding the visual and working memory of *healthy subjects* (Chi, Fregni, & Snyder, 2010; Sandrini, Fertonani, Cohen, & Miniussi, 2012). Recently, bihemispheric stimulation was used successfully in a group of eight patients with apraxia of speech (Marangolo et al., 2013) and in a single-case study, together with a verb anomia training (Manenti et al., 2014). In this last report (Manenti et al., 2014), after 20 sessions of bihemispheric stimulation on dorsolateral prefrontal cortex (DLPFC) (tDCS anodal was placed on the left DLPFC and tDCS cathodal was placed on the right DLPFC), an aphasic patient achieved an improvement in treated and untreated verbs naming and the effect lasted up to 48 weeks after the end of stimulation.

Generally, aphasia is a consequence of stroke to the left hemisphere, but more rarely, linguistic disorders after stroke to the right hemisphere have been reported in both left- and right-handed individuals, taking the name of crossed aphasia and crossed aphasia in dextrals (for a review, see Marien, Paghera, De Deyn, & Vignolo, 2004). To the best of our knowledge, only in one study was inhibitory repetitive transcranial magnetic stimulation (rTMS) used on the contralateral hemisphere to examine functional recovery of a patient with crossed aphasia (Jung et al., 2010).

In this current article, we present a case study in which repeated sessions of dual tDCS were used to improve naming performance in a chronic aphasic patient following stroke to the right middle cerebral artery (MCA). EBE (acronym of patient's name) presented a severe impairment of expressive and receptive language (see later) and a structural preservation of the left hemisphere (see Figure 1). Crossed aphasia was suspected, but the five criteria employed in the literature for this diagnosis were not completely satisfied (Marien et al., 2004): presence of aphasia, right-handedness documented by a formal test, lesion confined to the right hemisphere, absence of left-handedness in relatives, and absence of early brain

damage. When the first three criteria are met, a diagnosis of possible crossed aphasia could be made. EBE was right-handed (she writes and draws with the right hand before and after the stroke), but it was not clear if she was forced to shift the original left-hand preference to the right due to pressure at school. Moreover, her husband reported a double preference of EBE in the execution of daily activities, and he was not sure if EBE has left-handed relatives. Severe aphasia of EBE and left hemiparesis with marked involvement of the upper limb prevented a formal test for handedness. However, we asked her husband to answer the questions of the Edinburgh Handedness Inventory (handedness score: +78). Therefore, on the basis of the model of Marien et al. (2004), the patient could be classified as a case of possible crossed aphasia.

This is the first study in which a dual tDCS has been used to ameliorate naming performance of an aphasic patient following stroke to the right hemisphere.

Since the naming task involves processes that probably take place in separate brain regions (Abel et al., 2009; Hillis et al., 2006), we decided to stimulate Broca's and Wernicke's areas electrically to evaluate whether repeated bihemispheric tDCS (daily frequency for 2 weeks) on these areas could contribute differently to improvement in the picture-naming task.

Because of the particularity of this case, a patient with possible and unreliable crossed aphasia, to decide the most suitable dual montage for tDCS treatments, we carried out an exploratory pilot experiment. Dual tDCS was used on the Brodmann areas (BA) 44/45 in three separate sessions: anode on the right and cathode on the left, anode on the left and cathode on the right, and sham. The montage inducing the best performance was then chosen for the subsequent treatment.

Materials and methods

Case description

EBE was a 57-year-old woman, with 13 years of education, a native Italian speaker, and a public clerk, who suffered from aphasia with dysarthric and disfluent speech, following total complete right MCA stroke (Figure 1). The patient was affected by hypertension and diabetes mellitus; she suffered from a left hemiplegia and she presented with hemihypesthesia. She did not show extinction phenomena



Figure 1. Representative magnetic resonance imaging (MRI) images of EBE at the time of the present study. T1-weighted 1.5-T MRI scan (the thickness of the MRI slice is 1.2 mm) shows the right-hemisphere lesion.

Table 1. EBE's visuospatial abilities as measured by standardized tests.

	Score	Cutoff
Corsi span	4.25	3.25
Rey picture – copy	33.5	28.87
Rey picture – recall	16.25	9.46
Constructional apraxia	14	7.75
Bell's test	1	<2
Benton's Judgment of Line Orientation	19	19

in the auditory modality and in the visual modality, a history of early brain damage or seizure in childhood, depression, and drug and/or alcohol abuse. She was referred to us in March 2011, 2.5 years after the stroke.

The stroke affecting the right hemisphere (about 8 cm of lesion on axial plane) spared EBE's drawing skills; she perfectly maintained visuospatial abilities, as shown by the results of the standardized tests (Table 1). After 3-month speech therapy carried out during the subacute period of the stroke, EBE presented a severe nonfluent aphasia and produced a few words randomly and inappropriately. Her comprehension was better but also mildly impaired. Nonetheless, magnetic resonance imaging (MRI) showed morphological integrity of the left hemisphere (see Figure 1). A language evaluation was carried out with the Battery for the Analysis of the Aphasic Deficit (BADA; Miceli, Laudanna, Burani, & Capasso, 1994), and the results are presented in Table 2. Severe aphasia of EBE prevented the execution of some linguistic tasks: she was unable to read and write but she was able to perform word and sentence comprehension, lexical

decision, repetition, and picture naming, even though, in these tasks, she produced many errors (Table 2). Almost all errors in repetition consisted of words and pseudowords phonologically related to the target (*trasmesse*, *transmitted* → *sommesse*, *subdued*; *dappertutto*, *everywhere* → *dadetutto*, *pseudoword*). In the picture-naming task, EBE needed a phonological cue (the first or the first two phonemes of the stimulus) without which she could name hardly any picture. This cue gave rise to the production of lexical substitution that shared with the target the first or the first two phonemes, which sometimes were linked neither semantically nor phonologically to the stimulus. Thus, most of the errors in naming consisted in uttering related or unrelated words (i.e., *ponte*, *bridge* → *pomodoro*, *tomato*; *tasca*, *pocket* → *tavolo*, *table*; *camminare*, *to walk* → *dormire*, *to sleep*; *cucire*, *to sew* → *cucinare*, *to cook*) and pseudowords (i.e., *bottiglia*, *bottle* → *bottocchia*; *tromba*, *trumpet* → *totto*; *sudare*, *to sweat* → *sugare*; *macinare*, *to grind* → *manuciare*). Semantic (i.e., *pesca*, *peach* → *pera*, *pear*; *fuoco*, *fire* → *fumo*, *smoke*; *versare*, *to pour* → *bere*, *to drink*; *spingere*, *to push* → *tirare*, *to pull*) and perseverative errors were also produced. Performance in naming was comparable for different frequency words (high-frequency words: 71/102 errors, 70%; low-frequency words: 78/102 errors, 76%; $\chi^2 = 1.22$; $p = .27$) and grammatical class words (nouns: 75/104 errors, 72%; verbs: 74/100, 74%; $\chi^2 = 0.09$; $p = .76$).

Research was conducted in accordance with the Helsinki Declaration as revised in 1989. A written informed consent was obtained from EBE and her husband.

Pilot experiment

Picture-naming task

Thirty-two pictures (16 objects and 16 actions), extracted from BADA and matched for frequency, were presented to EBE. Seeing her inability to name pictures without a phonological cue, the images for the naming task were first presented without cues, then after 10 s with a first letter, and if no response was obtained after another 10 s, with the first two letters. The processes underlying picture naming are manifold. To name a picture, an individual has to recognize the image, activate semantic representation based on the visual and structural features of the object, and relate the semantic feature to the lexical representation and when the word was chosen all the letters constituting that word have to be produced in the correct order (Whatmough & Chertkow, 2002). In our modified naming task, a phonological cue, provided together with the image, would facilitate the link between the semantic features and the phonological representation of the words.

The following scores were used: 0 = incorrect response; 0.5 = correct response after two letters of

Table 2. Percentage of incorrect responses (number of incorrect items/total number of items) produced by EBE in some subtests of BADA (Miceli et al., 1994).

<i>Repetition</i>	
Words	47.7 (43/90)
Pseudowords	55.5 (40/72)
<i>Lexical decision</i>	
Auditory	20 (32/160)
Visual	32 (51/160)
<i>Auditory word–picture match</i>	
Nouns	26 (21/80)
Verbs	22.5 (9/40)
<i>Visual word–picture match</i>	
Nouns	10 (8/80)
Verbs	37.5 (15/40)
<i>Spoken naming</i>	
Nouns	72 (75/104)
Verbs	74 (74/100)
<i>Sentence–picture matching</i>	
Auditory	42.5 (51/120)
Visual	42 (38/90)

phonological cue; 1 = correct response after one letter; and 2 = correct response without cue. In a 16-word list, the highest score would be 32. Therefore, a higher “score” means a better performance.

The sums of the scores obtained in different experimental conditions were compared by means of one-way analysis of variance (ANOVA) tests with conditions (four levels: baseline, sham, anode on the right, and anode on the left). The number of correctly named pictures (accuracy) was also measured. The accuracy percentage (correct trials/all trials) was arcsine-transformed and then analyzed by means of one-way ANOVA tests as within-subject factors. The presentation order of pictures was random for the four conditions (baseline, sham, anode on the right, and anode on the left) within each category of pictures.

tDCS

Three single sessions of dual tDCS were carried out with a 1-week interval between them. By using an electroencephalography (EEG) cap, the electrode was positioned on F5, according to the International 10-20 System for EEG electrode placement, and symmetric coordinates were used for the homologous site.

In the first session, the anode was placed on the left BA 44/45 and the cathode was placed on the right BA 44/45 (“anode on the left” condition); then the montage was inverted in the other two sessions, that is, first real (“anode on the right” condition) and second sham stimulation (sham condition). Between the two real stimulations, performances in the modified naming task were measured in baseline condition (without stimulation). A direct current stimulator (Magstim Company Ltd, Whitland, Wales, UK), battery-powered, was used. The two electrodes, covered with saline solution soaks, were applied to the scalp. Each soak had an area of 16 cm² (4 × 4). The current increased in the first 8 s up to 1 mA, and then, it remained constant throughout the stimulation time (20 min). For sham tDCS, the 1-mA intensity was only given for 30 s, reproducing sensations provoked by the passage of current at the start of the stimulation. In all conditions of stimulation (two real and one sham tDCS), the naming task started 5 min after the onset of tDCS and was completed at the end of the stimulation.

Results of the pilot experiment

tDCS efficacy was greater when the cathode was positioned on the right BA 44/45 and the anode was positioned on the left BA 44/45 (“anode on the left” condition). One-way ANOVA for the score showed no significant main effect: $F(3, 93) = 1.335$, $p = .27$ (Figure 2(a)). A univariate test of significance for

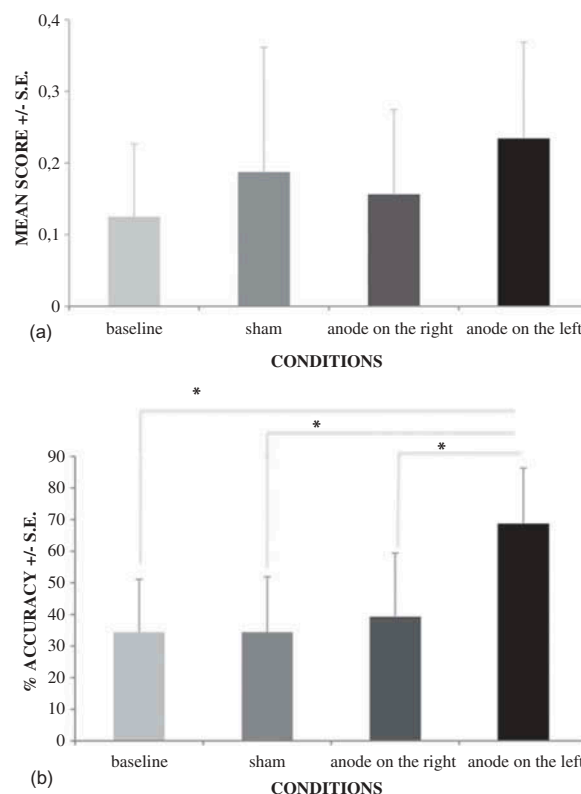


Figure 2. (a) Mean score and (b) mean accuracy of the naming task in the different sessions of the pilot experiment.

Notes: Error bars indicate standard errors (SE). *Significant difference ($p < .05$). The score is based on the number of phonological cues given to EBE in the naming task: no cue with correct response: 2; one letter of cue with correct response: 1; two letters of cue with correct response: 0.5; two letters of cue with incorrect response: 0. The mean accuracy represents the proportion of correct responses (see Materials and methods section). In Figure 2(b), “anode on the left” condition is significant ($p < .05$) versus all the other conditions. In the “anode on the right” condition, the anode is placed on the right and the cathode is placed on the left BA 44/45; in the “anode on the left” condition, the cathode is placed on the right and the anode is placed on the left BA 44/45; in the sham condition, a fictitious stimulation is used.

planned comparison showed a significant difference between the score in baseline and the score in the “anode on the left” condition, ($F = 6.355$, $p = .017$), but no significant difference was found between the score in baseline and the score in the “anode on the right” condition ($F = 0.39$, $p = .53$) or sham ($F = 1.35$, $p = .25$). Moreover, the sham condition did not show any significant difference with all the other conditions. One-way ANOVA for accuracy showed a significant main effect, $F(3, 93) = 4.43$, $p = .05$ (Figure 2(b)). Duncan’s post hoc analysis showed that the “anode on the left” condition was significantly different ($<.05$) as compared to all the other conditions. No significant interaction for both noun and verb scores in all directions was observed, $F(3, 45) = 1.53$, $p = .22$. The same results were found for accuracy, $F(3, 45) = 1.92$, $p = .14$.

Experimental treatment

Two tDCS treatments with EBE were carried out using the “anode on the left” condition, in which the cathode was positioned on the damaged hemisphere and the anode was positioned on the preserved contralateral hemisphere. In Experiment 1, BA 44/45 were stimulated, and in Experiment 2, BA 39/40 were stimulated, for 2 weeks. The same modified naming task as used in the pilot experiment was given.

Experiment 1 – anterior region stimulation

The treatment started 1 month after the end of the pilot experiment. Dual tDCS was applied on F5 and F6 (according to the International 10-20 System for EEG electrode placement), the cathode on the right and the anode on the left. Stimulation was applied at 1 mA for 20 min daily for 2 weeks (weekend free) (timeline for the experiments is given in Figure 3).

EBE performed the naming of the set of 32 pictures (16 nouns and 16 verbs) at the following times: before tDCS (T0), immediately after the end of tDCS treatment (T1), and 3 days after the end of the treatment, and if an effect was found, her performance was checked every 3 days, until it came back to the baseline level. When the effect was lost, we started sham stimulation, which was carried out like the real treatment. An exception was to program current duration for 30 s, to simulate the initial itch sensation. During stimulation, EBE was seated and the tDCS machine was positioned out of sight.

Experiment 2 – posterior region stimulation

Four months after the previous experiment, EBE was recruited for a second treatment. Material and procedures were the same as for Experiment 1 (Figure 3), but in this case, the right and left BA 39/40 were stimulated.

After the modified picture-naming task was performed at T0, a tDCS session (1 mA, 20 min) was carried out daily for 2 weeks (weekend free). The cathode was positioned on the right BA 39/40 in position CP6 (according to the International 10-20 System for EEG electrode

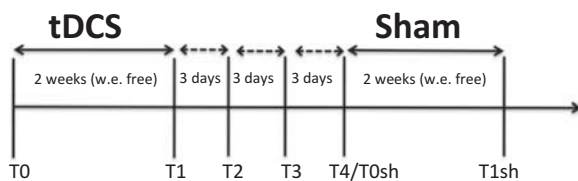


Figure 3. Timeline for Experiments 1, 2, and 3.

Notes: w.e. = weekend; T0, T1, T2, T3, T4/T0sh, T1sh = different evaluation times in picture-naming tasks, before and after real and sham stimulations.

placement), and the anode was positioned on the left BA 39/40 in position CP5.

EBE performed the same picture-naming task at the end of the real stimulation (T1), and her performance was checked every 3 days. Sham stimulation followed the same timeline as in Experiment 1.

In both the experiments, score (obtained by means of the number of phonological cues given to EBE) and accuracy (percentage of correct responses), evaluated separately for nouns and verbs, were measured.

Results

Six measures of performance (at six different times) were obtained in Experiment 1 (anterior: a) and in Experiment 2 (posterior: p): baseline/apT0, immediately after the end of treatment/apT1, after 3 days/apT2, after 6 days/apT3, after 9 days/apT4, and immediately after the end of sham/apT1sh. Measurement apT4 was considered the baseline of the sham (real/apT4 = sham/apT0) because this time the performance in Experiment 1 came back to the baseline value.

Results of anterior region stimulation

One-way ANOVA with conditions (six levels: aT0, aT1, aT2, aT3, aT4/aT0sh, and aT1sh), as within-subject factors, showed a significant main effect on score: $F(5, 155) = 2.29$, $p = .048$ (Figure 4(a)). Duncan's post hoc

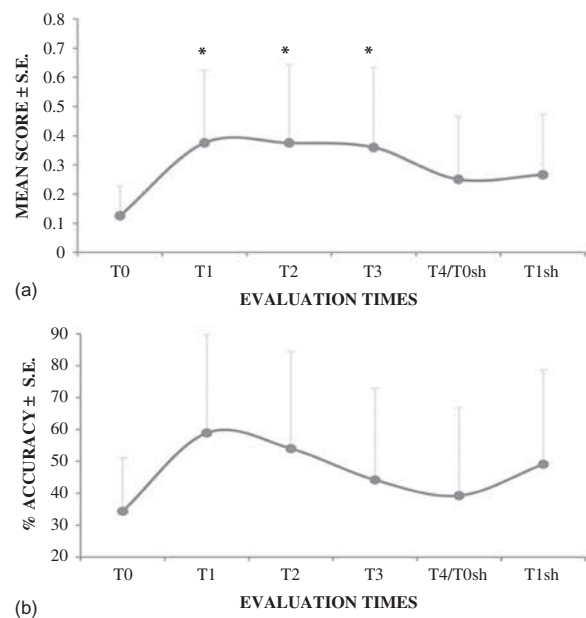


Figure 4. (a) Mean score and (b) mean accuracy at the different times in Experiment 1.

Notes: Error bars indicate standard errors (SE). *Significant difference ($p < .05$).

analysis showed that baseline condition (aT0) was significant versus all the other conditions ($p < .004$), except for aT4/aT0sh and aT1sh. No other significances were found in post hoc analysis. One-way ANOVA for accuracy showed no significant effect: $F(5, 155) = 1.3$, $p = .26$ (Figure 4(b)).

Results of posterior region stimulation

One-way ANOVA with conditions (six levels: pT0, pT1, pT2, pT3, pT4/pT0sh, and pT1sh), as within-subject factors, showed no significant main effect between conditions on score, $F(5, 155) = 1.76$, $p = .12$, and accuracy $F(5, 155) = 1.1$, $p = .35$.

Furthermore, two one-way ANOVAs with conditions (two levels: real and sham tDCS), categories (two levels: nouns and verbs), and times (two levels: T0 and T1), as within-subject factors, showed no significant interaction in both score and accuracy in Experiment 1 – score: $F(1, 15) = 0.20$, $p = .66$; accuracy: $F(1, 15) = 4.31$, $p = .055$ – and in Experiment 2 – score: $F(1, 15) = 3.71$, $p = .07$; accuracy: $F(1, 15) = 1.36$, $p = .26$.

We wonder whether in Experiment 2 EBE failed to achieve amelioration because of an erroneous choice of electrode polarity. In this connection, the same tDCS pad montage, with the anode on the contralateral hemisphere and the cathode on the ipsilesional hemisphere, was used in both experiments even though extensive literature suggests that the excitatory stimulation of ipsilesional areas facilitates recovery. One could argue that a different montage, with anodal (excitatory) stimulation of the damaged hemisphere and cathodal (inhibitory) stimulation of the spared hemisphere on the posterior region, could give more beneficial results in our patient. Thus, we decided to perform a further study (Experiment 3 (Posterior: P) in which tDCS treatment on BA 39/40 was carried out with a reversed electrode polarity with respect to Experiment 2.

Addendum

Experiment 3 – posterior region stimulation

Four months after the end of Experiment 2, EBE was recalled. Material, tDCS parameters, and experimental timeline (Figure 3) were the same as for Experiments 1 and 2, but in this case, the anode was placed on the right BA 39/40 and the cathode was placed on the left BA 39/40 (positions CP6 and CP5, respectively, according to the International 10-20 System for EEG electrode placement).

Results of Experiment 3

One-way ANOVA with conditions (six levels: PT0, PT1, PT2, PT3, PT4/PT0sh, and PT1sh), as within-subject factors, showed a significant effect of treatment on score,

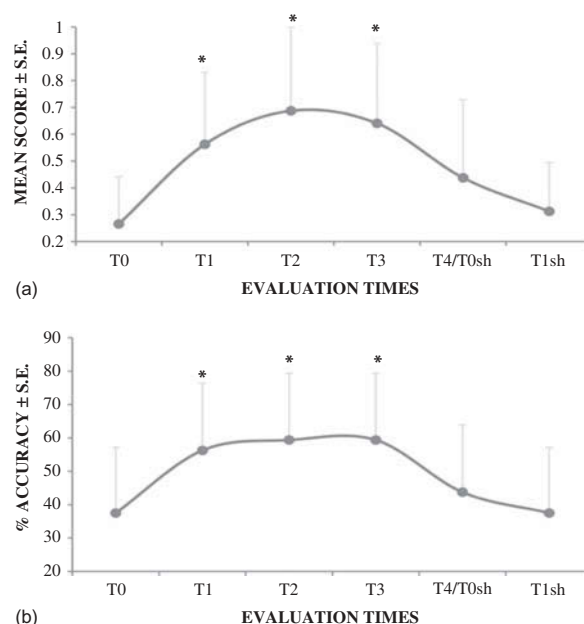


Figure 5. (a) Mean score and (b) mean accuracy at the different times in Experiment 3.

Notes: Error bars indicate standard errors (SE). *Significant difference ($p < .05$).

$F(5, 155) = 3.9$, $p = .002$ (Figure 5(a)), and accuracy, $F(5, 155) = 3.3$, $p = .007$ (Figure 5(b)). Duncan's post hoc analysis showed that baseline condition (PT0) was significant ($p < .05$) versus posttreatment conditions (PT1, PT2, and PT3) but not versus both PT4/PT0sh and PT1sh.

Concerning possible different performance between nouns and verbs, one-way ANOVA with conditions (two levels: real and sham tDCS), categories (two levels: nouns and verbs), and times (two levels: T0 and T1), as within-subject factors, showed no significant interaction on either score, $F(1, 15) = 3.12$, $p = .10$, or accuracy, $F(1, 15) = 2.72$, $p = .11$.

Discussion

We have presented a single-case study of possible crossed aphasia following stroke to the right MCA where, after dual tDCS treatment, an improvement that lasts up to 6 days after the end of stimulation was obtained in a modified naming task. Specifically, anodal stimulation on left BA 44/45 and simultaneous cathodal stimulation on right BA44/45 (Experiment 1) significantly increased the score; that is to say, EBE needs a lower number of phonological cues, given the pictures together, to obtain a correct response in the naming task, compared to baseline and sham stimulation. By contrast, the same montage on BA 39/40 (Experiment 2) produced no significant improvement, but the reverse polarity, anodal tDCS on the right and cathodal tDCS on the left BA 39/40 (Experiment 3),

ameliorated performance in terms of both score and accuracy. No differences in performance were found between nouns and verbs in all conditions for each of the three experiments, even though an improvement for verbs could be expected after anterior stimulation (Cotelli et al., 2006; Finocchiaro et al., 2006, but see Crepaldi, Berlingeri, Paulesu, & Luzzatti, 2011 for a different interpretation). One of the possible reasons for this failed grammatical class effect could be the anatomic extension of EBE's lesion and her severe linguistic impairment (Table 2). Furthermore, the amplitude of the area of the electrodes used for tDCS (16 cm²) could produce a more general effect on the network of the picture-naming task.

This is the first study in which, after bilateral tDCS of the anterior (Experiment 1) and posterior (Experiment 3) linguistic cerebral regions, using opposite polarities of stimulation, an improvement was obtained in an aphasic patient following stroke to the right hemisphere. In the literature, there is only one case of a crossed aphasia patient in whom inhibitory rTMS on the contralateral (left) hemisphere produced an improvement in a word-generation task (Jung et al., 2010). This result was comparable with other cases of transcranial stimulation in aphasic patients after stroke to the left hemisphere (Barwood et al., 2011; Hamilton et al., 2010; Naeser et al., 2005). Our study also achieved results already reported in the literature. Indeed, in Experiment 1, EBE's performance improved after anodal stimulation of the contralateral anterior region together with cathodal stimulation of the ipsilesional anterior region, similar to what was reported by Monti et al. (2008). In Experiment 3, EBE obtained amelioration after excitatory stimulation of the ipsilesional hemisphere and inhibition of the contralateral hemisphere, replicating other literature data (Baker et al., 2010; Fiori et al., 2011; Jung, Lim, Kang, Sohn, & Paik, 2011; You et al., 2011). Thus, the results of the few studies in which transcranial stimulation was used on patients with right hemisphere stroke seem comparable with the other left hemisphere stroke cases discussed in the previous literature.

Heiss and Thiel (2006) proposed a hierarchic model of recruitment of dominant and contralateral areas for post-stroke aphasia recovery, depending on the extension of the lesion: original activation patterns within the network of the dominant hemisphere produce the most marked improvement; activation of areas around the lesion could produce good recovery; and finally, limited recovery depends on activation of contralateral homotopic areas. According to this model, the poor recovery of EBE 2 years after the injury and the extension of her lesion support the possibility that in this patient, the contralateral homotopic areas could participate in linguistic processing. In this connection, considering that the regions surrounding the right BA 44/45 are damaged and they have poor possibilities of recovery, anodal tDCS on the spared homologous left BA 44/45 could have promoted recruitment of

this region for linguistic processing. Moreover, our simultaneous cathodal stimulation on the right BA 44/45 would decrease the neural activity in this area, whose background noise could interfere with the functioning of the spared left one. Unfortunately, we have no functional MRI data confirming this tDCS effect. However, supporting our interpretation, in the pilot experiment, cathode on the left BA 44/45 and anode on the right BA 44/45 did not produce beneficial results ("anode on the right" condition in Figure 2(a) and (b)).

Thus, a plausible tDCS action could be to strengthen poststroke functional reorganization of language that, considering the extension of EBE's lesion, would be shifted to the contralateral cerebral regions. This explanation, however, would fit well for the anterior area, but it cannot be invoked for the posterior stimulations, either for Experiment 2, where no improvement was obtained using the montage of Experiment 1, or for Experiment 3, in which the opposite electrodes montage of Experiments 1 and 2 (anodal tDCS on right and cathodal tDCS on left) produced an improvement for both score and accuracy. How can we reconcile these results?

It is possible that the regions around the right (ipsilesional) BA 39/40 might be available to serve language functions. This would explain the results of both Experiments 2 and 3. In Experiment 2, the lack of improvement could be attributed to the further inhibition, due to the cathodal tDCS on ipsilesional posterior area, of a region belonging to a compensatory alternative naming network, the network that after excitatory anodal stimulation produced EBE's amelioration in Experiment 3. Contemporaneous cathodal stimulation over contralateral homologous regions would have strengthened this effect (Giglia et al., 2011; Vines et al., 2008). Moreover, consistently with Heiss and Thiel's (2006) models, perilesional regions would participate with more success in poststroke aphasia recovery than contralateral areas: this would explain why only one measure (score) in Experiment 1 and both behavioral measures (score and accuracy) in Experiment 3 improved.

Our findings suggest that, as evidenced by other studies (Naeser et al., 2011; Turkeltaub et al., 2012), different regions in each hemisphere could variously participate in poststroke language reorganization and could be involved in aphasia recovery. Considering that tDCS alters membrane potential (unlike rTMS, which is able directly to stimulate the neurons), it is plausible that it could strengthen an alternative network, which could be distributed in different regions of the two hemispheres (in our case, contralesional anterior and ipsilesional posterior) *based on the extension of the lesion after the stroke*. Of course, further investigations will be needed to confirm this possible functional reorganization in other patients.

The results of Experiment 1 could seem to be in contrast with two previous tDCS treatments, in which

after anodal stimulation of the left Broca's and Wernicke's regions, right-handed aphasic patients demonstrated improvement in terms of error number and reaction times in naming tasks (Baker et al., 2010; Fiori et al., 2011). Some comments have to be made in this regard. For both studies, the effect of right anodal stimulation has not been explored. In this connection, Baker et al. (2010) only stimulated anodically the left Broca's area (with patients undergoing anomia treatment) according to the consideration that the regions of the left hemisphere play a crucial role in aphasia recovery, as indicated by some functional studies (Crinion & Leff, 2007; Fridriksson et al., 2010; Postman-Caucheteux et al., 2010). However, although this claim was experimentally supported, the possible contribution of the right hemisphere in aphasia recovery was not taken into account by these authors. Fiori et al. (2011) omitted to anodically stimulate the right posterior regions because in the same study no significant effect was found in a nonword learning task by healthy subjects. One could object that after brain damage, a functional reorganization, linked to neuronal plasticity and depending on several factors, could occur. Consequently, the same type of stimulation on brain-damaged and healthy individuals is probably not comparable.

By contrast, the results of Experiment 1 were similar to those reported by Monti et al. (2008), who after a single cathodal stimulation of the left frontotemporal areas obtained an improvement in a group of aphasic patients. The authors claimed a possible deactivation of inhibitory interneurons of the left hemisphere that reduces intrahemispheric inhibition, consequently allowing better functioning of an alternative left linguistic network. In our case, simultaneous anodal stimulation on the spared area could suggest different explanations. Indeed, in a recent review, Jacobson et al. (2012) reported that anodal stimulation has more efficacy on cognitive and, specifically, linguistic tasks, probably because of the strong representation of the linguistic network in the brain (Jacobson et al., 2012). Thus, a plausible interpretation of EBE's improvement after dual stimulation of the anterior region could mainly pertain to the participation of the left spared hemisphere, although dual stimulation should have an intensifier effect modulating activity in opposite directions simultaneously.

One limit of this study was repeating the same 32 stimuli to EBE several times. Of course, it cannot be excluded that the patient acquired familiarity with the task and the items; however, this cannot explain at all the improvement after real tDCS, because a comparable result should also be evidenced in the sham condition, where instead EBE's performance worsened with respect to the previous repetition of the task.

The present report, in line with previous studies, also strengthens the value of tDCS as a compelling therapeutic tool in severe chronic aphasia following stroke to the right

hemisphere and underlines the need to carefully evaluate the areas of the linguistic network to be stimulated in rehabilitative programs. Moreover, it is worth bearing in mind that the efficacy of tDCS treatment could depend on several factors such as onset and extension of the lesion, individual features, and capacity of the available cerebral tissue to take over the functions previously performed by the damaged cerebral areas (plasticity). Each of these factors should be considered in studies in which patients receive transcranial stimulations. Finally, despite the peculiarities of our patient, who does not represent the general population of patients with poststroke aphasia, we think that our study can help to increase knowledge in the neurostimulation field applied to the recovery of aphasia. Indeed, as claimed by Cappa (2011, p. 750), "Given the huge variability among aphasic patients at the clinical and neurological level, it is highly unlikely that a single procedure may be universally effective."

Acknowledgments

We thank Chiara Cupidi who referred the patient EBE. We especially thank EBE for her unfailing collaboration during the research.

References

- Abel, S., Dressel, K., Kümmerer, D., Saur, D., Mader, I., Weiller, C., & Huber, W. (2009). Correct and erroneous picture naming responses in healthy subjects. *Neuroscience Letters*, 463, 167–171. doi:10.1016/j.neulet.2009.07.077
- Abo, M., Senoo, A., Watanabe, S., Miyano, S., Doseki, K., Sasaki, N., ... Yonemoto, K. (2004). Language-related brain function during word repetition in post-stroke aphasics. *Neuroreport*, 15, 1891–1894. doi:10.1097/00001756-200408260-00011
- Antal, A., Paulus, W., & Nitsche, M. (2011). Electrical stimulation and visual network plasticity. *Restorative Neurology and Neuroscience*, 29, 365–374.
- Baker, J. M., Rorden, C., & Fridriksson, J. (2010). Using transcranial direct-current stimulation to treat stroke patients with aphasia. *Stroke*, 41, 1229–1236. doi:10.1161/STROKEAHA.109.576785
- Barwood, C., Murdoch, B., Whelan, B., Lloyd, D., Riek, S., O'Sullivan, J., ... Wong, A. (2011). Improved language performance subsequent to low-frequency rTMS in patients with chronic nonfluent aphasia post-stroke. *European Journal of Neurology*, 18, 935–943. doi:10.1111/j.1468-1331.2010.03284.x
- Calvert, G., Brammer, M., Morris, R., Williams, S., King, N., & Matthews, P. (2000). Using fMRI to study recovery from acquired dysphasia. *Brain & Language*, 71, 391–399. doi:10.1006/brln.1999.2272
- Cappa, S. (2011). The neural basis of aphasia rehabilitation: Evidence from neuroimaging and neurostimulation. *Neuropsychological Rehabilitation*, 21, 742–754. doi:10.1080/09602011.2011.614724
- Chi, R., Fregni, F., & Snyder, A. (2010). Visual memory improved by non-invasive brain stimulation. *Brain Research*, 1353, 168–175. doi:10.1016/j.brainres.2010.07.062

- Cotelli, M., Fertonani, A., Miozzo, A., Rosini, S., Manenti, R., Padovani, A., ... Miniussi, C. (2011). Anomia training and brain stimulation in chronic aphasia. *Neuropsychological Rehabilitation*, 21, 717–741. doi:10.1080/09602011.2011.621275
- Cotelli, M., Manenti, R., Cappa, S., Geroldi, C., Zanetti, O., Rossini, P., & Miniussi, C. (2006). Effect of transcranial magnetic stimulation on action naming in patients with Alzheimer disease. *Archives of Neurology*, 63, 1602–1604. doi:10.1001/archneur.63.11.1602
- Crepaldi, D., Berlinger, M., Paulesu, E., & Luzzatti, C. (2011). A place for nouns and a place for verbs? A critical review of neurocognitive data on grammatical-class effects. *Brain & Language*, 116, 33–49. doi:10.1016/j.bandl.2010.09.005
- Crinion, J., & Leff, A. (2007). Recovery and treatment of aphasia after stroke: Functional imaging studies. *Current Opinion in Neurology*, 20, 667–673. doi:10.1097/WCO.0b013e3282f1c6fa
- Crosson, B., Moore, A., Gopinath, K., White, K., Wierenga, C., Gaiefsky, M., ... Roth, L. J. G. (2005). Role of the right and left hemispheres in recovery of function during treatment of intention in aphasia. *Journal of Cognitive Neuroscience*, 17, 392–406. doi:10.1162/089929053279487
- Fernandez, B., Cardebat, D., Demonet, J., Joseph, P., Mazaux, J., Barat, M., & Allard, M. (2004). Functional MRI follow-up study of language processes in healthy subjects and during recovery in a case of aphasia. *Stroke*, 35, 2171–2176. doi:10.1161/01.STR.0000139323.76769.b0
- Finocchiaro, C., Maimone, M., Brighina, F., Piccoli, T., Giglia, G., & Fierro, B. (2006). A case study of primary progressive aphasia: Improvement on verbs after rTMS treatment. *Neurocase*, 12, 317–321. doi:10.1080/13554790601126203
- Fiori, V., Coccia, M., Marinelli, C., Vecchi, V., Bonifazi, S., Ceravolo, M., ... Marangolo, P. (2011). Transcranial direct current stimulation improves word retrieval in healthy and nonfluent aphasic subjects. *Journal of Cognitive Neuroscience*, 23, 2309–2323. doi:10.1162/jocn.2010.21579
- Fridriksson, J., Bonilha, L., Baker, J., Moser, D., & Rorden, C. (2010). Activity in preserved left hemisphere regions predicts anomia severity in aphasia. *Cerebral Cortex*, 20, 1013–1019. doi:10.1093/cercor/bhp160
- Giglia, G., Mattaliano, P., Puma, A., Rizzo, S., Fierro, B., & Brighina, F. (2011). Neglect-like effects induced by tDCS modulation of posterior parietal cortices in healthy subjects. *Brain Stimulation*, 4, 294–299. doi:10.1016/j.brs.2011.01.003
- Hamilton, R., Sanders, L., Benson, J., Faseyitan, O., Norise, C., Naeser, M., ... Coslett, H. B. (2010). Stimulating conversation: Enhancement of elicited propositional speech in a patient with chronic nonfluent aphasia following transcranial magnetic stimulation. *Brain and Language*, 113, 45–50. doi:10.1016/j.bandl.2010.01.001
- Hamilton, R. H., Chrysikou, G., & Coslett, B. (2011). Mechanisms of aphasia recovery after stroke and the role of noninvasive brain stimulation. *Brain & Language*, 118, 40–50. doi:10.1016/j.bandl.2011.02.005
- Heiss, W., & Thiel, A. (2006). A proposed regional hierarchy in recovery of post-stroke aphasia. *Brain and Language*, 98, 118–123. doi:10.1016/j.bandl.2006.02.002
- Hillis, A., Kleinman, J. T., Newhart, M., Heidler-Gary, J., Gottesman, R., Barker, P., ... Chaudhry, P. (2006). Restoring cerebral blood flow reveals neural regions critical for naming. *Journal of Neuroscience*, 26, 8069–8073. doi:10.1523/JNEUROSCI.2088-06.2006
- Jacobson, L., Koslowsky, M., & Lavidor, M. (2012). tDCS polarity effects in motor and cognitive domains: A meta-analytical review. *Experimental Brain Research*, 216, 1–10. doi:10.1007/s00221-011-2891-9
- Jung, I., Lim, J., Kang, E., Sohn, H., & Paik, N. (2011). The factors associated with good responses to speech therapy combined with transcranial direct current stimulation in post-stroke aphasic patients. *Annals of Rehabilitation Medicine*, 35, 460–469. doi:10.5535/arm.2011.35.4.460
- Jung, T. D., Kim, J. Y., Lee, Y. S., Kim, D. H., Lee, J. J., Seo, J. H., ... Chang, Y. (2010). Effect of repetitive transcranial magnetic stimulation in a patient with chronic crossed aphasia: fMRI study. *Journal of Rehabilitation Medicine*, 42, 973–978. doi:10.2340/16501977-0637
- Liebetanz, D., Nitsche, M. A., Tergau, F., & Paulus, W. (2002). Pharmacological approach to the mechanisms of transcranial DC-stimulation-induced after-effects of human motor cortex excitability. *Brain*, 125, 2238–2247. doi:10.1093/brain/awf238
- Manenti, R., Petesi, M., Brambilla, M., Rosini, S., Miozzo, A., Padovani, A., ... Cotelli, M. (2014). Efficacy of semantic-phonological treatment combined with tDCS for verb retrieval in a patient with aphasia. *Neurocase*. doi:10.1080/13554794.2013.873062
- Marangolo, P., Fiori, V., Cipollari, S., Campana, S., Razzano, C., Di Paola, M., ... Caltagirone, C. (2013). Bihemispheric stimulation over left and right inferior frontal region enhances recovery from apraxia of speech in chronic aphasia. *European Journal of Neuroscience*, 38, 3370–3377. doi:10.1111/ejn.12332
- Marangolo, P., Marinelli, C., Bonifazi, S., Fiori, V., Ceravolo, M., Provinciali, L., & Tomaiuolo, F. (2011). Electrical stimulation over the left inferior frontal gyrus (IFG) determines long-term effects in the recovery of speech apraxia in three chronic aphasics. *Behavioural Brain Research*, 225, 498–504. doi:10.1016/j.bbr.2011.08.008
- Marien, P., Paghera, B., De Deyn, P., & Vignolo, L. (2004). Adult crossed aphasia in dextrals revisited. *Cortex*, 40, 41–74. doi:10.1016/S0010-9452(08)70920-1
- Miceli, G., Laudanna, A., Burani, C., & Capasso, R. (1994). *Batteria per l'Analisi dei Deficits Afasici (BADA)*. Roma: CEPSAG.
- Miniussi, C., Cappa, S., Cohen, L., Floel, A., Fregni, F., Nitsche, M., ... Walsh, V. (2008). Efficacy of repetitive transcranial magnetic stimulation/transcranial direct current stimulation in cognitive neurorehabilitation. *Brain Stimulation*, 1, 326–336.
- Monti, A., Cogiamanian, F., Marceglia, S., Ferrucci, R., Mameli, F., Mrakic-Sposta, S., ... Priori, A. (2008). Improved naming after transcranial direct current stimulation in aphasia. *Journal of Neurology, Neurosurgery and Psychiatry*, 79, 451–453. doi:10.1136/jnnp.2007.135277
- Monti, A., Ferrucci, R., Fumagalli, M., Mameli, F., Cogiamanian, F., Ardolino, G., & Priori, A. (2013). Transcranial direct current stimulation (tDCS) and language. *Journal of Neurology, Neurosurgery and Psychiatry*, 84, 832–842. doi:10.1136/jnnp-2012-302825
- Naeser, M., Martin, P., Nicholas, M., Baker, E., Seekins, H., Kobayashi, M., ... Pascual-Leone, A. (2005). Improved picture naming in chronic aphasia after TMS to part of right Broca's area: An open-protocol study. *Brain and Language*, 93, 95–105. doi:10.1016/j.bandl.2004.08.004
- Naeser, M., Martin, P., Theoret, H., Kobayashi, M., Fregni, F., Nicholas, M., ... Pascual-Leone, A. (2011). TMS suppression of right pars triangularis, but not pars opercularis, improves naming in aphasia. *Brain and Language*, 119, 206–213. doi:10.1016/j.bandl.2011.07.005

- Nitsche, M., & Paulus, W. (2000). Excitability changes induced in the human motor cortex by weak transcranial direct current stimulation. *The Journal of Physiology*, 527, 633–639. doi:10.1111/j.1469-7793.2000.t01-1-00633.x
- Postman-Caucheteux, W., Birn, R., Pursley, R., Butman, J., Solomon, J., Picchioni, D., ... Braun, A. R. (2010). Single-trial fMRI shows contralesional activity linked to overt naming errors in chronic aphasic patients. *Journal of Cognitive Neuroscience*, 22, 1299–1318. doi:10.1162/jocn.2009.21261
- Rosen, H., Petersen, S., Linenweber, M., Snyder, A., White, D., Chapman, L., ... Corbetta, M. (2000). Neural correlates of recovery from aphasia after damage to left inferior frontal cortex. *Neurology*, 55, 1883–1894. doi:10.1212/WNL.55.12.1883
- Sandrini, M., Fertonani, A., Cohen, L., & Miniussi, C. (2012). Double dissociation of working memory load effects induced by bilateral parietal modulation. *Neuropsychologia*, 50, 396–402. doi:10.1016/j.neuropsychologia.2011.12.011
- Schlaug, G., Marchina, S., & Wan, C. (2011). The use of non-invasive brain stimulation techniques to facilitate recovery from post-stroke aphasia. *Neuropsychology Review*, 21, 288–301. doi:10.1007/s11065-011-9181-y
- Sparing, R., & Mottaghy, F. (2008). Noninvasive brain stimulation with transcranial magnetic or direct current stimulation (TMS/tDCS) – From insights into human memory to therapy of its dysfunction. *Methods*, 44, 329–337. doi:10.1016/j.ymeth.2007.02.001
- Thompson, C. K. (2004). Neuroimaging: Applications for studying aphasia. In L. L. La Pointe (Ed.), *Aphasia and related disorders* (pp. 19–38). New York, NY: Thieme.
- Turkeltaub, P. H., Coslett, B., Thomas, A., Faseyitan, O., Benson, J., Norise, C., & Hamilton, R. (2012). The right hemisphere is not unitary in its role in aphasia recovery. *Cortex*, 48, 1179–1186.
- Vines, B. W., Cerruti, C., & Schlaug, G. (2008). Dual-hemisphere tDCS facilitates greater improvements for healthy subjects' non-dominant hand compared to uni-hemisphere stimulation. *BMC Neuroscience*, 9, 345–352. doi:10.1186/1471-2202-9-103
- Vitali, P., Abutalebi, J., Tettamanti, M., Danna, M., Ansaldo, A., Perani, D., ... Cappa, S. F. (2007). Training-induced brain remapping in chronic aphasia: A pilot study. *Neurorehabilitation and Neural Repair*, 21, 152–160. doi:10.1177/1545968306294735
- Warburton, E., Price, C., Swinburn, K., & Wise, R. (1999). Mechanisms of recovery from aphasia: Evidence from positron emission tomography studies. *Journal of Neurology Neurosurgery and Psychiatry*, 66, 155–161. doi:10.1136/jnnp.66.2.155
- Whatmough, C., & Chertkow, H. (2002). Neuroanatomical aspects of naming. In A. E. Hillis (Ed.), *The handbook of adult language disorders* (pp. 143–161). New York, NY: Psychology Press.
- Xu, X. J., Zhang, M. M., Shang, D. S., Wang, Q., Luo, B., & Weng, X. (2004). Cortical language activation in aphasia: A functional MRI study. *Chinese Medical Journal*, 117, 1011–1016.
- You, D., Kim, D., Chun, M., Jung, S., & Park, S. (2011). Cathodal transcranial direct current stimulation of the right Wernicke's area improves comprehension in subacute stroke patients. *Brain & Language*, 119, 1–5. doi:10.1016/j.bandl.2011.05.002