

# Conduction Aphasia with Intact Visual Object Naming

Ajay Kumar Pandey, MD,\* † and Kenneth M. Heilman, MD\* †

**Abstract:** Conduction aphasia, most often caused by damage to the inferior parietal lobe and arcuate fasciculus, is usually characterized by mildly dysfluent speech with frequent phonemic paraphasic errors, impaired repetition, and impaired word finding and naming, but with relatively spared comprehension. We report an 86-year-old right-handed man with conduction aphasia caused by an infarction that damaged his right temporoparietal region. On testing with the Western Aphasia Battery, however, he named objects almost perfectly. To test his naming ability further, we showed him half the items in the Boston Naming Test; we described or defined the other half of the items, but did not show them to the patient. He performed excellently when naming the objects that he could see, but he had difficulty naming the objects that were only described or defined. These observations suggest that visual word naming may be mediated by a network that is somewhat independent of the networks that mediate spontaneous word finding and word finding based on verbal descriptions or definitions.

**Key Words:** speech, conduction aphasia, naming, visual object naming, stroke

(*Cogn Behav Neurol* 2014;27:96–101)

CT = computed tomography. **HAROLD** = hemispheric asymmetry reduction in older adults. **WAB-R** = Western Aphasia Battery–Revised.

In 1861, Paul Broca described a patient who had non-fluent speech, with impaired repetition and naming abilities, but who had relatively preserved speech comprehension. This syndrome is now known as Broca aphasia (Bastian, 1898; Mohr et al, 1978).

In his classic 1874 paper “Der aphasische Symptomenkomplex” [“The aphasic symptom complex”], Carl Wernicke described a man who had a stroke but,

unlike Broca’s patient, retained fluent speech. Wernicke’s patient could hear, but he could understand little of what was said to him. This syndrome of sensory aphasia came to be named after Wernicke.

Patients with Wernicke aphasia speak fluently but often make paraphasic errors, such as using incorrect words (semantic or verbal paraphasia), making phonological errors when speaking some words (phonemic or literal paraphasia), and even producing nonwords (neologisms). These patients also have impaired speech repetition, its severity often mirroring their impaired comprehension. Likewise, when asked to name objects, these patients often cannot produce the correct word and they make paraphasic and neologistic errors.

When Wernicke (1874) conducted an autopsy on his patient, he found a left hemisphere lesion with damage localized to the posterior part of the superior temporal gyrus, which is at the posterior end of the auditory acoustic zone.

In his 1874 paper, Wernicke posited that patients with this sensory aphasia are impaired at understanding speech because their injury has destroyed their memories of how words sound. He proposed that the brain area that stores word sounds is connected to the Broca area, which is important in producing word sounds (motor phonetic programming). This area, now called the *phonological lexicon*, is located in the posterior portion of the superior temporal gyrus.

If patients with injury to this phonological lexicon have an intact Broca area, they can fluently program the production of phoneme sequences. However, the words that the patients use are not constrained by lexical (word sound) knowledge, and so they make paraphasic errors and even speak in jargon (jargon aphasia).

Similarly, when trying to name or describe objects or actions, they cannot access their phonological lexicon, which contains the set of speech sounds and phoneme sequences that represent these objects and actions. With injury to this phonological lexicon, patients with Wernicke aphasia cannot comprehend speech and are often unaware that they are speaking incomprehensible jargon. Thus, they do not try to correct their speech errors.

In addition to describing this sensory aphasia, Wernicke suggested that injury to the connections between the posterior portion of the superior temporal gyrus (Wernicke area) and Broca area would also impair speech. That is, when trying to speak, patients with this disconnection should make phonological errors. However, unlike patients with sensory aphasia, who have lost their knowledge of word sounds (the phonological lexicon),

Received for publication February 3, 2013; accepted October 22, 2013. From the \*Department of Neurology, University of Florida College of Medicine, Gainesville, FL; and †Malcom Randall Veterans Affairs Medical Center, Gainesville, FL.

Present address: Ajay Kumar Pandey, Neuroscience Consultants, South Miami, FL.

The authors declare no conflicts of interest.

Reprints: Kenneth M. Heilman, MD, Box 100236, Department of Neurology, University of Florida College of Medicine, Gainesville, FL 32610-0236 (e-mail: heilman@neurology.ufl.edu).

Copyright © 2014 by Lippincott Williams & Wilkins

patients with a disconnection between the Wernicke and Broca areas should have intact memories of word sounds stored in their superior temporal gyrus and should still be able to comprehend speech. Therefore, these patients should be able to monitor their speech errors and may try to correct them. Wernicke (1874) called this theoretical disorder *Leitungsaphasie*—conduction aphasia.

Wernicke did not discuss impaired repetition in his paper. It was Lichtheim (1885) who first noted that patients with conduction aphasia have an impaired ability to repeat words spoken to them. In 1908, Wernicke also described the importance of defective repetition in conduction aphasia.

Kurt Goldstein (1912) also described conduction aphasia, which he called *central aphasia*. He proposed that central aphasia is a disturbance of “inner speech.” When speaking spontaneously, a person must find the words needed to express a concept. If people have impaired access to their word output pronouncing dictionary (the phonological output lexicon) when they try to express their thoughts in spontaneous speech, they may have difficulty finding words that represent their thoughts.

In addition to not being able to find the correct words, patients with conduction aphasia may make many literal (phonemic) paraphasic errors (Benson and Ardila, 1996). Although these patients may have impaired access to their phonological output lexicon, their ability to comprehend spoken words suggests that their phonological input lexicon is intact.

Feinberg et al (1986) tested the hypothesis that patients with conduction aphasia have an impairment of inner speech or of phonological output processing, but a preserved input lexicon. The researchers assessed 5 patients with conduction aphasia on their phonological knowledge about words that they could not say. The patients were shown pictures of objects and were asked to name each. If they could not say a target object’s name, they were shown pictures of other objects and were asked whether or not the name of each other object was homophonic with or rhymed with the name of the target object. Four of the 5 patients succeeded in making these phonological judgments on the names of seen objects that they could not speak. Thus, although they had impaired phonological output processing and could not say the names of many objects, they had an intact phonological knowledge of the object names (phonological input lexicon).

The brain damage that causes conduction aphasia in right-handed patients most often involves the left parietal lobe. Still, over the last half century, there has been much debate about the exact location of the critical lesion. Some investigators have suggested that it is the arcuate fasciculus (Berthier et al, 2012; Damasio and Damasio, 1980; Geschwind, 1965), and others that it is the cortex of the left posterior perisylvian region, including the supra-marginal gyrus, the posterior superior temporal lobe, and the insular cortex (island of Reil) (Anderson et al, 1999; Buchsbaum et al, 2011).

Recently, we evaluated a right-handed man with crossed conduction aphasia from a right hemisphere infarction. A behavioral dissociation that we found in his naming abilities might help us understand the different networks that may mediate naming and may be impaired in patients with aphasia.

## CASE REPORT

An 86-year-old right-handed white man had the sudden onset of a speech disorder and was admitted to the hospital for evaluation of a possible stroke. The patient reported being right-handed his entire life; he had never switched from preferring to use his left hand to using his right hand. He had been treated with warfarin for atrial fibrillation, but the drug had been stopped 2 weeks before his hospital admission. He had a history of congestive heart failure, and he had a cardiac pacemaker. He was also being treated for hypothyroidism, hypertension, and hyperlipidemia.

On physical examination at admission, the patient had a weight of 66 kg, height of 172.7 cm, and normal vital signs. Other than atrial fibrillation, he had a normal cardiac examination and normal breath sounds. He did not have any organomegaly. The rest of his general examination was normal.

On neurologic examination, he had mild left lower facial weakness and some hearing loss. His major problem was mildly dysfluent speech. He paused to search for words, and made phonemic and semantic paraphasic errors followed by *conduite approche* (repeated attempts to say the word correctly). When his hearing aid was working, he was able to follow 1-step commands, eg, “Please point to your television set,” but he was somewhat impaired at following commands that required several actions in sequence, eg, “Before pointing to the ceiling, please point to the door.”

When we said a word and asked him to repeat it, he continued to make frequent phonological paraphasic errors. However, when we placed objects before him and asked him to name them, he was almost always able to do so correctly and with only rare phonological or semantic paraphasic errors.

The hospital speech pathologists evaluated him with the Western Aphasia Battery–Revised (WAB-R) (Kertesz, 2007). The results are shown in Table 1. Four major language subtests are used to classify language deficits. Patients with conduction aphasia are most likely to have relatively fluent spontaneous speech and speech comprehension, but impaired repetition and naming. Based on our patient’s performance, the speech pathologists concluded that his clinical and WAB-R profile was most compatible with conduction aphasia.

To pursue our observation that his spontaneous word-finding ability was more impaired than his ability to name viewed objects, we gave him the Boston Naming Test (Kaplan et al, 1983), in 2 conditions. In the first condition, the examiner showed him each of the 30 pictures on the even-numbered pages of the Boston Naming

**TABLE 1.** This Patient’s Relevant Scores on the Western Aphasia Battery–Revised<sup>1</sup> During his Evaluation on Admission

Task	This Patient’s Score/ Highest Possible Score
<b>PART 1</b>	
<b>Spontaneous Speech</b>	
Information Content	9/10
Fluency, Grammatical Competence, and Paraphasias	6/10
<b>Auditory Verbal Comprehension</b>	
Yes/No Questions	57/60
Auditory Word Recognition	59/60
Sequential Commands	58/80
<b>Repetition</b>	50/100
<b>Naming</b>	
Object Naming	60/60
Word Fluency	13/20
Sentence Completion	8/10
Responsive Speech	10/10
<b>Scores for Aphasia Quotient</b>	
Spontaneous Speech	15/20
Auditory Verbal Comprehension	8.2/10
Repetition	5.0/10
Naming and Word Finding	9.1/10
<b>APHASIA QUOTIENT</b>	<b>74.6/100*</b>
<b>PART 2</b>	
<b>Reading</b>	
Reading Comprehension of Sentences	28/40
Reading Commands	20/20
Written Word Stimulus: Object Choice Matching	6/6
Written Word Stimulus: Picture Choice Matching	6/6
Picture Stimulus: Written Word Choice Matching	6/6
Spoken Words: Written Word Choice Matching	4/4
Letter Discrimination	6/6
Spelled Word Recognition	5/6
Spelling	6/6
<b>Writing</b>	
Writing on Request	6/6
Written Output	10/34
Writing to Dictation	3/10
Writing of Dictated or Visually Presented Words	6/10
Alphabet and Numbers	22/22.5
Dictated Letters and Numbers	6.5/7.5
Copying of Words of a Sentence	7/10
<b>LANGUAGE QUOTIENT†</b>	<b>76.8/100</b>

\*Scoring: 94-100 = normal. 76-93 = mild impairment. 51-75 = moderate impairment. 26-50 = severe impairment. 0-25 = very severe impairment. The patient’s score of 74.6 put him at the cutoff between mild and moderate impairment.

†The Language Quotient is calculated from scores from both Parts 1 and 2 of the Battery.

<sup>1</sup>Kertesz, 2007.

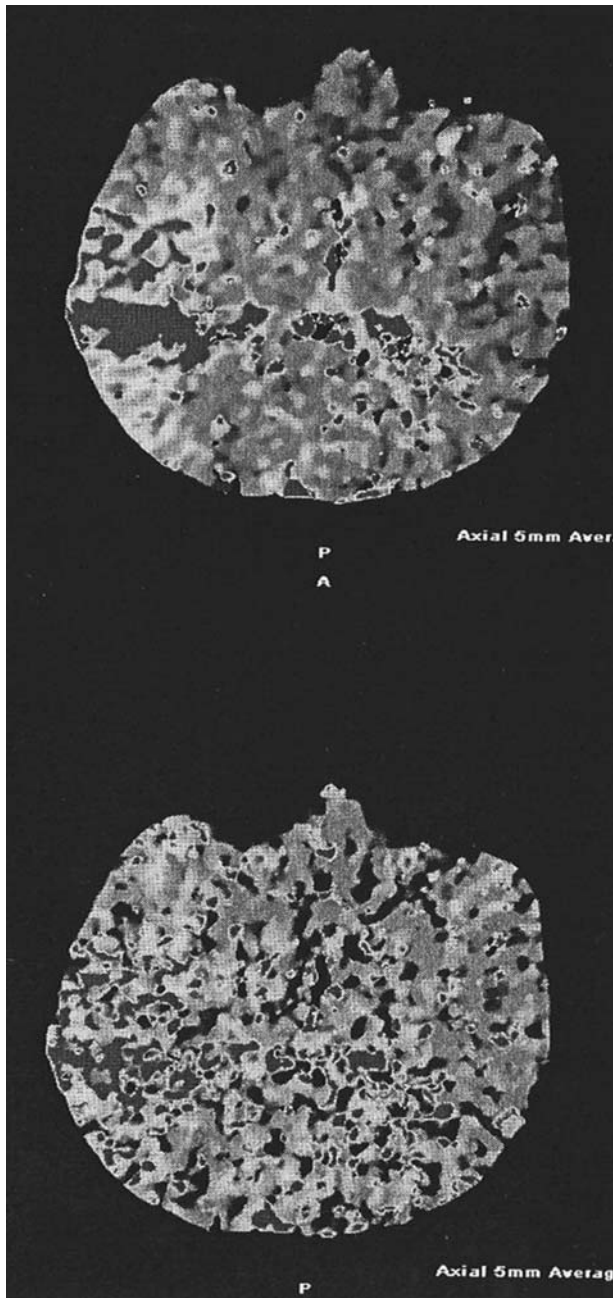
Test; after viewing each picture, he tried to name it. In the second condition, the examiner used the 30 pictures on the odd-numbered pages of the Boston Naming Test, but, rather than showing these pictures to the patient, the examiner only described or defined them, eg, “something used to sleep on.” After each description, the patient tried to name the object (eg, “bed”).

When the patient was allowed to view the pictures, he correctly named 28 of the 30. In contrast, when he tried to name the described or defined objects that he could not see, he correctly named only 14 of the 30. His errors were

primarily an inability to find the correct word. He rarely made phonological or semantic errors in either task.

When the speech pathologists retested his visual naming ability with the WAB-R, he performed perfectly.

Because the patient had a cardiac pacemaker, he could not undergo magnetic resonance imaging. Instead, 5 days after the onset of his symptoms, we obtained a computed tomogram (CT) and a CT angiogram of his brain. The CT did not show any lesions; however, the CT angiogram revealed an acute cutoff of the M1 segment of the right middle cerebral artery, with distal reconstitution



**FIGURE 1.** Representative slices from this patient's computed tomography angiogram, performed 5 days after his speech became impaired. Perfusion imaging shows abnormally prolonged time to peak perfusion in the right posterior temporal and temporoparietal region, corresponding to the vascular distribution of the posterior branches of the inferior division of the right middle cerebral artery.

of flow at the M1/M2 junction. The angiogram also showed a paucity of distal M3 and M4 branches in the right temporoparietal region. Densely calcified plaques involved both the cavernous internal carotid arteries and the carotid bulbs, but we did not see any flow-limiting stenosis. There were also extensive calcified atherosclerotic

plaques in his aortic arch and at the origin of the brachiocephalic artery, left common carotid artery, and left subclavian artery, but, again, without significant stenosis.

CT perfusion imaging revealed an abnormally prolonged time to peak perfusion in the right posterior temporal and temporoparietal region, corresponding to the vascular distribution of the posterior branches of the inferior division of the right middle cerebral artery (Figure 1).

## DISCUSSION

Despite his stroke, our patient retained almost perfect auditory word recognition and ability to give correct answers to questions requiring a “yes” or “no” response; however, on the WAB-R sequential command subtest, he performed only 58/80 commands correctly.

Many patients with conduction aphasia have impaired working memory (Heilman et al, 1976; Tzortzis and Albert, 1974). Our patient's poor performance on a digit span task indicates that his working memory was impaired. This impairment could help explain why he performed poorly on the WAB-R sequential verbal command subtest. Overall, his WAB-R performance pattern was compatible with conduction aphasia.

Most textbook descriptions of conduction aphasia mention that affected patients have impaired naming (Albert et al, 1981; Benson and Ardila, 1996). Our patient had impairments in name and word finding during spontaneous speech and when trying to name an object after hearing it described, but his picture-object naming was intact.

Alexander et al (1989) have noted reports of patients with conduction aphasia from right hemisphere lesions, a disorder that the authors call “mirror image crossed conduction aphasia.”

Berndt et al (1991) reported a patient with a right hemisphere posterior temporoparietal lesion who met the profile of conduction aphasia on the Boston Diagnostic Aphasia Examination. Although their paper focused on memory disorders, the authors wrote that their patient's confrontation naming was “relatively spared.” Berndt and colleagues did not try to learn if their patient had modality-specific impairments in naming.

Our patient did much better at naming pictures of objects than naming in response to a spoken definition or description. This dissociation in naming suggests that these 2 naming tasks may, at least in part, be mediated by 2 independent neuronal networks, 1 of which was impaired in our patient, and the other intact. Such a dual naming postulate is partly supported by the observation of 2 different forms of naming disorders, termed *optic aphasia* and *nonoptic aphasia*.

Patients with optic aphasia, originally described by Freund (1889), have a modality-specific anomia. Like patients with visual agnosia, patients with optic aphasia cannot name objects by sight. Unlike patients with visual agnosia, those with optic aphasia can correctly describe these objects and demonstrate how to use them, even though they cannot name them. When the same objects are presented in

other modalities, including touch, smell, and sound (eg, a car horn), patients can name them correctly (Heilman, 2006).

Freund posited a cause for optic aphasia: The visual cortex processes visual information but that visual information cannot reach the language areas located in the left hemisphere. According to Heilman's (2006) modified Wernicke-Kussmaul-Lichtheim language-speech processing model, optic aphasia could theoretically be explained by the visual association areas of the brain, which store the visual object recognition units, becoming disconnected or dissociated from the phonological output lexicon. Therefore, patients with this disconnection may still be able to have their visual object recognition units access their semantic-conceptual networks (Heilman, 2006).

Support for the postulate that object recognition units can get direct access to the phonological output lexicon without activating semantic-conceptual networks comes from a report of several patients with another form of aphasia, called *nonoptic aphasia* (Shuren et al, 1993). Patients with optic aphasia can name objects correctly in response to a definition, but cannot name objects presented visually. By contrast, patients with nonoptic aphasia can name visually presented objects correctly, but are severely impaired when trying to name the same objects in response to a definition. Unlike our patient, Shuren's patients with nonoptic aphasia could repeat sentences flawlessly, but they had impaired comprehension and they spoke semantic jargon.

Naming to definition, speech comprehension, and normal speech production all require an intact semantic-conceptual field. Thus, Shuren et al (1993) posited that their patients' nonoptic aphasia was probably caused by degradation of their semantic-conceptual networks. In contrast, the patients' preserved naming of seen objects suggests that the modular network composed of the visual object recognition units, phonological output lexicon, and phonetic programming apparatus were all connected and working properly. We suspect that our patient's left hemisphere may have contained this modular network.

Such a direct nonsemantic naming route is supported by the observation that normal people can readily learn and speak pseudo-names for viewed pseudo-objects. While the modified Wernicke-Kussmaul-Lichtheim information processing model (Heilman, 2006) can help explain both optic and nonoptic aphasia, the model has no theoretical lesion locus that could explain our patient's form of conduction aphasia.

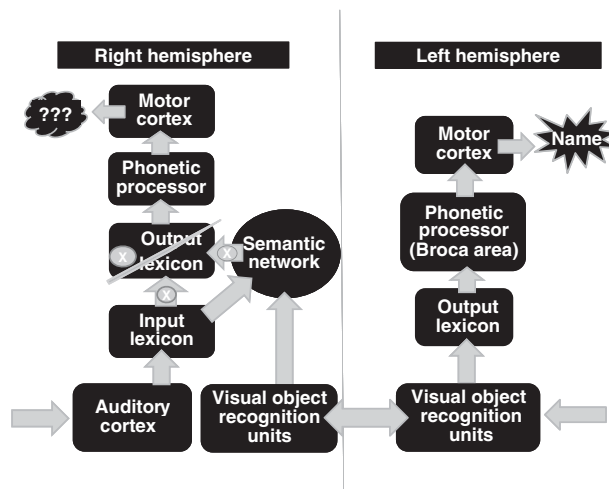
Thus, we propose that this right-handed man with conduction aphasia from a right hemisphere temporo-parietal infarction may be using both his right and left hemispheres to mediate speech. Although his right hemisphere may have a relatively intact semantic-conceptual network, his infarction may have injured his right hemisphere's output lexicon or access to this lexicon (Figure 2). Alternatively, his lesion may have impaired his postlexical processing (Wilshire and Coslett, 2000).

We suspect that our patient's intact right hemisphere input lexicon could still access his semantic-conceptual networks, thus allowing him to understand speech. Fur-

ther, we think that his impairment of speech repetition was related to his impaired output lexicon (or postlexical processing) such that his intact right hemisphere input lexicon could not activate his output lexicon normally (Figure 2). In contrast to his injured right hemisphere, his intact left hemisphere may have had a fully functioning object naming network consisting of the visual object recognition units, phonological output lexicon, and postlexical processing, including phonetic programming. Although his left hemisphere was uninjured, it may never have developed an input lexicon and thus could not perform tasks such as repetition (Katz and Goodglass, 1990).

Researchers have theorized that some people's right and left hemispheres may have different components or modules important in language and speech processing. For example, Bernal and Ardila (2009) noted unusual patients whose Broca area appeared to be in the left hemisphere and whose Wernicke area appeared to be in the right hemisphere. In another study, Lidzba et al (2011) found through functional imaging that 24% of children and young adults had language comprehension and production mediated by different hemispheres.

As for our patient, it is possible that his input lexicon (Wernicke area) was located in his right hemisphere (Figure 2).



**FIGURE 2.** Diagram of our patient's right and left hemisphere speech-language modular networks. The patient's right hemisphere injury appeared to have either damaged his phonological output lexicon (marked by a long slash) or impaired access to this lexicon (marked by arrows with a white X). His auditory cortex could gain access to an intact input lexicon, and this lexicon could access semantics. Therefore, he could comprehend. Because his intact right hemisphere input lexicon could not access his output lexicon, he was impaired at repetition. During spontaneous speech and naming to verbal definition, he had word-finding difficulties, primarily anomia, because his semantic network could not access his output lexicon. In contrast, his left hemisphere had an intact output lexicon. His visual object recognition units could recognize seen objects and could access the left hemisphere's output lexicon, thus allowing him to name viewed objects.

While our patient may have had this unusual brain organization his entire adult life, there is an alternative possibility, which has to do with his age. He was 86 years old when he had the stroke that induced his conduction aphasia with intact picture naming. In 2002, Cabeza introduced a model of how the brain may change with aging. He called this model “HAROLD,” for “hemispheric asymmetry reduction in older adults.” HAROLD proposes that cognitive performance tends to be less lateralized in older adults than in younger adults. The age-related alterations of hemispheric asymmetries may relate to a compensatory mechanism or may reflect a de-differentiation process. Support for Cabeza’s model has come primarily from studies using functional neuroimaging (Woodard and Sugarman, 2012).

Although it is possible that our right-handed patient’s conduction aphasia from a right hemisphere lesion could be explained by the HAROLD model, there is evidence against it. For instance, Nocentini et al (1999) studied patients with right hemisphere damage and did not find that age influenced their language impairments and other types of deficits.

Another challenge to HAROLD explaining our patient’s aphasia being caused by a right hemisphere infarction comes from studies of patients with Wernicke aphasia. These studies have revealed that with left hemisphere lesions, Wernicke aphasia is more common in older than younger patients (Basso et al, 1980; Knepper et al, 1989). Therefore, if the right hemisphere plays a greater role in language as people age, then older patients should have a lower incidence of Wernicke aphasia. Our patient, however, did not have Wernicke aphasia, which would have been caused by injury to his input lexicon, but rather appeared to have injury to either his output lexicon or the access to this lexicon. It remains possible that with aging, this lexicon is more likely to be in the right hemisphere.

Although right-handed patients with crossed aphasia are uncommon, future studies of older patients may be able to test further the HAROLD postulate of the output lexicon. Functional imaging studies may also help us learn if and how word finding, naming to definition, and naming pictures use different networks in younger versus older people.

#### ACKNOWLEDGMENT

The authors thank the anonymous reviewers for their insightful comments.

#### REFERENCES

- Albert ML, Goodglass H, Helm NA, et al. 1981. *Clinical Aspects of Dysphasia*. Vienna: Springer-Verlag.
- Alexander MP, Fischette MR, Fischer RS. 1989. Crossed aphasias can be mirror image or anomalous. Case reports, review and hypothesis. *Brain*. 112:953–973.
- Anderson JM, Gilmore R, Roper S, et al. 1999. Conduction aphasia and the arcuate fasciculus: a reexamination of the Wernicke-Geschwind model. *Brain Lang*. 70:1–12.
- Basso A, Capitani E, Laiacoma M, et al. 1980. Factors influencing type and severity of aphasia. *Cortex*. 16:631–636.
- Bastian HC. 1898. *A Treatise on Aphasia and Other Speech Defects*. London: H.K. Lewis.
- Benson DF, Ardila A. 1996. *Aphasia: A Clinical Perspective*. New York: Oxford University Press.
- Bernal B, Ardila A. 2009. The role of the arcuate fasciculus in conduction aphasia. *Brain*. 132:2309–2316.
- Berndt RS, Mitchum CC, Price TR. 1991. Short-term memory and sentence comprehension. An investigation of a patient with crossed aphasia. *Brain*. 114:263–280.
- Berthier ML, Lambon Ralph MA, Pujol J, et al. 2012. Arcuate fasciculus variability and repetition: the left sometimes can be right. *Cortex*. 48:133–143.
- Broca P. 1861. Remarques sur le siège de la faculté du langage articulé, avec deux observations d’aphémie [Comments on the site of the faculty for speech, followed by an observation of aphemia]. *Bull Soc Anat*. 6:330–357.
- Buchsbaum BR, Baldo J, Okada K, et al. 2011. Conduction aphasia, sensory-motor integration, and phonological short-term memory: an aggregate analysis of lesion and fMRI data. *Brain Lang*. 119:119–128.
- Cabeza R. 2002. Hemispheric asymmetry reduction in older adults: the HAROLD model. *Psychol Aging*. 17:85–100.
- Damasio H, Damasio AR. 1980. The anatomical basis of conduction aphasia. *Brain*. 103:337–350.
- Feinberg TE, Gonzalez Rothi LJ, Heilman KM. 1986. “Inner speech” in conduction aphasia. *Arch Neurol*. 43:591–593.
- Freund CS. 1889. Ueber optische Aphasie und Seelenblindheit [On optic aphasia and visual agnosia]. *Arch Psychiatr Nervenkr*. 20:276–297, 371–416.
- Geschwind N. 1965. Disconnection syndromes in animals and man. *Brain*. 88:237–294, 585–644.
- Goldstein K. 1912. Die Zentral Aphasie [Central aphasia]. *Neurol Zentralbl*. 12:739–751.
- Heilman KM. 2006. Aphasia and the diagram makers revisited: an update of information processing models. *J Clin Neurol*. 2:149–162.
- Heilman KM, Scholes R, Watson RT. 1976. Defects of immediate memory in Broca’s and conduction aphasia. *Brain Lang*. 3:201–208.
- Kaplan E, Goodglass H, Weintraub S. 1983. *The Boston Naming Test*. Philadelphia, PA: Lea & Febiger.
- Katz RB, Goodglass H. 1990. Deep dysphasia: analysis of a rare form of repetition disorder. *Brain Lang*. 39:153–185.
- Kertesz A. 2007. *Western Aphasia Battery—Revised*. San Antonio, TX: Harcourt Assessment.
- Knepper LE, Biller J, Tranel D, et al. 1989. Etiology of stroke in patients with Wernicke’s aphasia. *Stroke*. 20:1730–1732.
- Lichtheim L. 1885. On aphasia. *Brain*. 7:433–484.
- Lidzba K, Schwilling E, Grodd W, et al. 2011. Language comprehension vs. language production: age effects on fMRI activation. *Brain Lang*. 119:6–15.
- Mohr JP, Pessin MS, Finkelstein S, et al. 1978. Broca aphasia: pathologic and clinical. *Neurology*. 28:311–324.
- Nocentini U, Goulet P, Drolet M, et al. 1999. Age-related evolution of the contribution of the right hemisphere to language: absence of evidence. *Int J Neurosci*. 99:59–67.
- Shuren J, Geldmacher D, Heilman KM. 1993. Nonoptic aphasia: aphasia with preserved confrontation naming in Alzheimer’s disease. *Neurology*. 43:1900–1907.
- Tzortzis C, Albert ML. 1974. Impairment of memory for sequences in conduction aphasia. *Neuropsychologia*. 12:355–366.
- Wernicke C. 1874. *Der aphasische Symptomenkomplex [The Symptom Complex of Aphasia]*. Breslau: Cohn und Weigert.
- Wernicke C. 1908. The symptom-complex of aphasia. In: Church A, ed. *Modern Clinical Medicine: Diseases of the Nervous System* (an authorized translation from “Die Deutsche Klinik,” under the general editorial supervision of Dr. Julius L. Salinger). New York: Appleton.
- Wilshire CE, Coslett HB. 2000. Disorders of word retrieval in aphasia: theories and potential applications. In: Nadeau SE, Gonzalez-Rothi LJ, Crosson BA, eds. *Aphasia and Language: Theory to Practice*. New York: The Guilford Press; 82–107.
- Woodard JL, Sugarman MA. 2012. Functional magnetic resonance imaging in aging and dementia: detection of age-related cognitive changes and prediction of cognitive decline. *Curr Top Behav Neurosci*. 10:113–136.