


# Phenotypic Analysis of Epilepsy in the Mitochondrial Encephalomyopathy, Lactic Acidosis, and Strokelike Episodes–Associated Mitochondrial DNA A3243G Mutation

Journal of Child Neurology  
2014, Vol. 29(9) 1249–1256  
© The Author(s) 2014  
Reprints and permission:  
sagepub.com/journalsPermissions.nav  
DOI: 10.1177/0883073814538511  
jcn.sagepub.com  


Scott T. Demarest, MD<sup>1</sup>, Matthew T. Whitehead, MD<sup>1</sup>,  
Sinan Turnacioglu, MD<sup>1</sup>, Phillip L. Pearl, MD<sup>2</sup>, and Andrea L. Gropman, MD<sup>1</sup>

## Abstract

The A to G mitochondrial DNA point mutation at position 3243 (A3243G) is the most common cause of mitochondrial encephalomyopathy, lactic acidosis, and strokelike episodes (MELAS), a systemic multiorgan disease. Epilepsy is a common finding but there is wide phenotypic variation that has not been thoroughly explored. We report the epilepsy phenotypes of 7 patients with the A3243G mutation. Most presented with typical MELAS and epilepsy characterized by infrequent prolonged focal seizures, including *epilepsia partialis continua*, hemiclonic status epilepticus, nonconvulsive status, and occipital status epilepticus. Seizures usually occurred during the acute phase of a strokelike episode. Periodic lateralized epileptiform discharges may be seen electrographically. Some patients with this mutation are completely asymptomatic or have mild symptoms typical for mitochondrial diseases. Slow spike-wave activity consistent with Lennox-Gastaut syndrome and electrographic status epilepticus was seen in 1 patient who responded to ethosuximide.

## Keywords

electroencephalogram, Lennox-Gastaut syndrome, mitochondria, seizures

Received May 06, 2014. Received revised May 06, 2014. Accepted for publication May 06, 2014.

Mitochondrial encephalomyopathy, lactic acidosis, and stroke-like episodes (MELAS) is a systemic disease with multiorgan involvement and varied phenotypes. The most common mutation associated with MELAS is the A to G point mutation in the mitochondrially encoded tRNA leucine 1<sup>(UUA/G)</sup> (*MT-TL1*) gene at position 3243 (A3243G) within mitochondrial DNA.<sup>1,2</sup> Because of significant heteroplasmy, this mutation can result in a wide variety of phenotypes that range from asymptomatic to severely affected patients.<sup>3</sup> MELAS is a severe progressive encephalomyopathy characterized by strokelike episodes that generally result in a stepwise decline in neurologic function. Most MELAS patients have epilepsy that may be severe and medically refractory, contributing substantially to morbidity. In the original description by Pavlakis and colleagues, all 11 patients had epilepsy, 9 of which were focal in origin.<sup>4</sup>

No specific electroencephalographic (EEG) characteristics are pathognomonic for MELAS. EEG in MELAS patients can be normal during healthy periods or may demonstrate focal or multifocal epileptiform abnormalities. This may be associated with focal or generalized slowing.<sup>1,5-7</sup> EEGs tend to be more abnormal during strokelike episodes than between them. Polyspike and wave discharges<sup>8</sup> and photoparoxysmal responses<sup>9</sup> have been reported. Periodic lateralized epileptiform discharges

can be seen with prolonged seizures and strokelike episodes.<sup>5,10-13</sup> Periodic lateralized epileptiform discharges are generally associated with a clinical change suggesting an ictal phenomenon but also may be asymptomatic.

Seizures are nearly always focal and often hemiconvulsive<sup>8</sup> and may secondarily generalize. Pavlakis and colleagues originally described 2 patients with generalized myoclonus<sup>4</sup>; however, there is no other reference to generalized epilepsy in the subsequent literature. Canafoglia and colleagues evaluated 31 patients with mitochondrial encephalopathies (5 with MELAS) and found generalized myoclonic seizures were only associated with myoclonus epilepsy with ragged red fibers.<sup>9</sup> Most seizures

<sup>1</sup> Children's National Medical Center, The George Washington University School of Medicine, Washington, DC, USA

<sup>2</sup> Department of Neurology, Boston Children's Hospital, Harvard Medical School, Boston, MA, USA

## Corresponding Author:

Andrea L. Gropman, MD, Division of Neurogenetics and Developmental Pediatrics, Children's National Medical Center, 111 Michigan Avenue NW, Washington, DC 20010, USA.

Email: AGropman@childrensnational.org

in MELAS are associated with strokelike episodes, but breakthrough seizures can occur between episodes, which are often shorter.<sup>11</sup> Overall, the literature supports posterior seizure onset, consistent with a predilection for strokelike episodes to occur in these locations.<sup>6,12,14</sup>

Various types of prolonged focal seizures have been reported in association with MELAS. In some cases, these were associated with periodic lateralized epileptiform discharges, as described above,<sup>5,10-13</sup> and in other cases, with frequent recurrent seizures without return to baseline. The exact phenotype of the prolonged focal seizure is likely a function of the origin of the seizure. Epilepsia partialis continua is commonly described in association with strokelike episodes involving the motor strip and is characterized by persistent focal motor seizures with retained consciousness.<sup>4,7,13</sup> Complex partial status epilepticus with behavioral arrest or dyscognitive symptoms in association with epileptiform activity on EEG also has been reported.<sup>5,13</sup> This phenotype likely has some overlap with nonconvulsive status epilepticus, which was found in a patient with MELAS presenting with psychiatric disturbance and aggressive behavior.<sup>1</sup> Occipital status epilepticus that presented with visual hallucinations also has been reported.<sup>6,15</sup> These prolonged focal seizures can progressively generalize, causing varying degrees of interruption of cognition or full secondarily generalized seizures.

Since the original description of MELAS 30 years ago, a number of publications have clarified associated epilepsy characteristics. The typical picture that has evolved depicts patients with MELAS as having a predilection to develop prolonged focal seizures associated with strokelike episodes.<sup>1,5-8,12,15</sup> The majority of the literature consists of single case reports, with a few case series that describe the epilepsy characteristics of patients with a variety of mitochondrial cytopathies, some of whom had MELAS.<sup>9,16</sup> There has also been 1 case series of 4 MELAS patients characterizing their episodes of status epilepticus; 3 of the 4 patients harbored the mtA3243G mutation.<sup>13</sup> The literature nonetheless leaves the practitioner with many questions about the phenotypic spectrum of epilepsy and the relationship between the epilepsy and strokelike episodes experienced by these patients.

In this paper, we analyze the phenotypic features of 7 patients with the classic mtA3243G mitochondrial mutation associated with MELAS, with focus on the epilepsy and EEG characteristics. It is notable that not all patients with this mutation suffer strokelike episodes or have epilepsy. These patients demonstrate this mutation's phenotypic variation.

## Methods

A retrospective chart review was obtained for EEG characteristics, seizure description, magnetic resonance imaging (MRI), and magnetic resonance spectroscopy, and developmental assessments for patients with the MELAS-associated mtA3243G gene mutation. EEG reports were reviewed for the presence of generalized versus focal slowing, overall background organization, and epileptiform activity, including location, frequency, morphology, and persistence. Sleep architecture and abnormalities were noted as well as any overall characteristics that suggested particular electroclinical syndromes. The EEG findings

were placed in the context of clinical seizure phenotypes and any association with strokelike episodes both temporally and in terms of the overall severity of MELAS as determined by an MRI-based disease severity score. This was further correlated with neurocognitive assessments and progression.

MRI was performed on either 1.5- or 3-Tesla scanners (General Electric, Milwaukee, WI) at various time points during both clinically active and quiescent disease in all patients. Prescribed pulse sequences included axial T<sub>2</sub>-weighted imaging, axial T<sub>2</sub> fluid-attenuated inversion recovery imaging, coronal T<sub>2</sub>-weighted imaging, sagittal T<sub>1</sub>-weighted imaging, axial diffusion-weighted imaging/diffusion tensor imaging, and single-voxel point-resolved MR spectroscopy with voxel of interest placed over the left basal ganglia. The most recent MR exam in each patient was scored by a point system developed to quantitatively evaluate disease severity. A severity score (0-100) was calculated from each patient's brain MR using the following metrics: brain volume loss (location and degree), signal abnormality (type and extent), and the presence or absence of elevated lactate based on MR spectroscopy (Table 1).

As brain parenchymal volume loss tends to progress over the disease course, the most remote available exam was used as an internal baseline to aid in the subjective assessment of volume loss. Extent of brain signal abnormality affecting the cortex/subcortical white matter in the cerebrum and cerebellum and total area of signal abnormality in the brainstem were subjectively graded in range percentiles. T<sub>2</sub> prolongation without signal suppression on T<sub>2</sub> fluid-attenuated inversion recovery images and without accompanying diffusion restriction in areas of brain volume loss was considered encephalomalacia/gliosis from prior injury. Hyperintense signal on T<sub>2</sub>-weighted imaging with any areas of T<sub>2</sub> fluid-attenuated inversion recovery signal suppression and no restricted diffusion in areas of volume loss was considered more advanced disease, representing encephalomalacia/gliosis with necrosis. MRI was available for patients 1 through 4. (Specific rating for each patient by regions of interest is available online as a supplement at [jcn.sagepub.com/supplemental](http://jcn.sagepub.com/supplemental))

## Results

### Patient Histories

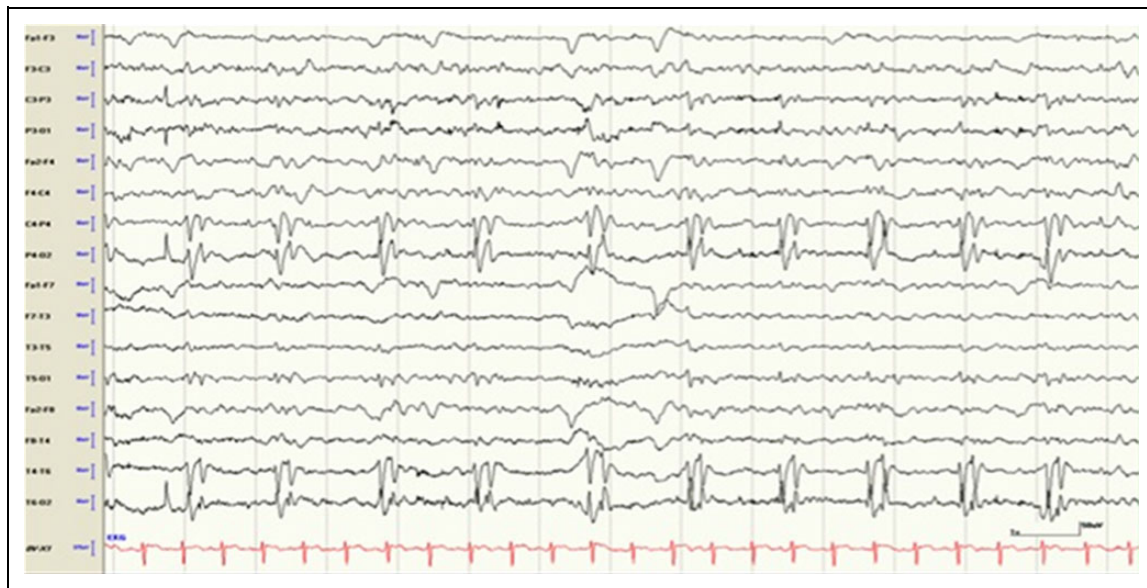**Patient 1.** This patient was healthy until 14 years of age, when she presented with bilateral clonic seizures that were relatively short and had a tendency to cluster, up to 8 in 1 day. She was initially placed on carbamazepine, and then transitioned to levetiracetam because of treatment-limiting side effects. The seizures occurred sporadically over the first 9 months, with no more than 1 per month. Just after she turned 15 she had repeat MRI because of ongoing seizures, which identified subacute strokelike findings of at least 2 different ages, leading to the diagnosis of MELAS. The patient was placed on mitochondrial vitamin supplements that included arginine and was continued on levetiracetam over the following 2 years, during which her disease was relatively quiescent.

She suffered no identified strokelike episodes or seizures until she was 17 years old, when she presented with brief focal seizures with alteration of consciousness that clustered but were easily aborted. She was found to have both acute and subacute MRI changes at this time. She went on to have 2 more strokelike episodes during the subsequent 6 months. The first was also associated with a focal seizure and an EEG that was

**Table 1.** EEG Findings in our Cohort of MELAS Patients.

Patient number	Current age (y)	EEG findings							Seizures			MRI-based MELAS severity score	Developmental outcomes to date
		Background organization	Sleep	Background slowing		Epileptiform discharges		Status epilepticus	Seizure types	Between stroke-like episodes	Electroclinical syndrome		
				Focal	Generalized	Focal	Generalized						
1	20	Excess beta	–	Posterior	Mild at times	Left occipital, bifrontal	–	OSE, EPC	Focal	During only	None	52	Cognitive impairment; receptive expressive language disorder; impaired visual-motor skills; impaired working memory and processing speed; mood disorder
2	11	–	–	Left posterior, right parietal	Mild at times	Left posterior	–	Hemiclonic status	Focal	During only	None	43	Language disorder/fluent aphasia; motor dyspraxia
3	17	Poor	Poor	Various at different times	Mild/moderate, FIRDA	MF, PLEDs	–	NCS, OSE	Focal	Both	None	36	Cognitive impairment; receptive expressive language disorder; deficits in attention and executive function
4	12	Excess beta	ESES, no spindles	–	Mild at times	MF (O/P)	0.5-2 Hz SSW, PSW, PFA	SWS	Focal, BA Tonic	No SLEs	LGS	0	Receptive expressive language disorder; learning disorder; ADHD; anxiety
5	13	–	–	–	–	–	–	No	Focal	During only	None	3 strokes, no MRI available	Cognitive impairment; mixed receptive expressive and pragmatic language disorder; ADHD; disruptive behavior disorder; dysgraphia
6	11	–	–	–	–	–	–	None	None	None	None	N/A	Deficit in processing speed; speech disarticulation; deficit in fine motor skills
7	39	–	–	–	–	–	–	None	None	None	None	N/A	N/A

Abbreviations: BA, behavioral arrest; EPC, epilepsy partialis continua; ESES, electrographic status epilepticus in sleep; FIRDA, frontal intermittent recurrent delta activity; LGS, Lennox-Gastaut syndrome; MELAS, mitochondrial encephalomyopathy, lactic acidosis, and stroke-like episodes; MF, multifocal; OSE, occipital status epilepticus; PFA, paroxysmal fast activity; PLEDs, periodic lateralized epileptiform discharges; PSW, polyspike and wave; SSW, slow spike and wave; SWS, spike wave stupor.



**Figure 1.** Standard EEG recording in a bipolar montage demonstrating right occipital periodic lateralized epileptiform discharges associated with occasional visual phenomenon in patient 3.

unremarkable. The last stroke that year was associated with a clinical event characterized by retained consciousness, diffuse shaking, and horizontal headshaking. The patient was subsequently found to have a homonymous hemianopia, and an acute metabolic stroke was identified in the contralateral posterior cerebral artery territory on MRI.

At 18 years of age she had a prolonged focal seizure with alteration of consciousness that evolved into complex partial status epilepticus with more than 70 electrographic seizures in 1 day. These had variable clinical accompaniment, and evolved into periodic left occipital discharges that remained prominent for 48 hours, during which the patient complained intermittently of visual hallucinations. The diagnosis was occipital status epilepticus associated with a left occipital metabolic stroke.

The patient had further occasional breakthrough seizures, precipitated by acute illnesses, and at age 20 developed left-sided *epilepsia partialis continua* clinically associated with right posterior EEG discharges. MRI revealed multiple areas of acute stroke, predominantly in the right hemisphere. At the time of publication, this patient had an MRI disease severity score of 52, the highest of any patients in our cohort, representing the accumulation of multiple large territories of infarction in different stages of evolution.

**Patient 2.** This patient presented at age 9 years with hemiclonic status epilepticus and progression to multiple convulsive and nonconvulsive seizures associated with an acute stroke-like episode. She was placed on levetiracetam without seizure recurrence. She had at least 2 additional acute metabolic strokes over 2 years that involved multiple areas and required substantial rehabilitation but were not associated with clinical seizures. At the time of publication, this patient was 11 years old and had a disease severity score of 43, which is the second worst in our

cohort despite her relatively young age. She suffered limited complications from epilepsy.

**Patient 3.** In the early school-age period, this patient developed decreasing school performance and failure to thrive. Seizure onset was at age 14 years. Imaging showed calcifications of the basal ganglia and thalamus without evidence of cortical infarct. He was subsequently diagnosed with hearing loss and confirmed to have MELAS. Clusters of unilateral motor seizures with headache ensued, followed by nonconvulsive status epilepticus. EEG demonstrated periodic lateralized epileptiform discharges of 5 days' duration (Figure 1). Antiepileptic drug management included levetiracetam, lacosamide, phenobarbital, and topiramate.

Ultimately, there were recurrent stroke-like episodes, with clinical accompaniment including acute-onset visual loss and headache. Seizures occurred independently of stroke-like episodes with the semiology of behavioral arrest, eye fluttering, head deviation, and secondarily generalized convulsions. EEG findings were very frequent multifocal interictal epileptiform discharges and periodic complexes without clear clinical correlate. The patient had an MRI-based disease severity score of 36 at the age of 18 years.

**Patient 4.** An international adoptee from a Chinese orphanage at age 9 months, this patient had early expressive language delay and was otherwise well until age 9 years. She then developed recurrent headaches with emesis followed by disorientation. Following a first-time seizure, MRI was normal but EEG showed virtually continuous, high-amplitude 0.5- to 2.5-Hz generalized spike or polyspike and slow-wave discharges with posterior predominance and some increased right-sided involvement. She was started on valproate initially but transitioned to lamotrigine after the discovery of the mitochondrial DNA



short list of causes of periodic lateralized epileptiform discharges in children. An MRI finding consistent with a metabolic stroke in this setting is highly suggestive of the diagnosis. Additionally, a history of multiorgan dysfunction or subtle developmental delay may be explored.

The mechanism of status epilepticus in MELAS is postulated to involve a cycle developing after an inciting event causing a stroke-like episode, which may in turn trigger a seizure, thereby increasing metabolic demand, further straining energy metabolism, and resulting in increased cell injury.<sup>17-19</sup> This may also start with a seizure and lead to metabolic decompensation and stroke-like episode. Fever, glycemic alterations, and headache have been implicated as such triggers.<sup>13</sup> L-Arginine may be useful in the treatment of status epilepticus in MELAS.<sup>15,20</sup> Oral L-arginine given in the first 30 minutes of stroke-like episodes may reduce progression of symptoms.<sup>21</sup>

### Epilepsy Phenotypes

The patients within our cohort had very different epilepsy phenotypes. Patients 1 and 2 had a small number of lifetime seizures that were nearly all associated with acute stroke-like episodes. Most seizures were either prolonged or occurred in clusters. These patients had the highest MRI-based disease severity scores in the cohort but had relatively minimal epileptic burden between stroke-like episodes. Patient 3 had frequent stroke-like episodes often associated with prolonged seizures and also had refractory epilepsy between stroke-like episodes. Additionally, his periodic lateralized epileptiform discharges were not isolated to the time around stroke-like episodes. Admittedly, his epilepsy severity between stroke-like episodes progressed as he accumulated brain injury. However, this alone does not explain this phenotypic difference, as patients 1 and 2 had more accumulation of disease based on the MRI severity scores than patient 3 and had little to no seizures outside of their stroke-like episodes.

Patient 4 presented a phenotype of an epileptic encephalopathy, first with electrographic status epilepticus in sleep and then Lennox-Gastaut syndrome. She suffered very frequent seizures and episodes of generalized spike wave associated with stupor. This improved dramatically with the introduction of ethosuximide, with associated cognitive improvement. Despite this active epilepsy, she never had a clear stroke-like episode. Patients 4 and 6 are still quite young and could develop stroke-like episodes.

Although neither MELAS nor the mtA3243G mutation has been classically associated with Lennox-Gastaut syndrome or electrographic status epilepticus in sleep, there is growing evidence that mitochondrial dysfunction may play a disease-modifying role in association with other mutations more classically associated with epileptic encephalopathy.<sup>22,23</sup> Furthermore, Lee and colleagues described a series of 48 epilepsy patients with suspected mitochondrial disease who had greater than 20% reduced function of 1 of complex I through complex IV of the electron transport chain. One patient of the 48 was ultimately diagnosed with MELAS and 12 of the 48 had

electroclinical syndromes consistent with Lennox-Gastaut syndrome. It is unclear from the report what, if any, identifiable electroclinical syndrome would apply to the patient with MELAS.<sup>16</sup> In either case, patient 4 in the present report serves to expand the phenotypic spectrum of epilepsy associated with the mtA3243G mitochondrial DNA mutation.

### Relationship Between Seizures and Metabolic Strokes

Prolonged focal seizures in a patient with MELAS are highly concerning for an acute metabolic stroke. However, 2 of the patients in our series suffered severe and in some cases prolonged seizures and epileptiform activity without evidence for metabolic infarcts. This is a fertile area for future investigation to identify protective or predisposing mechanisms of energy failure in patients with the same mutation.

Although the relationship between seizures and stroke-like episodes is variable between patients with MELAS, it is fairly well conserved within individuals. This is a useful observation for clinical practice; patients in our study tended to divide early into a group that always had stroke-like episodes with seizures and a group that had frequent seizures not associated with such events. However, it is prudent in the early stages of disease before a pattern is well developed to treat all patients aggressively for possible metabolic stroke given the debilitating neurocognitive toll.

All of our patients who suffered a seizure were placed on daily antiepileptic medication, yet some of these patients only suffered seizures during stroke-like episodes. Patient 5 was started on a new antiepileptic medication with each new stroke-like episode, yet never experienced a seizure between these episodes. It remains unclear whether long-term and polydrug therapy provides additional benefit in patients who only have seizures during such episodes. Alternatively, seizure prophylaxis may be important to reduce the risk of seizures triggering a stroke-like episode. Large multicenter trials are necessary to address this question.

Both the MRI analysis and EEG findings of focal slowing and epileptiform abnormalities support preferential involvement of the posterior cortical areas, as reported by others.<sup>6,12,14</sup> Even patient 4 who reported no definite stroke-like episode had many focal electrographic abnormalities that localized to the posterior regions when not generalized.

### Neurocognitive Characteristics

All patients who suffered stroke-like episodes experienced a stepwise decline in cognitive function consistent with the progressive degenerative nature of MELAS. One patient (patient 4) presented with epileptic encephalopathy and demonstrated improvement after initiation of effective antiepileptic drug therapy. In our series of 6 patients with symptomatic mtA3243G mutations, only 2 (patients 1 and 2) were not reported to have subtle abnormalities in speech or motor development preceding the onset of either seizures or stroke-like episodes.

Although the cognitive impairment identified in some patients in this series has been described in the literature as a feature of MELAS, several patients were also found to have other neurodevelopmental outcomes, including mixed receptive-expressive language disorder, executive dysfunction, and anxiety.<sup>4,24</sup>

This cohort of 7 patients with mtA3243G mutation demonstrate the wide phenotypic variation that can be seen with this mutation. Although 2 of our patients with the highest burden of strokelike episodes had mild epilepsy, another patient who has not had any strokelike episodes to date suffers from severe epileptic encephalopathy with generalized manifestations that responded to ethosuximide. Of 2 sisters who both had 100% homoplasmy, one had a fairly classic picture of MELAS whereas the other had minor developmental delay and fatigability. Another patient remained asymptomatic. This establishes the range of phenotypes associated with the mtA3243G mutation.

### Authors' Note

This work was presented in part at the 2013 Neurobiology of Disease in Children Symposium: Mitochondrial Disease, held in conjunction with the 42nd Annual Meeting of the Child Neurology Society, Austin, Texas, October 30, 2013.

### Acknowledgments

The authors wish to thank Melanie Fridl Ross, MSJ, ELS, for editing this paper.

### Author Contributions

SD wrote most of the manuscript and created the figures and tables. MW provided expertise in MRI analysis, including the creation of the MRI-based disease severity score. ST provided expertise and summary of the developmental outcomes of each patient and possible relationships to other clinical factors. PP provided clinical expertise related to epilepsy and EEG interpretation and revised the manuscript. ALG provided clinical expertise in MELAS and its underlying genetics and treatment, in addition to revising the manuscript.

### Declaration of Conflicting Interests

The authors declared no potential conflicts of interest with respect to the research, authorship, and/or publication of this article.

### Funding

The authors received no financial support for the research, authorship, and/or publication of this article.

### Ethical Approval

All patients provided written consent to participate in research studies through the North American Mitochondrial Disease Consortium. (Pro00002935)

### References

1. Kaufman KR, Zuber N, Rueda-Lara MA, Tobia A. MELAS with recurrent complex partial seizures, nonconvulsive status epilepticus, psychosis, and behavioral disturbances: case analysis with literature review. *Epilepsy Behav.* 2010;18:494-497.
2. Koga Y, Povalko N, Nishioka J, et al. Molecular pathology of MELAS and L-arginine effects. *Biochim Biophys Acta.* 2012;1820:608-614.
3. Uusimaa J, Moilanen JS, Vainionpaa L, et al. Prevalence, segregation, and phenotype of the mitochondrial DNA 3243A>G mutation in children. *Ann Neurol.* 2007;62:278-287.
4. Pavlakis SG, Phillips PC, DiMauro S, et al. Mitochondrial myopathy, encephalopathy, lactic acidosis, and strokelike episodes: a distinctive clinical syndrome. *Ann Neurol.* 1984;16:481-488.
5. Corda D, Rosati G, Deiana GA, Sechi G. "Erratic" complex partial status epilepticus as a presenting feature of MELAS. *Epilepsy Behav.* 2006;8:655-658.
6. Karkare S, Merchant S, Solomon G, et al. MELAS with A3243G mutation presenting with occipital status epilepticus. *J Child Neurol.* 2009;24:1564-1567.
7. Lin CM, Thajeb P. Valproic acid aggravates epilepsy due to MELAS in a patient with an A3243G mutation of mitochondrial DNA. *Metab Brain Dis.* 2007;22:105-109.
8. Oguro H, Iijima K, Takahashi K, et al. Successful treatment with succinate in a patient with MELAS. *Intern Med.* 2004;43:427-431.
9. Canafoglia L, Franceschetti S, Antozzi C, et al. Epileptic phenotypes associated with mitochondrial disorders. *Neurology.* 2001;56:1340-1346.
10. Funakawa I, Yasuda T, Terao A. Periodic lateralized epileptiform discharges in mitochondrial encephalomyopathy. *Electroencephalogr Clin Neurophysiol.* 1997;103:370-375.
11. Kanaumi T, Hirose S, Goto Y, et al. An infant with a mitochondrial A3243G mutation demonstrating the MELAS phenotype. *Pediatr Neurol.* 2006;34:235-238.
12. Leff AP, McNabb AW, Hanna MG, et al. Complex partial status epilepticus in late-onset MELAS. *Epilepsia.* 1998;39:438-441.
13. Ribacoba R, Salas-Puig J, Gonzalez C, Astudillo A. Characteristics of status epilepticus in MELAS. Analysis of four cases. *Neurologia.* 2006;21:1-11.
14. Kim IO, Kim JH, Kim WS, et al. Mitochondrial myopathy-encephalopathy-lactic acidosis-and strokelike episodes (MELAS) syndrome: CT and MR findings in seven children. *AJR Am J Roentgenol.* 1996;166:641-645.
15. Toribe Y, Tominaga K, Ogawa K, Suzuki Y. Usefulness of L-arginine infusion for status epilepticus in mitochondrial myopathy, encephalopathy, lactic acidosis, and stroke-like episodes. *No To Hattatsu.* 2007;39:38-43.
16. Lee YM, Kang HC, Lee JS, et al. Mitochondrial respiratory chain defects: underlying etiology in various epileptic conditions. *Epilepsia.* 2008;49:685-690.
17. Yuen AW, Sander JW. Impaired mitochondrial energy production: the basis of pharmacoresistance in epilepsy. *Med Hypotheses.* 2011;77:536-540.
18. Tzoulis C, Bindoff LA. Acute mitochondrial encephalopathy reflects neuronal energy failure irrespective of which genome the genetic defect affects. *Brain.* 2012;135(pt 12):3627-3634.
19. Kang HC, Lee YM, Kim HD. Mitochondrial disease and epilepsy. *Brain Dev.* 2013;35:757-761.
20. Koga Y, Ishibashi M, Ueki I, et al. Effects of L-arginine on the acute phase of strokes in three patients with MELAS. *Neurology.* 2002;58:827-828.

21. Koga Y, Akita Y, Nishioka J, et al. L-arginine improves the symptoms of strokelike episodes in MELAS. *Neurology*. 2005;64:710-712.
22. Bolszak M, Anttonen AK, Komukainen T, et al. Digenic mutations in severe myoclonic epilepsy of infancy. *Epilepsy Res*. 2009;85:300-304.
23. Craig AK, de Menezes MS, Saneto RP. Dravet syndrome: patients with co-morbid SCN1A gene mutations and mitochondrial electron transport chain defects. *Seizure*. 2012;21:17-20.
24. Anglin RE, Tarnopolsky MA, Mazurek MF, Rosebush PI. The psychiatric presentation of mitochondrial disorders in adults. *J Neuropsychiatry Clin Neurosci*. 2012;24:394-409.