



## Research report

# Pure associative tactile agnosia for the left hand: Clinical and anatomo-functional correlations



Laura Veronelli <sup>a,\*</sup>, Valeria Ginex <sup>a</sup>, Daria Dinacci <sup>b</sup>, Stefano F. Cappa <sup>c,d</sup>  
and Massimo Corbo <sup>a</sup>

<sup>a</sup> Department of Neurorehabilitation Sciences, Casa Cura Policlinico, Milano, Italy

<sup>b</sup> Hildebrand Clinic, Rehabilitation Center, Brissago, Switzerland

<sup>c</sup> Istituto Universitario Studi Superiori, Pavia, Italy

<sup>d</sup> San Raffaele Scientific Institute, Milano, Italy

## ARTICLE INFO

## Article history:

Received 5 February 2014

Reviewed 12 April 2014

Revised 13 May 2014

Accepted 18 June 2014

Action editor Georg Goldenberg

Published online 1 July 2014

## Keywords:

Tactile agnosia

Apraxia

Tactile object recognition

Somatosensory perception

Cross-modal transfer

Parietal lobe

## ABSTRACT

Associative tactile agnosia (TA) is defined as the inability to associate information about object sensory properties derived through tactile modality with previously acquired knowledge about object identity. The impairment is often described after a lesion involving the parietal cortex (Caselli, 1997; Platz, 1996). We report the case of SA, a right-handed 61-year-old man affected by first ever right hemispheric hemorrhagic stroke. The neurological examination was normal, excluding major somesthetic and motor impairment; a brain magnetic resonance imaging (MRI) confirmed the presence of a right subacute hemorrhagic lesion limited to the post-central and supra-marginal gyri. A comprehensive neuropsychological evaluation detected a selective inability to name objects when handled with the left hand in the absence of other cognitive deficits. A series of experiments were conducted in order to assess each stage of tactile recognition processing using the same stimulus sets: materials, 3D geometrical shapes, real objects and letters. SA and seven matched controls underwent the same experimental tasks during four sessions in consecutive days. Tactile discrimination, recognition, pantomime, drawing after haptic exploration out of vision and tactile–visual matching abilities were assessed. In addition, we looked for the presence of a supra-modal impairment of spatial perception and of specific difficulties in programming exploratory movements during recognition.

Tactile discrimination was intact for all the stimuli tested. In contrast, SA was able neither to recognize nor to pantomime real objects manipulated with the left hand out of vision, while he identified them with the right hand without hesitations. Tactile–visual matching was intact. Furthermore, SA was able to grossly reproduce the global shape in drawings but failed to extract details of objects after left-hand manipulation, and he could not identify objects after looking at his own drawings.

This case confirms the existence of selective associative TA as a left hand-specific deficit in recognizing objects. This deficit is not related to spatial perception or to the

\* Corresponding author. Department of Neurorehabilitation Sciences, Casa Cura Policlinico, via Dezza 48, 20144 Milano, Italy.

E-mail address: [laura.veronelli@gmail.com](mailto:laura.veronelli@gmail.com) (L. Veronelli).

<http://dx.doi.org/10.1016/j.cortex.2014.06.015>

0010-9452/© 2014 Elsevier Ltd. All rights reserved.

programming of exploratory movements. The cross-modal transfer of information via visual perception permits the activation of a partially degraded image, which alone does not allow the proper recognition of the initial tactile stimulus.

© 2014 Elsevier Ltd. All rights reserved.

## 1. Introduction

Tactile agnosia (TA) is defined as the inability to recognize objects after tactile exploration, in the presence of relatively intact sensory functions and adequate cognitive abilities. The deficit is modality-specific, as the same object is promptly recognized through other modalities (Saetti, De Renzi, & Comper, 1999). The process of recognition of an object requires various abilities, such as encoding elementary sensory data, integrating the sensory information in order to generate a coherent tactile representation of the object, and associating the tactile representation with semantic knowledge about the object. According to Lissauer (1890), TA may result from impairments at the stage of sensory integration (apperceptive TA) or at a subsequent stage in which tactile representation acquires meaning (associative TA).

The neural correlates of tactile object recognition involve the inferior parietal cortex and the insular cortex (Bohlhalter, Fretz, & Weder, 2002; Caselli, 1997; Crutch, Warren, Harding, & Warrington, 2005; Platz, 1996; Reed, Caselli, & Farah, 1996). Crutch et al. (2005) described a patient with bilateral apperceptive TA due to a left hemisphere lesion extending from the parietal operculum to the superior parietal lobe, which involves the posterior part of the post-central gyrus, the supra-marginal gyrus and the anterior part of the angular gyrus in the inferior parietal lobe. The two patients affected by apperceptive TA described by Bohlhalter et al. (2002) showed a lesion in left post-central gyrus and left retro-insular/parietal operculum, and in the posterior parietal lobe. With respect to associative TA, Caselli (1991) described seven patients with brain lesions mainly damaging the left or the right inferior parietal, the posterior temporal, and the posterior insular cortex. Platz (1996) reported a patient with left-hand associative TA, HK, who showed a lesion limited to the right post-central gyrus and supra-marginal gyrus. More recently, a focal lesion involving selectively the trunk and the splenium of the corpus callosum was associated with left-hand associative TA (Balsamo, Trojano, Giamundo, & Grossi, 2008).

Since the first observations of TA, various interpretations and explanation attempts of the deficit have been advanced. The absence of primary somatosensory impairment is a crucial point, which however is hard to disentangle because, as clearly explained by Saetti et al. (1999), ‘the concomitant presence of TA and somesthetic deficits is frequent, due to the fact that the parietal lesion that causes agnosia often extends to the somatosensory cortex and/or its afferent pathways’. Studies that investigated tactile object recognition abilities of brain-damaged patients reported only relatively, rather than completely, intact elementary processing (e.g., touch, pain, temperature, vibration, thermal properties). For this reason,

some authors concluded for the impossibility to support the concept of agnosia (Bay, 1944; Campora, 1925). However, Wiebers, Dale, Kokmen, and Swanson (1998) pointed out a disproportion between the severity of the sensory deficit (often mild) and the recognition deficit, suggesting that in these cases sensory difficulties cannot account for defective recognition. Moreover, some cases of ‘pure’ TA have been described (Caselli, 1991; Endo, Miyasaka, Makishita, Yanagisawa, & Sugishita, 1992; Wernicke, 1895). Platz (1996) proposed an alternative concept for TA, which is compatible with the presence of sensory deficits, suggesting that the tactile recognition of an object involves distributed perceptual-motor processes rather than a separate stage following perception.

The determinants of defective tactile object recognition represent an open issue. Some authors highlighted that the exploratory motor procedures of the handling process are directly linked to the extraction of specific properties of objects. In particular, Caselli (1991) suggested that tactile object recognition involves a dynamic reciprocal interaction between exploratory hand and finger movements and the sensory data acquired as a result of those movements. Valenza et al. (2001) described a patient with a praxic disorder, showing dissociation between impaired shape and object recognition when using spontaneous exploratory procedures (active touch) and intact shape recognition when the experimenter guided the exploration (passive modality). In this case, the deficit was attributed to a selective difficulty in the exploration and manipulation of objects (pure tactile apraxia). Crutch et al. (2005), describing a patient with both apraxia and apperceptive TA, demonstrated that the computation of shape properties depends on intact programming of exploratory hand movements. An alternative possibility, however, is that the deficit in tactile object recognition does not allow the subject to manipulate efficiently the stimulus, because of the inability to distinguish *a priori* the salient features. In line with this view, Platz (1996) suggested that the mild deficit in exploration exhibited by patient HK might be the consequence, rather than the cause of the recognition deficit.

Another hypothesis is that TA could be secondary to a general supra-modal disorder of spatial perception (De Renzi, 1982; Ettlinger, Warrington, & Zangwill, 1957; Semmes, 1965). Different tasks, such as point localization, sense of passive movement and map-following, have been used to test the spatial abilities in patients with difficulty in tactile object recognition. Semmes, Weinstein, Ghent, and Teuber (1963) used a locomotor spatial test, in which patients were required to walk through a set of nine discs placed on the floor, guided by a visually presented map. They showed that the patient recognition performance correlated with the spatial recognition abilities, concluding that TA was

secondary to a more general spatial deficit. Nevertheless, [Reed et al. \(1996\)](#), using two map-following tasks (one of those was the same used by Semmes and colleagues), described a patient with TA and without spatial impairment.

Patients with TA often show preserved cross-modal associations, as tested through tactile–visual matching tasks. [Bohlhalter et al. \(2002\)](#) reported two cases of unilateral apperceptive TA, in which the ability in object recognition was improved after cross-modal information transfer. The authors suggested that the visual information (based on an intact visual representation of the object) can evoke a coordinated neural activity that facilitates the recognition due to a cross-modal comparison between the information in visual memory (intact) and the defective information derived from tactile exploration.

The main goals of the present case report are: (i) to establish the existence and selectivity of TA as a modality-specific recognition deficit, neither due to a praxic disturbance, nor to a supra-modal disorder of spatial perception; (ii) to evaluate the contribution of cross-modal information transfer in the process of tactile object recognition.

## 2. Case report

Patient SA, a right-handed 61-year-old man with graduate education, was admitted in our clinic to attend a neuro-rehabilitation program, 10 days after a lobar hemorrhagic stroke. While sleeping, he was awoken by involuntary movements of left limbs, shortly resolved; admitted to the hospital, a brain TC revealed an atypical parietal lobe haemorrhage; brain MRI (magnetic resonance imaging) with gadolinium, performed 4 days later, confirmed the presence of an intraparenchymal hemorrhagic lesion in parietal lobe, with modest perilesional brain oedema without enhancement. The EEG showed dysfunctional signs in both hemispheres; an antiepileptic therapy was started (Carbamazepine, 600 mg daily), and afterwards the patient remained seizure free. The neurological examination performed at hospital in the acute phase showed a left sensory-motor deficit, with progressive improvement. The neurological examination performed at the admission in our department, 15 days post-onset, revealed only a slight left arm loss of strength. Left limbs tendon reflexes were brisk. Clinical tests of co-ordination for upper and lower limbs were correctly performed. Routine neurological assessment of the somato-sensory system revealed normal sensation of light touch, pinprick, temperature, position sense and vibration throughout the body. He did not show tactile extinction. The brain MRI, performed 20 days after the stroke, confirmed the presence of a single, well-demarcated cortico-subcortical hyperintense lesion involving the antero-superior part of the parietal lobe (post-central circumvolution). The neurological examination was performed at follow-up every 2 weeks and showed a progressive improvement of left arm strength to a normal level; no changes were detected in sensory or co-ordination tests.

### 2.1. Neuropsychological assessment

The general neuropsychological examination established that SA had no significant cognitive impairment. Language

evaluation showed normal performances in confrontation naming of objects and verbs (Batteria per l'Analisi dei Defici Afasici, B.A.D.A., [Miceli, Laudanna, Burani, & Capasso, 1994](#)), confirming spared lexical access through the visual modality. Verbal and visuo-spatial short- and long-term memory was assessed by immediate and 15 min delayed recall of a list of words ([Carlesimo, Caltagirone, Fadda, Marfia, & Gainotti, 1995](#)), the 10 min delayed recall of the Rey–Osterrieth Complex Figure ([Caffarra, Vezzadini, Dieci, Zonato, & Venneri, 2002; Osterrieth, 1944](#)), the Disyllabic Words Span ([Spinnler & Tognoni, 1987](#)) and Corsi's Block tapping test ([Spinnler & Tognoni, 1987](#)): the patient obtained scores within normal range. Reasoning abilities were assessed through the Standard Progressive Matrices test ([Spinnler & Tognoni, 1987](#)) and resulted within normal range. Attention and Executive functions were evaluated with Wisconsin Card Sorting Test ([Laiacina, Inzaghi, De Tanti, & Capitani, 2000](#)), Trial Making Test ([Giovagnoli et al., 1996](#)), and phonemic and semantic verbal fluency ([Mondini, Mapelli, Vestri, & Bisiacchi, 2003; Spinnler & Tognoni, 1987](#)). Performance in all these tests was within the normal range. The assessment of visuo-spatial functions revealed no difficulties in the copy of the Rey–Osterrieth Complex Figure ([Caffarra et al., 2002; Osterrieth, 1944](#)) and no evidence of spatial neglect emerged in the cancellation tasks ([Albert, 1973; Gauthier, Dehaut, & Joannette, 1989](#)) nor in the sentence reading test ([Zoccolotti et al., 1989](#)). Praxis functions assessed with the ideomotor and ideative apraxia test ([De Renzi & Lucchelli, 1988; De Renzi, Motti, & Nichelli, 1980](#)) resulted within normal range. All scores are reported in [Table 1](#). For all tests, adjusted and 'equivalent' scores ([Capitani & Laiacina, 1997](#)) were available. The equivalent scores, that provide scores comparable across different tasks, range from '0' (defective performance) to '4' (very good performance, see psychometric details in [Capitani & Laiacina, 1997](#)).

In order to verify if fine motor control was preserved, especially with respect to the left hand, the patient was asked to write out of visual control with each hand consecutively. While right-hand writing was fluent, the left one was clumsy. SA had strong right-hand laterality (scoring 80 at the Edinburgh Handedness Inventory, range: –100 extreme left-hand preference; +100 extreme right-hand preference) ([Oldfield, 1971](#)), which could account for his difficulties in writing with the contralesional hand. Upon clinical testing, SA showed a difficulty in recognizing and naming objects (e.g., a key, a pen) after tactile presentation (out of vision) with the contralesional left hand. This isolated deficit was investigated in the next sessions.

### 2.2. Lesion mapping

Scanning was performed by 1.5 Tesla MRI system at the same time of the psychometric evaluation and of the behavioural assessment of the recognition deficit. Lesion site was drawn manually using the MRicro software ([Rorden & Brett, 2000](#)) onto selected horizontal slices of a standard template brain ([Fig. 1](#)). Lesion maps selectively involved the right post-central gyrus and, minimally, the underlying white matter (20.0 cc). Broadmann Area (BA) analysis showed a major involvement of the primary somatosensory cortex of the right hemisphere

**Table 1 – Neuropsychological data. Raw scores and equivalent scores or cut-off scores are reported. Equivalent scores range from '0' (defective performance), '1' (borderline performance), and '2' to '4' (performance within normal range).**

Cognitive domain	Test	Raw score	Equivalent score
Verbal long-term memory – immediate recall	List of 15 words	46/75	4
Verbal long-term memory – delayed recall	List of 15 words	6/15	1
Visuo-spatial long-term memory	Rey–Osterrieth Complex Figure – recall	18/36	4
Verbal short-term memory	Disyllabic Words Span	4	2
Visuo-spatial short-term memory	Corsi's Block tapping test	4	1
Problem solving	Wisconsin Card Sorting Test – global score	28	4
	Wisconsin Card Sorting Test – perseverative responses	5	4
	Wisconsin Card Sorting Test – non-perseverative errors	14	3
	Wisconsin Card Sorting Test – failure to maintain set	0	4
Abstract reasoning	Raven Coloured Matrices	40/48	4
Shifting attention	Trial Making Test A	42	4
	Trial Making Test B-A	64	3
Lexical access	Semantic verbal fluency	21.75	4
Visuo-spatial abilities	Rey–Osterrieth Complex Figure – copy	33/36	4
Cognitive domain	Test	Raw score	Cut-off
Lexical access	Phonemic verbal fluency	11.6	10
Confrontation naming – object	B.A.D.A.	30/30	28
Confrontation naming – verbs	B.A.D.A.	28/28	26
Ideomotor apraxia	Imitation of gestures – upper right limb	67/72	53
	Imitation of gestures – upper left limb	66/72	53
Ideative apraxia	Production of semantic gestures	5/5	nr
nr: normal range.			

(BA 3: 8292 voxels; BA 2: 1420 voxels; BA 1: 184 voxels), followed by the primary motor cortex (BA 4: 3135 voxels), and by the supra-marginal gyrus (BA 40: 902 voxels).

### 3. Assessment of tactile perception

#### 3.1. Materials and methods

A series of experimental tasks were conducted in order to investigate the nature of SA's tactile recognition deficits. The tasks were designed to assess discrimination and identification abilities of elementary tactile features, shapes and real objects perceived through haptic modality. Each task was administered in different sessions, and performances were videotaped. Seven age- and education-matched control subjects underwent to the same evaluation. Mean age and education of the control group were, respectively, 59.1 years (standard deviation – SD  $\pm$  2.8; range 54–61) and 15.4 years (SD  $\pm$  2.2; range 13–18). All controls were males. Informed consent was obtained from the patient and controls, according with the Declaration of Helsinki (British Medical Journal, 302: 1194, 1991). During all the tasks, SA and controls were required to close the eyes and vision was additionally prevented using an A3 sheet of paper, except when explicitly stated.

##### 3.1.1. Tactile discrimination

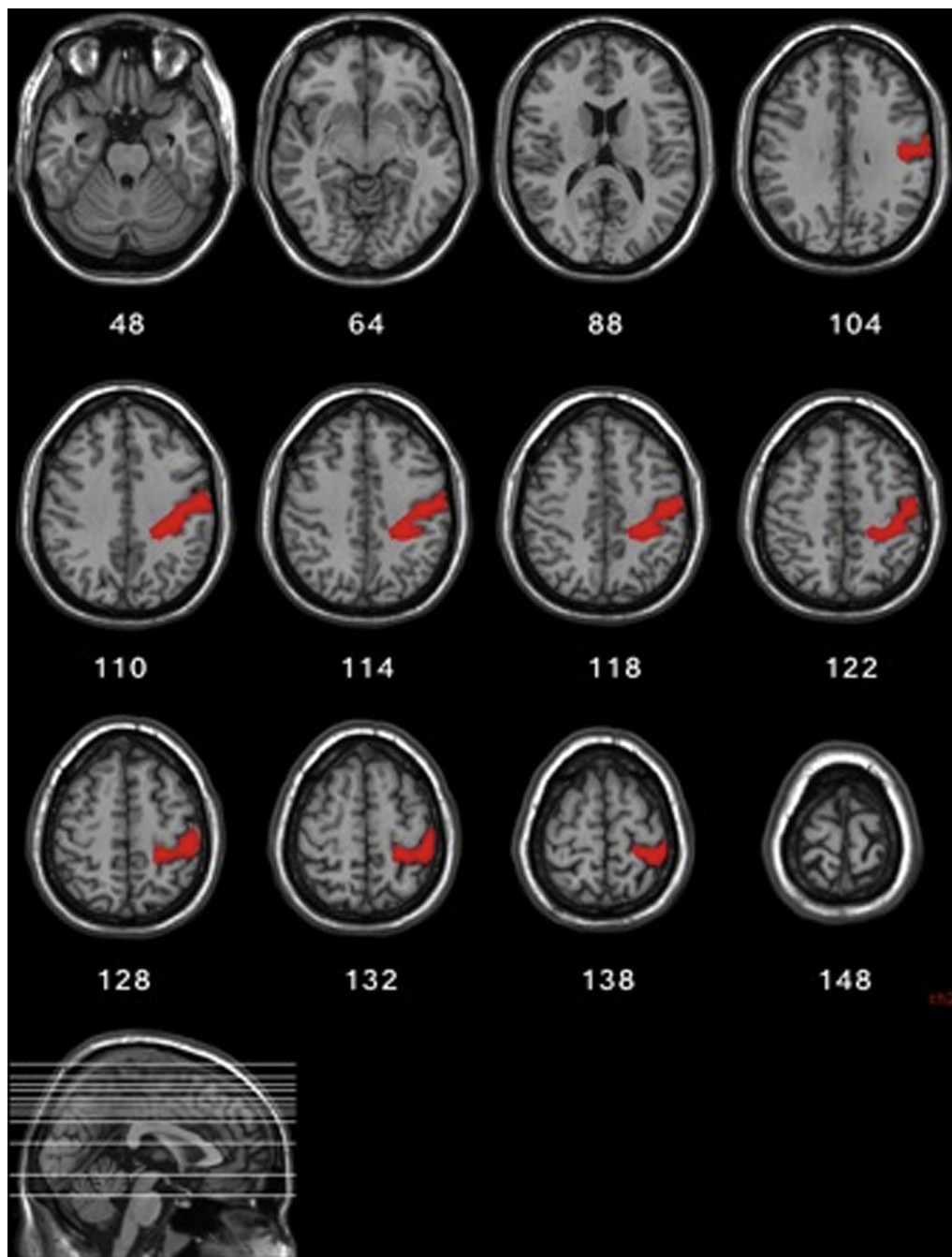
The patient was asked to touch and handle pairs of stimuli and give a same–different judgement. In order to avoid any priming effect of the unimpaired hand on the other one, the two stimuli of each pair were first consecutively presented

to the left hand, then to both hands simultaneously and, finally, only to the right hand. No time limits were given. Bimanual handling was assessed to test possible inter-hemispheric information transfer and facilitation. Moreover, in the last condition, the similarity judgement was carried out without any working memory involvement. The order of stimulus presentation for each task was randomised.

Three types of stimuli sets were used:

- i. *Materials*. 14 pairs of different materials (e.g., plastic, wool, paper, glass) were included. Stimuli samples were 40 mm squares, placed on a horizontal surface, which the patient was required to explore with the pad of his forefinger.
- ii. *3D geometrical shapes*. 10 pairs of 3D cardboard geometrical shapes (e.g., pyramid, cone, cube, cylinder) were presented. Mean height was 85.00 mm (SD  $\pm$  15.81; range 60–100), mean length was 67.50 mm (SD  $\pm$  6.35; range 60–80), and mean depth was 67.50 mm (SD  $\pm$  13.18; range 50–100). In the bimanual task the same 10 pairs were used.
- iii. *Real objects*. 30 pairs of familiar objects were presented in a randomized order. 15 pairs were composed by two identical objects, whereas the other 15 by two different objects. The differences between these objects were previously balanced depending on shape and texture. Hence, about half of the 15 pairs ( $N = 8$ ) were objects characterized by similar shape and different texture (e.g., lighter/battery), while the remaining ones ( $N = 7$ ) were characterized by similar texture and different shape (e.g., glass/light bulb). In the bimanual





**Fig. 1 – Lesion mapping of patient SA. MNI coordinates for the shown axial slices are given. Regions specifically damaged involved the right post-central gyrus, the supra-marginal gyrus and the underneath white matter.**

discrimination task a total of 25 pairs of objects was used: 9 pairs of identical objects, 16 pairs of different objects. Regarding the latest stimuli, 10 pairs were characterized by similar shape and different texture whereas the other 6 were characterized by similar texture and different shape.

### 3.1.2. Tactile identification

After assessing discrimination abilities, SA was asked to name after haptic exploration different kinds of stimuli presented in

a randomized order, first to the left hand and second to the right one.

- i. *3D geometrical shapes.* The same 10 3D cardboard geometrical shapes used in the discrimination task were included.
- ii. *Real objects.* 33 objects used in the discrimination task were presented. If the patient could not name the object, a subsequent pantomime was required, in order to assess recognition without language involvement. A difficulty in naming with spared pantomime would suggest a linguistic (rather than gnosis) impairment, i.e., tactile anomia.

### 3.1.3. Tactile–visual matching

SA was asked to handle out of vision and without time limits a real object; then the object was removed and he was asked to open his eyes and to point to the photograph of the handled object presented on a computer screen with three distractors: one shape-matched with the target, one texture-matched and one not matched for any feature with the target. The task was executed first with the left hand and then with the right one. The same 33 real objects used in the tactile identification task were used with a different randomized order.

### 3.1.4. Drawing after haptic exploration of objects

In order to evaluate the ability to elaborate a representation of an object's shape, we asked the patient to manipulate an object with each hand out of vision, to draw it with the dominant hand, and then to name the drawn object. The left hand was tested first to prevent performance bias due to cueing with knowledge obtained by the intact right hand. 5 small size familiar objects were presented, in order to allow a complete exploration with one hand (e.g., birthday candle, a wooden spoon, a nail varnish) (Fig. 2), different from those presented in the object discrimination task.

### 3.1.5. Picture naming

The patient was asked to name the photographs used in tactile–visual matching task, in order to evaluate the ability of visually recognize the pictures used in the task. The possibility of a bias in remembering photographs already seen was avoided by administering first the tactile–visual matching performance.

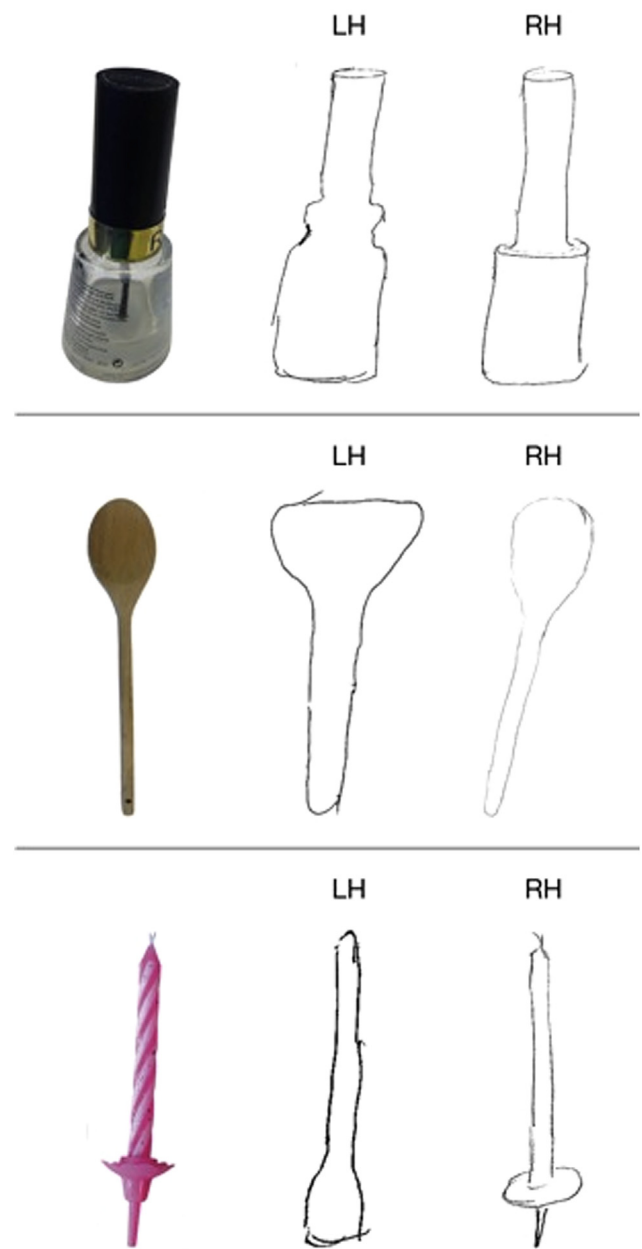
### 3.1.6. Statistical analysis

SA's left-hand performances were compared to controls' left-hand ones, by t-tests using the procedure described by Crawford and Garthwaite (2002). In the single case studies, the matched control sample approach is a very widely employed methodological design, avoiding the inflated Type I (false positive) and Type II (false negative) errors associated with the intra-individual approach without a control sample (Laws, Gale, Leeson, & Crawford, 2005). SA's left- and right-hand performances were also compared using two-tailed Fisher's exact test. Significance level was set at  $p < .05$ . In shape naming, shape discrimination and object discrimination tasks the only comparisons were conducted between SA's left and right hand, due to errorless performances shown by controls.

## 3.2. Results

In the tactile discrimination tasks SA showed spared discrimination ability for textures, shapes and real objects. Conversely, he exhibited a deficit in both naming and pantomiming real objects after left-hand tactile presentation. Fig. 3 illustrated the percentage performances obtained by SA and controls in tactile discrimination and identification tasks.

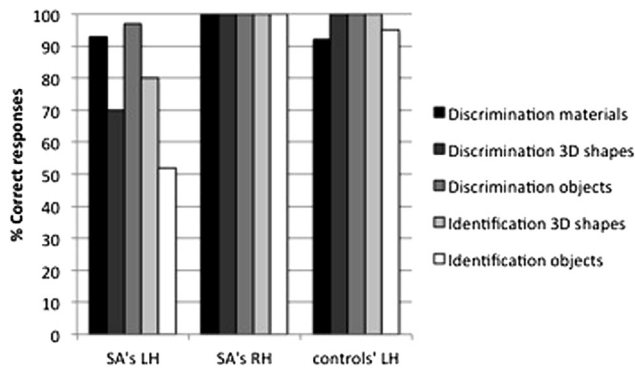
SA was able to discriminate 13 pairs of different material out of 14 (92%) with the left hand, and 14 out of 14 (100%) with the right one, without significant differences between hands (left–right Fisher's exact test,  $p = 1.00$ ). No differences were found in the comparison between SA and controls (material



**Fig. 2 – Examples of SA's drawings of familiar objects after left-hand (LH) and right-hand (RH) manipulation.**

discrimination:  $p = .86$ ). Similar intact abilities were found in the shape discrimination task, in which SA was able to correctly discriminate 7 out of 10 shapes (70%) with the left hand and 10 out of 10 (100%) with the right one (left–right Fisher's exact test,  $p = .21$ ). Finally, SA showed intact discrimination of real objects: 29 out of 30 pairs (96%) with the left hand and 30/30 (100%) with the right one (left–right Fisher's exact test,  $p = 1.00$ ). During bimanual presentation he correctly discriminated 6 out of 10 pairs of shapes (60%), and 23 out of 25 pairs of real objects (92%), exhibiting no differences with respect to left hand alone.

While 3D shape naming was relatively spared [left-hand correct responses 8/10 (80%), right-hand ones 10/10 (100%);



**Fig. 3 – Percentages of SA's left hand (LH) and right hand (RH) and controls' LH correct responses in the tactile discrimination task (materials, 3D shapes, objects) and in the tactile identification task (3D shapes, objects).**

left–right Fisher's exact test,  $p = .47$ ], severe difficulties emerged when the recognition task addressed the naming abilities of real objects handled with the left hand. SA was able to name correctly 17 out of 33 real objects (51%) after left-hand tactile exploration, and 30 out of 30 (100%) after right-hand one (left–right Fisher's exact test,  $p < .001$ ). Left-hand performance was significantly different from controls' one ( $p < .005$ ). Even when objects have been correctly identified this happened after long latencies (see Supplementary video material). Furthermore, SA could not pantomime any objects that he was not able to name. In the case of the relatively large objects included in the tasks, there was the possibility that the subjects' perception was supported by judgements concerning the spatial position of the fingers (kinesthesia) rather than by tactile fingertips information (we wish to thank an anonymous reviewer for this suggestion). Real objects were then divided in large (maximum size over 60 mm: 19/33) and small (maximum size under 60 mm: 14/33) objects, the last being characterized by a small volume (e.g., little candle, screw, match, cork) and requiring more fine-grain texture and shape information provided by the fingertips alone. The percentage of correct identifications did not differ between the two groups of stimuli (large objects: 47%; small objects: 57%;  $p = .73$ ).

Supplementary video related to this article can be found online at <http://dx.doi.org/10.1016/j.cortex.2014.06.015>.

In the tactile–visual matching task, SA was able to visually identify all but one of the tactually explored objects (32/33, 96%), including the ones he did not identify through the tactile modality. The only error was shape-based ('compact disc' for 'fumigator').

In the drawing task, SA was able to grossly reproduce the global shape, but rarely he was able to extract details and to place them accurately. Nevertheless, in both conditions (i.e., after manipulating and looking at his drawing) he failed to name the objects drawn. Conversely, after manipulation with the right hand, the patient was able to quickly recognize all five objects presented and to draw their global shape and details.

Finally, in the picture naming task, all pictures but one (32/33, 96%) were correctly named. The uncorrected item ('cork') was previously recognized during tactile–visual matching task.

### 3.3. Comment

SA was able to discriminate between elementary features perceived through haptic modality. Discrimination performance, evaluated through a series of tasks (materials, 3D geometrical shapes, real objects) was largely spared. This finding should be considered with caution, due to the ceiling performance exhibited by the control sample and by the patient himself with his unimpaired right hand, suggesting that the tasks might be quite simple. The drawings of objects explored out of vision supported the fact that the patient integrated sensory information into a coherent tactile representation of the object. However, he could neither name nor pantomime tactile explored objects, exhibiting a deficit in the association between the tactile representation and the proper semantic knowledge of the object itself. The inability in pantomiming the unrecognized objects excludes the possibility of a tactile–verbal disconnection, as in the case of tactile anomia (Endo et al., 1992). On the basis of the distinction made by Lissauer between 'apperceptive' and 'associative' agnosia, SA's deficits can be described as associative. Nevertheless, as suggested by Platz (1996), perceptual deficits and associative agnosia may not reflect an impairment of completely distinct underlying processes, but overlap and run interactively. This hypothesis is supported by SA's performances in shape discrimination, in which a difference, even if not significant, was found between left (70% of corrected responses) and right hand (100%). Furthermore, in SA's drawings shape is grossly reported without details.

Concerning cross-modal transfer, SA exhibited a preserved ability to match across modalities, as shown in the tactile–visual matching task: while tactile recognition was not possible, he correctly identified the haptically explored object if presented visually among distractors. However, starting from his own drawings, he was not able to visually recognize the manipulated objects. The possible explanations of this finding will be discussed further on.

## 4. Assessment of praxic abilities

### 4.1. Materials and methods

Even if SA did not show ideational and ideomotor apraxia during baseline psychometric assessment, his movements during haptic exploration were qualitatively mildly clumsy. The aim of the following series of experimental tasks was to investigate possible praxic influences on the missed recognitions, according to the procedure used by Valenza et al. (2001). We assessed letter discrimination and recognition through an active modality, in which the patient was free to manipulate letters, and a passive modality, testing SA's graphesthetic function. Graphesthesia is the ability to recognize, by the sensation of touch, alphanumerics that are traced with a tipped stylus on the skin. In this series of experiments we used graphesthesia to test the access to letter representations excluding handling and hand exploratory movements.

The same group of seven age- and education-matched subjects used as controls in the assessment of tactile perception underwent these experimental tasks.

Four experimental tasks were designed and assessed in both hands:

- i. *Active letter discrimination.* The task required a same–different judgement of 10 pairs of plastic upper-case alphabetical letters (max high 35 mm, max length 20 mm, depth 10 mm) after active tactile exploration out of vision.
- ii. *Active letter identification.* SA was asked to name after handling the 21 letters described above.
- iii. *Passive letter discrimination.* The experimenter wrote on patient's palm 10 pairs of upper-case alphabetical letters, using the head of a soft pen and maintaining the same dimension as the plastic letters at points (i) and (ii). A same–different judgement was required.
- iv. *Passive letter identification.* 21 letters were written with same procedure as point (iii). The task required naming each letter.

If SA's recognition deficit was due to praxic deficits, he would not show any difficulties in naming letters when passively traced on the palm of his left hand, while active letter recognition should be affected. On the contrary, if praxic difficulties were consequent to a core gnosis impairment, deficits would be found in both active and passive modalities. If the deficit is truly 'associative' in nature, differences should be found between passive discrimination (spared) and passive identification (affected).

The statistical analyses were performed as described above (see Section 3.1.6).

## 4.2. Results

SA showed difficulties in identification compared to discrimination of letters in both active and passive modalities. Percentage performances exhibited by SA and controls are reported in Fig. 4.

Letter discrimination performances did not differ between hands in both active (left–right Fisher's exact test,  $p = .58$ ) and passive modalities (left–right Fisher's exact test,  $p = 1.00$ ). SA's left-hand active discrimination was significantly different from controls ( $p < .001$ ), while passive discrimination did not ( $p = .22$ ). Correct responses were 7 out of 10 (70%) with both

hands in active modality, while in passive modality SA correctly discriminated 9 out of 10 letter (90%) with the left hand and 10 out of 10 letters (100%) with the right one.

Poorer naming performances were exhibited with the left hand compared to the right one, in both active and passive modalities: left-hand correct responses were 2 out of 21 (9%), and right-hand ones 20 out of 21 in active letter naming (95%) (left–right Fisher's exact test,  $p < .001$ ). In passive modality, left-hand correct responses were 10 out of 21 (48%), and right-hand ones 17 out of 21 (81%) (left–right Fisher's exact test,  $p = .05$ ). Left-hand active and passive naming performances were significantly different from controls ( $p < .005$ , for both comparisons). The difference between active and passive modalities was also significant (Fisher's exact test,  $p < .05$ ): interestingly the same difference was also significant in the control group (Fisher's exact test,  $p < .05$ ), suggesting that the type of task could play a role in the level of accuracy with the left hand.

## 4.3. Comment

In some case reports tactile object recognition deficits were attributed to affected abilities to plan and program the gestures necessary to the correct exploration of the object during handling (i.e., 'tactile apraxia', Valenza et al., 2001). On the contrary, other studies (see Platz, 1996) suggested that the recognition deficit itself could result in a poor organization of exploratory gestures. Without a mental representation of the object, based on its recognition, it would be difficult to plan and monitor adequate movements during manipulation. SA exhibited defective letter identification in both active and passive (graphesthesia) modalities only for the left hand, while letter discrimination was largely spared. Correct performances in passive letter discrimination confirmed intact sensory processing, and provided further evidence that sensory impairment cannot explain our patient's difficulties. One possibility was that fingertips and palm could have been differently affected by a sensory deficit. In the passive modality, however, (palm) fine discrimination abilities were preserved, while identification was impaired. Similar patterns of performances were found also in the active modality (fingertips) supporting a high level (associative) nature of the deficit. On the other hand, motor programming abilities were sufficiently preserved to allow correct discrimination between very similar stimuli after active exploration. Defective recognition seems to be the core of our patient deficit, and the mild deficit in exploration could be a consequence, rather than a cause of the object recognition disturbance (Platz, 1996). Finally, a difference between discrimination and identification confirmed even in passive modality the 'associative' (rather than 'apperceptive') nature of the deficit.

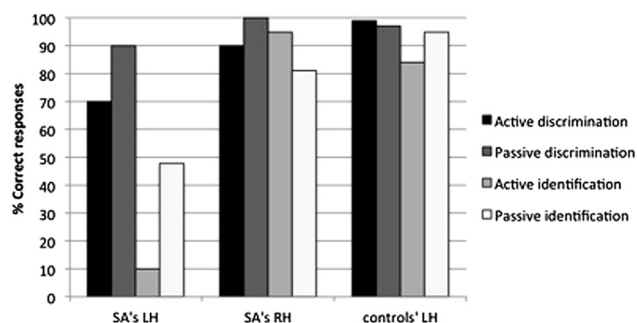


Fig. 4 – Percentages of SA's left hand (LH) and right hand (RH) and controls' LH correct responses in active (free exploration) and passive (graphesthesia) modalities in discrimination and identification tasks.

## 5. Assessment of supra-modal spatial perception

### 5.1. Tactile spatial exploration

Considering that when tactile object recognition is impaired without concomitant sensory deficits spatial ability is also



often impaired, some authors suggested that TA could be secondary to a general impairment of spatial cognition (De Renzi, 1982; Semmes, 1965). The following experiments were designed to assess SA's abilities in the exploration of peripersonal space.

#### 5.1.1. Materials and methods

A 500 mm × 500 mm base on which 24 cylinders (45 mm of diameter) were positioned (10 on the left, 10 on the right and 4 in the centre), was placed in front of the patient. The patient was asked to explore alternatively with the left and the right hand the space in front of him and to grasp all the cylinders. The task was carried out 3 times with the right hand and 3 times with the left hand; each time the position of the cylinders was randomly varied.

#### 5.1.2. Results

In all the sessions, and with both the right and the left hand, the patient was able to grasp all the cylinders without any omission. SA was able to reach, out of vision, all the cylinders situated in front of him and to remove them correctly and without hesitation. The patient showed a comparable ability in object manipulation with his right and left hand: no differences were found between the two hands in terms of spatial exploration, capacity of stimuli localization, and grasp orientation.

### 5.2. Tactile spatial representation

Representation of space is the result of the integration of multiple spatial representations encoded simultaneously in different coordinate systems that have a partly different, although interconnected, neurological substrate (Reed et al., 1996; Rumiati & Tessari, 2002). The present experiment was designed to investigate if SA's TA may be secondary to a deficit in spatial representation when derived through tactile modality, by assessing SA's ability to represent the peripersonal space.

#### 5.2.1. Materials and methods

A 300 mm × 300 mm base on which 40 cylinders with a diameter of 10 mm were placed was put in front of the patient. The cylinders were positioned on the base in 4 regular rows, each one constituted of 10 cylinders, with the same distance between each cylinder. The task required to move the hand from one cylinder to another, according to the directions given by the examiner. An example of delivery was: "Move your hand to the right for 2 cylinders; then, move forward for 3 cylinders; finally, move to the left for 3 cylinders". The patient was blindfolded, firstly, to avoid any visual facilitation and, secondly, to permit a better comparison with the tactile recognition task, with respect to other studies in which general spatial abilities were assessed with open eyes (Semmes, 1965). The task comprised two conditions: in the first one, the patient was asked to follow directions by imagining to stand in front of the cylinders (fixed condition), whereas in the second one, he had to imagine to mentally follow each direction with his body, updating his coordinate system in line with the direction required (updated condition). Each condition was performed with the right and then with the left hand.

For each condition, 3 directions for the right hand and 3 for the left hand, for a total of 12 directions were presented (3: fixed, right hand; 3: fixed, left hand; 3: updated, right hand; 3: updated, left hand). Directions varied on the number of moves required: 3, 6, and 9 moves respectively for each condition.

#### 5.2.2. Results

The patient performed correctly and without any difficulties with both the right and the left hand. There were no differences between the two conditions.

### 5.3. Comment

SA showed no difficulties in tactile exploration and in spatial representation using tactile modality. SA's impairment in object recognition could not be attributable to a general supra-modal spatial impairment, as proposed by Semmes (1965). The fact that TA was confined to the left hand is also difficult to reconcile with a generalized spatial impairment.

## 6. General discussion

We described a patient showing a selective impairment in tactile object recognition for the left hand only, after a first ever right hemorrhagic stroke. An extensive neuropsychological assessment demonstrated that all other cognitive abilities were totally normal. Furthermore, motor functions were intact, except for slight left arm weakness. The neurological examination excluded the presence of a somatosensory deficit that could account for the tactile impairment. Lesion mapping analysis revealed a well-defined lesion, which involved the right post-central gyrus, the supra-marginal gyrus and, in minimal part, the underlying white matter.

SA showed intact texture and shape discrimination abilities in simple discrimination tests, demonstrating that sensory information was correctly integrated into a coherent tactile representation of an object. Nevertheless, he was not able either to name, describe or pantomime most of objects explored with his left hand out of vision, while the same tasks were correctly executed without any hesitations with the dominant hand. The stage in which a tactile representation is associated with previously acquired knowledge about the object identity was mainly impaired, as described in the case of associative agnosia (Wernicke, 1895). The inability in pantomiming the unrecognized objects excludes the possibility of a tactile–verbal disconnection, as in the case of tactile anomia described by Endo et al. (1992).

Among the few cases of TA reported in the literature, some authors have highlighted the importance of the integrity of praxic abilities (Crutch et al., 2005; Valenza et al., 2001), while others focused on the involvement of supra-modal spatial impairment in tactile recognition deficit (Reed et al., 1996; Saetti et al., 1999). We therefore experimentally tested both of these hypotheses. Concerning praxic abilities, SA showed recognition deficit extended to passive modality as well as the active one, which cannot be explained by his slight exploratory difficulties during manipulation. With respect to the spatial impairment hypothesis, SA did not show any difficulties in the spatial tasks proposed out of vision, suggesting

that the impairment is specific to tactile perception. It is noteworthy that the present case supports the existence of tactile associative agnosia for the left hand as a pure recognition deficit, in absence of significant perceptual defects, an issue which is controversial in the literature (Bay, 1944; Campora, 1925; Wiebers et al., 1998). Furthermore, to our knowledge this is the first case of TA in which both praxic impairment and a general spatial deficit have been experimentally assessed and ruled out. The anatomo-clinical features of the case described here are very similar to the one reported by Platz (1996), HK, in which however the presence of apraxia was excluded only through a clinical evaluation and no assessment of the general spatial impairment was carried out. HK suffered from left-hand associative TA, due to a lesion limited to the right post-central gyrus and supra-marginal gyrus. Similarly, in the case of pure tactile apraxia described by Valenza et al. (2001) the large right-hemisphere lesion that affected the lateral temporal lobe, the frontal operculum and the infero-posterior part of the parietal lobe, preserving the superior right post-central gyrus, could be responsible for the observed praxic abnormalities.

The second goal of the study was to evaluate the contribution of cross-modal information transfer in tactile recognition. In the visual-matching task when four options are given, SA was able to visually recognize an object he could not tactilely identify. This process happened immediately, without any interference effect of visual shape-matched and texture-matched distractors. At first glance, this evidence suggests that information processed during haptic exploration could be effectively transferred across modalities. Several functional magnetic resonance imaging (fMRI) studies (see Amedi, von Kriegstein, van Atteveldt, Beauchamp, & Naumer, 2005; Lacey, Tal, Amedi, & Sathian, 2009, for a review) showed that areas spared in SA, as the lateral occipito-temporal sulcus, the intraparietal sulcus and the insula, play a crucial role in binding visual and tactile information. In particular, the lateral occipito-temporal sulcus and the intraparietal sulcus are visuo-haptic convergence areas, robustly activated during both visual and tactile object recognition. On the other hand the insula, being highly connected to various sensory areas, was proposed to permit the transfer of information between unisensory areas, playing a role in cross-modal matching. However, when drawing after handling, SA was able to grossly reproduce the shape of the manipulated object, but he could not recognize it after looking at his own drawing. This means that the information extracted from tactile manipulation is only partial. Recognition was successful only when a meaningful and detailed image was externally shown. Conversely, when the patient itself directly reproduced the image as in drawing, the representation is partially degraded in shape and free from meaningful details, thus insufficient to activate the semantic memory system even through visual modality. Our patient showed a performance similar to patient MT (Nakamura, Endo, Sumida, & Hasegawa, 1998), who was able to perform drawings and to verbally describe material and form of handled objects, without recognizing them.

In conclusion, this case demonstrates the existence of pure left-hand TA associated with a lesion limited to the post-central and supra-marginal gyri. The cross-modal transfer of information via visual perception allowed the activation of a

partially degraded image, which alone, however, did not allow the proper elaboration and characterization of the initial tactile sense stimulus.

## REFERENCES

- Albert, M. L. (1973). A simple test of visual neglect. *Neurology*, 23, 658–664.
- Amedi, A., von Kriegstein, K., van Atteveldt, N. M., Beauchamp, M. S., & Naumer, M. J. (2005). Functional imaging of human crossmodal identification and object recognition. *Experimental Brain Research*, 166, 559–571.
- Balsamo, M., Trojano, L., Giamundo, A., & Grossi, D. (2008). Left hand tactile agnosia after posterior callosal lesion. *Cortex*, 44(8), 1030–1036.
- Bay, E. (1944). Zum Problem der taktilen Agnosie. *Der Zeitschrift für Nerven*, 156, 64–96.
- Bohlhalter, S., Fretz, C., & Weder, B. (2002). Hierarchical versus parallel processing in tactile object recognition: a behavioural-neuroanatomical study of aperceptive tactile agnosia. *Brain*, 125, 2537–2548.
- Caffarra, P., Vezzadini, G., Dieci, F., Zonato, F., & Venneri, A. (2002). Rey–Osterrieth complex figure: normative values in an Italian population sample. *Neurological Sciences*, 22(6), 443–447.
- Campora, G. (1925). Astereognosis: its causes and mechanism. *Brain*, 48, 65–71.
- Capitani, E., & Laiacina, M. (1997). Composite neuropsychological batteries and demographic correction: standardization based on equivalent scores, with a review of published data. The Italian Group for the Neuropsychological Study of Ageing. *Journal of Clinical and Experimental Neuropsychology*, 19(6), 795–809.
- Carlesimo, G. A., Caltagirone, C., Fadda, L., Marfia, G., Gainotti, G., & Gruppo per la standardizzazione della batteria per il Deterioramento Mentale. (1995). Batteria per la valutazione del Deterioramento Mentale (parte III): analisi dei profili qualitativi di compromissione cognitiva. *Archivio di Psicologia, Neurologia e Psichiatria*, 4, 489–502.
- Caselli, R. J. (1991). Rediscovering tactile agnosia. *Mayo Clinic Proceedings*, 66(2), 129–142.
- Caselli, R. J. (1997). Tactile agnosia and disorders of tactile perception. In T. E. Feinberg, & M. J. Farah (Eds.), *Behavioural neurology and neuropsychology*. New York: McGraw-Hill.
- Crawford, J. R., & Garthwaite, P. H. (2002). Investigation of the single case in neuropsychology: confidence limits on the abnormality of test scores and test score differences. *Neuropsychologia*, 40(8), 1196–1208.
- Crutch, S. J., Warren, J. D., Harding, L., & Warrington, E. K. (2005). Computation of tactile object properties requires the integrity of praxic skills. *Neuropsychologia*, 43(12), 1792–1800.
- De Renzi, E. (1982). *Disorders of space exploration and cognition*. Chichester: J. Wiley.
- De Renzi, E., & Lucchelli, F. (1988). Ideational apraxia. *Brain*, 111, 1173–1185.
- De Renzi, E., Motti, F., & Nichelli, P. (1980). Imitating gestures. A quantitative approach to ideomotor apraxia. *Archives of Neurology*, 37(1), 6–10.
- Endo, K., Miyasaka, M., Makishita, H., Yanagisawa, N., & Sugishita, M. (1992). Tactile agnosia and tactile aphasia: symptomatological and anatomical differences. *Cortex*, 28(3), 445–469.
- Ettlinger, G., Warrington, E. K., & Zangwill, O. L. (1957). A further study of visual-spatial agnosia. *Brain*, 80, 335–361.
- Gauthier, L., Dehaut, F., & Joanette, Y. (1989). The bell test: a quantitative and qualitative test for visual neglect. *International Journal of Clinical Neuropsychology*, 11, 49–54.

- Giovagnoli, A. R., Del Pesce, M., Mascheroni, S., Simoncelli, M., Laiacona, M., & Capitani, E. (1996). Trail making test: normative values from 287 normal adult controls. *The Italian Journal of Neurological Sciences*, 17(4), 305–309.
- Lacey, S., Tal, N., Amedi, A., & Sathian, K. (2009). A putative model of multisensory object representation. *Brain Topography*, 21, 269–274.
- Laiacona, M., Inzaghi, M. G., De Tanti, A., & Capitani, E. (2000). Wisconsin card sorting test: a new global score, with Italian norms, and its relationship with the Weigl sorting test. *Neurological Sciences*, 21(5), 279–291.
- Laws, K. R., Gale, T. M., Leeson, V. C., & Crawford, J. R. (2005). When is category specific in Alzheimer disease? *Cortex*, 41, 452–463.
- Lissauer, H. (1890). Ein Fall von Seelenblindheit nebst einembeitrage zue Theorie derselben. *Archiv fur Psychiatrie und Nervenkrankheiten*, 21, 222–270. English translation by Jackson, M. (1988). Lissauer on agnosia. *Cognitive Neuropsychology*, 5, 155–192.
- Miceli, G., Laudanna, A., Burani, C., & Capasso, R. (1994). *Batteria per l'analisi dei deficit afasici*. Roma: CEPSAG.
- Mondini, S., Mapelli, D., Vestri, A., & Bisiacchi, P. (2003). *Esame Neuropsicologico Breve (ENB). Una batteria di test per lo screening neuropsicologico*. Milano: Raffaello Cortina Editore.
- Nakamura, J., Endo, K., Sumida, T., & Hasegawa, T. (1998). Bilateral tactile agnosia: a case report. *Cortex*, 34(3), 375–388.
- Oldfield, R. C. (1971). The assessment and analysis of handedness: the Edinburgh inventory. *Neuropsychologia*, 9, 97–113.
- Osterrieth, P. A. (1944). Filetest de copie d'une figure complex: contribution a l'etude de la perception et de la memoire [The test of copying a complex figure: a contribution to the study of perception and memory]. *Archives de Psychologie*, 30, 286–356.
- Platz, T. (1996). Tactile agnosia. Casuistic evidence and theoretical remarks on modality-specific meaning representations and sensorimotor integration. *Brain*, 119, 1565–1574.
- Reed, C. L., Caselli, R. J., & Farah, M. J. (1996). Tactile agnosia. Underlying impairment and implications for normal tactile object recognition. *Brain*, 119, 875–888.
- Rorden, C., & Brett, M. (2000). Stereotaxic display of brain lesions. *Behavioural Neurology*, 12(4), 191–200.
- Rumiati, R. I., & Tessari, A. (2002). Imitation of novel and well-known actions: the role of short-term memory. *Experimental Brain Research*, 143(3), 395.
- Saetti, M. C., De Renzi, E., & Comper, M. (1999). Tactile morphagnosia secondary to spatial deficits. *Neuropsychologia*, 37, 1087–1100.
- Semmes, J. (1965). A non-tactual factor in astereognosis. *Neuropsychologia*, 3, 295–314.
- Semmes, J., Weinstein, S., Ghent, L., & Teuber, H.-L. (1963). Correlates of impaired orientation in personal and extrapersonal space. *Brain*, 86, 747–772.
- Spinnler, H., & Tognoni, G. (1987). Standardizzazione e taratura di test neuropsicologici. *The Italian Journal of Neurological Sciences*, 8 (Suppl. 6), 1–20.
- Valenza, N., Ptak, R., Zimine, I., Badan, M., Lazeyras, F., & Schnider, A. (2001). Dissociated active and passive tactile shape recognition: a case study of pure tactile apraxia. *Brain*, 124, 2287–2298.
- Wernicke, C. (1895). Zwei Falle von Rindenlasionen. *Arbeiten Aus die Psychiatrische Klinik in Breslau*, 2, 33–53.
- Wiebers, D. O., Dale, A. J. D., Kokmen, E., & Swanson, J. W. (1998). The sensory examination. In D. O. Wiebers, A. J. D. Dale, E. Kokmen, & J. Swanson (Eds.), *Mayo clinic examinations in neurology* (7th ed.) (pp. 255–274). St Louis (MO): Mosby.
- Zoccolotti, P., Antonucci, G., Judica, A., Montenero, P., Pizzamiglio, L., & Razzano, C. (1989). Incidence and evolution of the hemi-neglect disorder in chronic patients with unilateral right brain-damage. *International Journal of Neuroscience*, 47, 209–216.