

Short Communication

Chronic Brain Hypoperfusion due to Multi-Vessel Extracranial Atherosclerotic Disease: A Potentially Reversible Cause of Cognitive Impairment

Apostolos Safouris^{a,*}, Anne-Sophie Hambye^b, Claudine Sculier^a, Sokratis G. Papageorgiou^c, Vasdekis N. Spyros^d, Marie-Dominique Gazagnes^a and Georgios Tsivgoulis^{c,e}

^aStroke Unit, Department of Neurology, Brugmann University Hospital, Brussels, Belgium

^bNuclear Medicine Department, Brugmann University Hospital, Brussels, Belgium

^cSecond Department of Neurology, University of Athens, School of Medicine, "Attikon" University Hospital, Athens, Greece

^dThird Department of Surgery, School of Medicine, University of Athens, Athens, Greece

^eInternational Clinical Research Center, St. Anne's University Hospital in Brno, Czech Republic

Accepted 29 May 2014

Abstract. A 62-year-old patient presented with persistent cognitive deficits 3 months after a right temporal ischemic stroke due to ipsilateral carotid occlusion. Work-up disclosed hemodynamically significant contralateral carotid artery stenosis and left subclavian steal phenomenon. Brain SPECT imaging revealed bihemispheric chronic brain hypoperfusion that substantially improved on repeat imaging when the subclavian steal was temporarily diminished by inflating a cuff around the left arm. Carotid endarterectomy of the asymptomatic carotid stenosis substantially ameliorated bihemispheric brain perfusion and reversed cognitive impairment. This case highlights that multi-vessel, extracranial atherosclerotic disease may cause chronic diffuse brain hypoperfusion that can be associated with cognitive impairment.

Keywords: Asymptomatic carotid stenosis, carotid endarterectomy, chronic brain hypoperfusion, SPECT, subclavian steal, transcranial Doppler

INTRODUCTION

Cerebrovascular hemodynamic failure has been hypothesized to result in impairment of cognitive status both in asymptomatic and symptomatic patients with carotid steno-occlusive disease and independent

of the presence of an underlying cerebral infarction [1, 2]. The former hypothesis rendered carotid artery disease as a potentially reversible cause of dementia. However, evidence of reversibility has been supported by case reports and small non-controlled studies [2]. We discuss the case of a patient with multi-vessel atherosclerotic extracranial artery disease who presented with cognitive impairment due to bihemispheric brain hypoperfusion. Carotid surgery of the only extracranial vessel that supplied the whole

*Correspondence to: Dr. Apostolos Safouris, Place Van Gehuchten 4, 1020 Bruxelles, Belgium. Tel.: +32 4773281; Fax: +32 4773467; E-mail: safouris@yahoo.com.

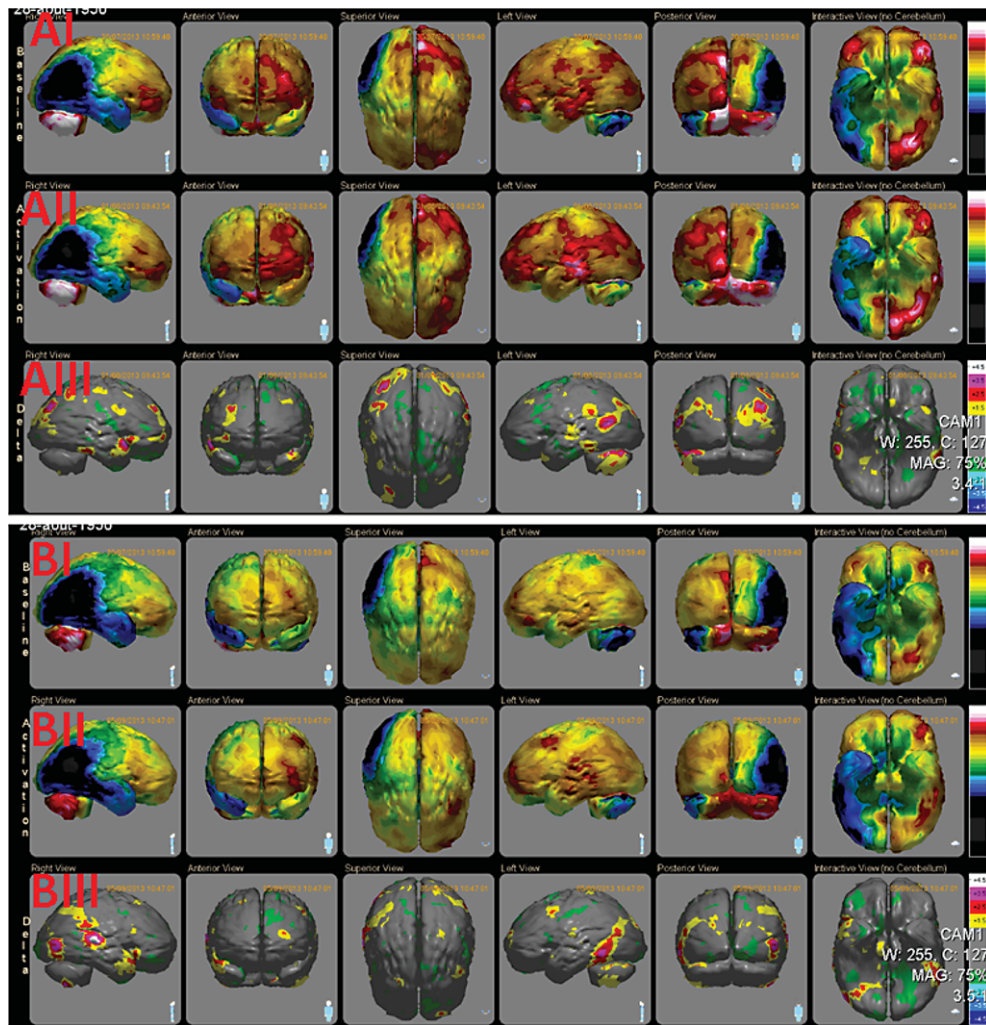


Fig. 1. Baseline SPECT imaging (AI), SPECT imaging with a cuff around the left arm (AII), and subtraction image (AIII) showing a moderately increased perfusion in both cerebral hemispheres following cuff inflation at 100 mmHg at the left arm due to reversal of subclavian steal syndrome leading to increased perfusion in anterior circulation. Baseline SPECT (BI), post-CEA SPECT (BII), and subtraction image (BIII) showing diffusely ameliorated perfusion in both hemispheres following left carotid artery surgery.

38 intracranial circulation resulted in amelioration of per- 49
 39 fusion deficits and resolution of cognitive deficits. 50

40 CASE DESCRIPTION 51

41 A 62-year-old man presented with mild left hemi- 52
 42 paresis (NIH Stroke Scale score: 4 points) due to 53
 43 an acute ischemic infarction in distribution of the 54
 44 temporal branch of right middle cerebral artery (Sup- 55
 45 plementary Figure 1A). The patient had no previous 56
 46 history of stroke or other neurological disorders. 57
 47 His medical history was significant for hypertension, 58
 48 hypercholesterolemia, and smoking. Physical exam- 59
 60
 61
 62

63 ination was remarkable for a left carotid murmur 49
 64 and substantial difference in blood pressure levels as 50
 65 measured in both arms: 110/50 mmHg on the right 51
 66 arm and 85/60 mmHg on the left arm. Diagnostic 52
 67 work-up revealed a thrombotic occlusion of the right 53
 68 internal carotid artery (Supplementary Figure 1B), a 54
 69 near-occlusion at the origin of left subclavian artery 55
 70 causing a subclavian steal syndrome (alternating flow 56
 71 in extracranial and intracranial left vertebral artery seg- 57
 72 ments), and a hemodynamically significant ($\geq 70\%$) 58
 73 stenosis of the left internal carotid artery (Fig. 2A–D). 59
 74 Left carotid artery stenosis was considered asymp- 60
 75 tomatic since no left hemispheric lesions were noted 61
 76 in brain magnetic resonance imaging (MRI) and the 62

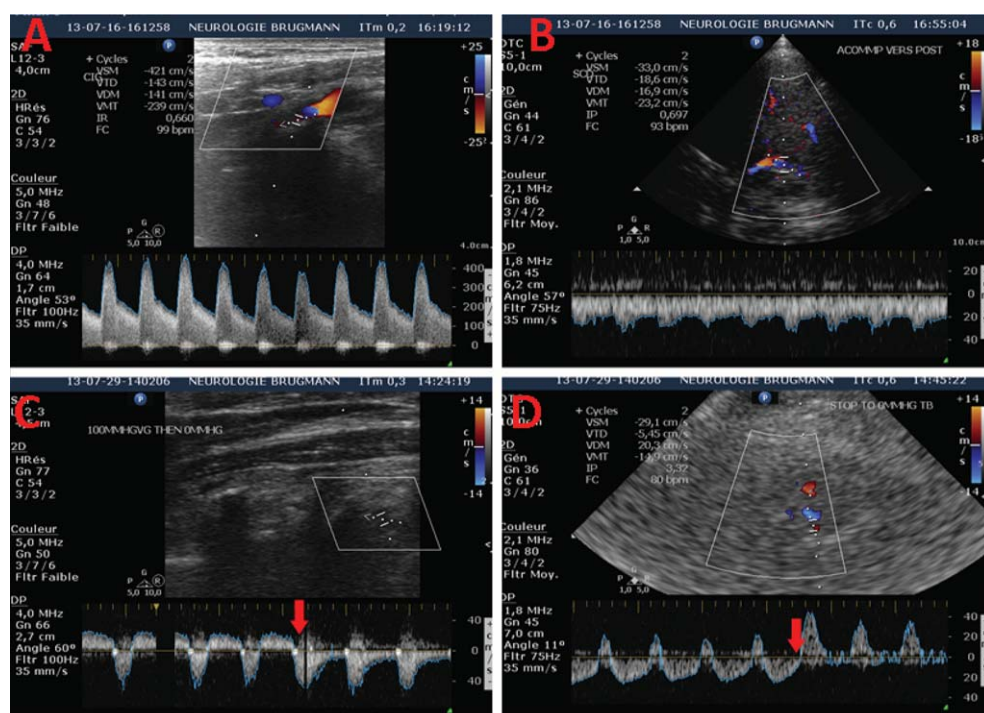


Fig. 2. Cervical Duplex showing a hemodynamically significant ($\geq 70\%$; Peak-Systolic Velocity: 421 cm/s, End-Diastolic Velocity: 143 cm/s) stenosis of left internal carotid artery (A). Transcranial Duplex showing a functional left posterior communicating artery directing flow from anterior to posterior circulation (B). Cervical Duplex showing alternating flow in transverse segment of left vertebral artery indicating a second-degree subclavian steal phenomenon (C). Note the complete flow reversal (red arrow) toward the arm following hyperemia-ischemia arm test (cuff inflation at suprasystolic blood pressure values followed by abrupt cuff deflation). Transcranial Duplex showing alternating flow in the intracranial segment of left vertebral artery indicating a second-degree subclavian steal phenomenon affecting the intracranial circulation (D). Note the complete flow reversal (red arrow) toward the arm following hyperemia-ischemia arm test (cuff inflation at suprasystolic blood pressure values followed by abrupt cuff deflation).

63 patient denied any previous focal neurologic symptoms
 64 that could be attributed to left hemispheric transient
 65 ischemic attack (TIA). The patient did not report any
 66 episode of loss of consciousness or other neurological
 67 symptoms during the use of his left arm that could be
 68 attributed to the subclavian steal phenomenon which
 69 was also considered as asymptomatic. Neuropsychological
 70 testing disclosed a deficit of visuoconstructive
 71 skills, attention, low short-term memory scores, and
 72 consolidation deficits in verbal long-term memory. The
 73 patient's Mini-Mental State Examination (MMSE) was
 74 22/30. All these deficits were originally attributed to
 75 the right temporal infarction, and the patient was
 76 diagnosed with vascular dementia caused by a strategic
 77 infarction.

78 The patient presented at follow-up at 3 months
 79 with no motor or sensory deficit but with persisting
 80 cognitive impairment. There were no behavioral
 81 symptoms including loss of self-control and apathy.
 82 Transcranial Color-Coded Duplex examination
 83 revealed a functional collateral intracranial circulation

with left internal carotid artery being the sole vessel
 supplying the circle of Willis via patent anterior
 communicating artery and patent posterior
 communicating arteries (Supplementary Figure 2D).
 Interestingly, the subclavian steal syndrome affected
 the intracranial circulation with functional posterior
 communicating arteries directing flow from anterior
 to posterior circulation (Fig. 2B). Moreover, a
 bidirectional flow was documented in basilar artery
 with a retrograde systolic component (Fig. 2D).

The hypothesis of a chronic bihemispheric
 hypoperfusion was raised given the diffuse cognitive
 deficits (not restricted to the right temporal lobe)
 and the patient underwent a brain single-photon
 emission computed tomography (SPECT) perfusion
 HMPAO - Tc99m 4 months post stroke, which
 detected perfusional anomalies that extended well
 beyond the ischemic lesions, concerning both
 hemispheres (Supplementary Figure 1C). In the
 interest of examining whether the subclavian steal
 phenomenon could have a significant impact on
 cerebral hemodynamics, transcranial

84
 85
 86
 87
 88
 89
 90
 91
 92
 93
 94
 95
 96
 97
 98
 99
 100
 101
 102
 103
 104

Doppler was repeated by inflating a cuff around the left arm to 100 mmHg during examination. This intervention reduced the severity of the steal phenomenon in the left vertebral artery but also improved the flow at the basilar artery where the persistence of retrograde component was minimal. A complete flow reversal towards the arm was noted both in extra- and intracranial vertebral artery segments following cuff deflation (Fig. 2C-D). Brain SPECT was repeated under the same conditions (a cuff inflated on the left arm at 100 mmHg 10 minutes before to 20 minutes after injection). Subtraction images showed moderate improvement of perfusion, not only on the periphery of the right ischemic area but also at the entire left cerebral hemisphere (Fig. 1, AI-AIII).

The patient was referred for vascular surgery and underwent left carotid endarterectomy (CEA) under the hypothesis that improving flow of left carotid artery would result in amelioration of brain perfusion, which in turn might induce a meaningful improvement in cognition. The intervention was also conducted with concomitant inflation of a cuff at 100 mmHg around the left arm as a prophylactic measure for perioperative stroke during the occlusion of the left carotid artery given the previous SPECT data showing amelioration in bihemispheric perfusion due to partial reversal of subclavian steal syndrome. The patient experienced no complication following carotid surgery. Post-operative brain SPECT indeed showed a discrete improvement of brain perfusion of the right hemisphere around the area of ischemia (temporal lobe) and a marked improvement of the perfusion of the left frontal, parietal and temporal lobes (Fig. 1, BI-BIII). Both the patient and his relatives noted a substantial cognitive improvement followed by amelioration in instrumental activities of daily living. His MMSE was 27/30. The patient declined repeating a detailed neuropsychological testing.

CONCLUSIONS

In patients with bilateral hemodynamically significant atherosclerotic carotid artery disease brain may be perfused by collateral circulation via the posterior cerebral and external carotid arteries [3]. Among different collaterals, the posterior communicating arteries maintain a crucial role in ensuring blood flow to the anterior circulation by reversing their normal postero-grade flow. In the described case, normal collaterality was compromised by the subclavian steal phenomenon of the left vertebral artery with posterior communicat-

ing arteries directing blood to the left upper limb at the expense of the entire brain circulation. As a consequence, the flow in the basilar artery was rendered bidirectional, draining blood from the anterior circulation via the left posterior communicating arteries [4], thus resulting in chronic bihemispheric hypoperfusion that was clinically manifested by cognitive impairment. Left CEA significantly improved brain perfusion as assessed by brain SPECT, which in turn alleviated patient's cognitive deficits.

Subclavian steal syndrome is a relatively frequent finding during cervical arteries duplex sonography. Although it is commonly asymptomatic, it should be noted that sometimes it may provoke posterior circulation TIA and may rarely require intervention especially when extending in the intracranial circulation [5, 6]. Interestingly, anterior circulation symptoms have been described in previous reports of subclavian steal syndrome with concomitant carotid disease [7]. Notably, we provide hemodynamic evidence using repeat SPECT imaging that even transient reduction of subclavian steal by cuff inflation at the affected arm may result in substantial improvement of anterior circulation perfusion. Moreover, inflating a cuff at suprasystolic blood pressures levels at the ipsilateral (to the subclavian artery) arm may constitute a potentially safe and effective measure to improve intracranial circulation during CEA in patients with carotid artery stenosis and concomitant subclavian artery syndrome. However, larger case series are needed to provide more additional evidence whether this maneuver reduces the risk of periprocedural stroke in this specific group of patients.

A carotid stenosis is considered asymptomatic in the absence of ischemic stroke or TIA in the distribution of the affected artery. Its treatment is mostly medical with CEA being considered as a therapeutic option in selected patients that present with a stenosis $\geq 70\%$ [8]. However, we considered left carotid artery stenosis in our patient as symptomatic since our hemodynamic work-up disclosed the left carotid artery as the sole vessel supplying the circle of Willis via patent and functional anterior and posterior communicating arteries. Consequently, we hypothesized that (i) the cognitive impairment in our patient may be attributed to the diffuse brain hypoperfusion instead of post-stroke dementia and (ii) the cerebral hypoperfusion may be improved following carotid surgery. The fact that asymptomatic carotid stenosis has been previously correlated with cognitive impairment and brain imaging abnormalities lends support to our hypothesis [9, 10]. The resolution of cognitive deficits in our

patient coupled with the substantial improvement in bihemispheric perfusion on SPECT imaging is in line with recent reports that documented benefit on cognitive functions post CEA [11] or stenting [12, 13] of otherwise asymptomatic carotid stenosis. There are still limited data to explain the deleterious effects of chronic brain hypoperfusion on cognitive function. A recent study revealed diffuse cognitive deficits and disrupted brain connectivity as measured by MRI fractional anisotropy in patients with asymptomatic carotid stenosis [14]. However, it should be acknowledged that whether chronic brain hypoperfusion should be aggressively treated by CEA in cognitively impaired patients with concomitant multi-vessel asymptomatic stenoses of cervical arteries remains an unproven challenge given the recent negative results of Randomized Evaluation of Carotid Occlusion and Neurocognition (RECON) trial [15].

In conclusion, the present case highlights that multi-vessel, extracranial atherosclerotic disease may cause chronic diffuse brain hypoperfusion that can be associated with significant cognitive impairment. Carotid revascularization procedures in the presence of functional intracranial collateral circulation may lead to resolution of brain hypoperfusion and reversal of cognitive deficits.

ACKNOWLEDGMENTS

Dr. Georgios Tsivgoulis has been supported by European Regional Development Fund - Project FNUSA-ICRC (No. CZ.1.05/1.1.00/02.0123).

Authors' disclosures available online (<http://www.jalz.com/disclosures/view.php?id=2368>).

SUPPLEMENTARY MATERIAL

The supplementary figure is available in the electronic version of this article: <http://dx.doi.org/10.3233/JAD-141203>.

REFERENCES

- [1] Marshall RS, Festa JR, Cheung YK, Chen R, Pavol MA, Derdeyn CP, Clarke WR, Videen TO, Grubb RL, Adams HP, Powers WJ, Lazar RM (2012) Cerebral hemodynamics and cognitive impairment: Baseline data from the RECON trial. *Neurology* **78**, 250-255. 243-246
- [2] Sasoh M, Ogasawara K, Kuroda K, Okuguchi T, Terasaki K, Yamadate K, Ogawa A (2003) Effects of EC-IC bypass surgery on cognitive impairment in patients with hemodynamic cerebral ischemia. *Surg Neurol* **59**, 455-460. 248-251
- [3] Liebeskind DS (2003) Collateral circulation. *Stroke* **34**, 2279-2284. 252-253
- [4] Harper C, Cardullo PA, Weyman AK, Patterson RB (2008) Transcranial Doppler ultrasonography of the basilar artery in patients with retrograde vertebral artery flow. *J Vasc Surg* **48**, 859-864. 254-256
- [5] Labropoulos N, Nandivada P, Bekelis K (2010) Prevalence and impact of the subclavian steal syndrome. *Ann Surg* **252**, 166-170. 258-260
- [6] Tan TY, Schminke U, Lien LM, Tegeler CH (2002) Subclavian steal syndrome: Can the blood pressure difference between arms predict the severity of steal? *J Neuroimaging* **12**, 131-135. 261-263
- [7] Hennerici M, Klemm C, Rautenberg W (1988) The subclavian steal phenomenon: A common vascular disorder with rare neurologic deficits. *Neurology* **38**, 669-673. 265-267
- [8] Ricotta JJ, Aburahma A, Ascher E, Eskandari M, Faries P, Lal BK (2011) Updated Society for Vascular Surgery guidelines for management of extracranial carotid disease: Executive summary. *Society for Vascular Surgery J Vasc Surg* **54**, 832-836. 268-272
- [9] Cheng HL, Lin CJ, Soong BW, Wang PN, Chang FC, Wu YT, Chou KH, Lin CP, Tu PC, Lee IH (2012) Impairments in cognitive function and brain connectivity in severe asymptomatic carotid stenosis. *Stroke* **43**, 2567-2573. 273-275
- [10] Balucani C, Viticchi G, Falsetti L, Silvestrini M (2012) Cerebral hemodynamics and cognitive performance in bilateral asymptomatic carotid stenosis. *Neurology* **79**, 1788-1795. 277-279
- [11] Takaiwa A, Kuwayama N, Akioka N, Kurosaki K, Hayashi N, Endo S, Kuroda S (2013) Effect of carotid endarterectomy on cognitive function in patients with asymptomatic carotid artery stenosis. *Acta Neurochir (Wien)* **155**, 627-633. 280-283
- [12] Chen YH, Lin MS, Lee JK, Chao CL, Tang SC, Chao CC, Chiu MJ, Wu YW, Chen YF, Shih TF, Kao HL (2012) Carotid stenting improves cognitive function in asymptomatic cerebral ischemia. *Int J Cardiol* **157**, 104-107. 284-286
- [13] Grunwald IQ, Papanagiotou P, Reith W, Backens M, Supprian T, Politi M, Vedder V, Zercher K, Muscalla B, Haass A, Krick CM (2010) Influence of carotid artery stenting on cognitive function. *Neuroradiology* **52**, 61-66. 288-291
- [14] Lin CJ, Tu PC, Chern CM, Hsiao FJ, Chang FC, Cheng HL, Tang CW, Lee YC, Chen WT, Lee IH (2014) Connectivity features for identifying cognitive impairment in presymptomatic carotid stenosis. *PLoS One* **9**, e85441. 292-295
- [15] Marshall RS, Festa JR, Cheung YK, Pavol MA, Derdeyn CP, Clarke WR, Videen TO, Grubb RL, Slane K, Powers WJ, Lazar RM, Investigators RECON (2014) On behalf of the RECON Investigators. Randomized Evaluation of Carotid Occlusion and Neurocognition (RECON) trial: Main results. *Neurology* **82**, 744-751. 296-301