

Thrombolysis in Recurrent Stroke—Beyond Guidelines: A Case Report

Suman Kushwaha, DM, Seema Malik, MD, Garima Sarraf, MD,
and Aldrin Dung Dung, DM

Intravenous (IV) thrombolysis is approved and proven treatment for acute ischemic stroke in the window period of 4.5 hours. The therapeutic benefit is not extended to many patients with prior stroke and recurrent stroke as they are excluded in the protocol for thrombolysis. We report a case of successful IV thrombolysis in a young patient with recent prior stroke and recurrent stroke. A 35-year-old male presented in our emergency with recurrent stroke had a history of acute onset vertigo, headache, and vomiting. He was diagnosed to have posterior circulation stroke before 5 days on the basis of clinical history and neuroimaging. On the day of presentation to our hospital, he had developed new symptom of acute onset right hemiparesis with dysarthria. IV tissue plasminogen activator administered within 2 hours of onset of new symptoms resulted in significant improvement in spite of the recent prior stroke. **Key Words:** Recurrent stroke—thrombolysis—tissue plasminogen activator—ischemia—hemiparesis.

© 2014 by National Stroke Association

Case Report

A nonhypertensive, nondiabetic, 35-year-old male patient came to our outpatient department with a history of acute onset vertigo, headache, recurrent vomiting, and slurring of speech 5 days back, which was maximum at onset and then static. His 3-day-old magnetic resonance imaging (MRI) scan of the brain (Fig 1) had established bilateral cerebellar and vermis infarct. He was started on antiplatelets, statins, and symptomatic treatment for vertigo. He had developed acute onset weakness of right upper and lower limb with facial palsy and severe dysarthria on the day of presentation. He was brought into the emer-

gency department within 2 hours of symptom onset. On examination, his blood pressure and pulse rate (PR) were 136/80 mm Hg and 84 per minute respectively. He had right upper motor neuron seventh nerve palsy and severe dysarthria. The motor power was 0/5 in right upper and lower limb and 5/5 in left side. Right plantar was extensor. There were mild cerebellar signs on the left side. National Institute of Health Stroke Scale (NIHSS) was 12 at the time of admission. Noncontrast computed tomography of the brain showed previous cerebellar infarct and no hemorrhage. We decided to thrombolysed the patient with tissue plasminogen activator (tPA) in spite of recent prior stroke as the patient had a new neurologic deficit. Patient was thrombolysed with intravenous (IV) tPA (0.9 mg/kg) according to his weight, 10% given as bolus and rest over 60 minutes. The weakness started to improve during tPA infusion. NIHSS improved and modified Rankin scale was 1 after 24 hours. The repeat MRI of the brain (Fig 2) showed infarcts in right pons on diffusion weighted images with no hemorrhagic transformation on gradient echo. He was discharged after 5 days with mild dysarthria and modified Rankin scale of 1.

From the Department of Neurology, Institute of Human Behaviour & Allied Sciences, Delhi, India.

Received February 10, 2014; revision received February 26, 2014; accepted March 5, 2014.

Address correspondence to Suman Kushwaha, DM, Department of Neurology, Institute of Human Behaviour & Allied Sciences, Delhi 110095, India. E-mail: sumankushwaha@gmail.com.

1052-3057/\$ - see front matter

© 2014 by National Stroke Association

<http://dx.doi.org/10.1016/j.jstrokecerebrovasdis.2014.03.003>

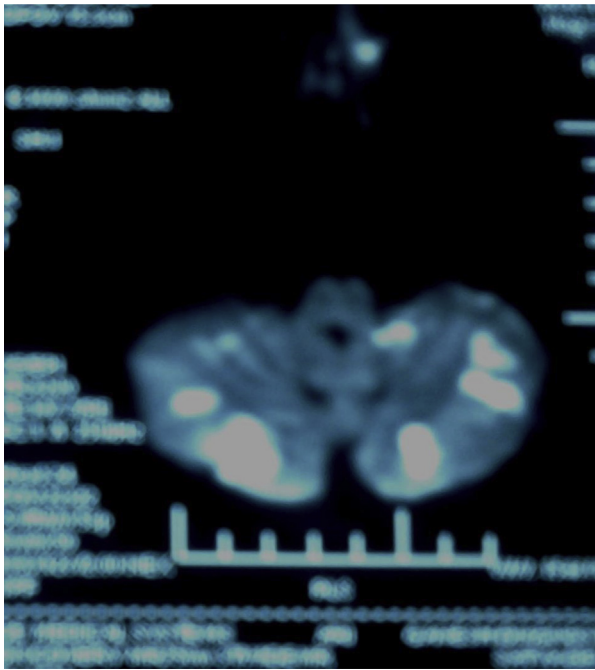


Figure 1. DW-MRI after the first stroke showing bilateral cerebellar and vermis infarcts.

Discussion

The gold standard treatment for acute ischemic stroke is tPA administration within the window period of 4.5 hours.¹ Stroke within last 3 months is contraindication for IV thrombolysis according to the guidelines for thrombolysis in acute ischemic stroke.² This is because of increased risk of hemorrhagic transformation in previous infarct after thrombolysis. Data on the rate of hemorrhage in patients who are thrombolysed with a recent prior stroke is not sufficient. In the study

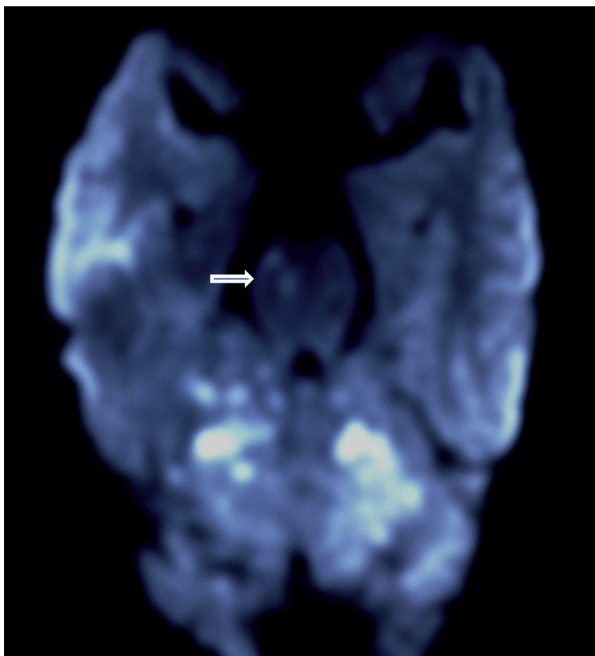


Figure 2. DW-MRI after thrombolysis showing 2 new small diffusion restricted areas in right pons.

by Mishra et al³ who have examined the effect of IV alteplase in the patients with diabetes mellitus, previous stroke and their combinations, their results showed improved outcomes among the patients with diabetes mellitus or previous stroke. The case that we have described clearly demonstrates the view against the contraindication of thrombolysis in the patients with prior stroke in the current guidelines. Tisserand et al⁴ in their study with 115 patients found recent silent infarct (RSI) on MRI in 21 patients. Similar hemorrhagic complication was observed in both RSI positive and negative groups. Some case series and case reports have now shown beneficial effects of thrombolysis in patients with recent prior stroke.^{5,6} We thrombolysed our patient who had recurrent strokes, recent posterior circulation stroke, and presented to us with new neurologic deficit as right hemiparesis and dysarthria in a window period of 2 hours. The hemorrhage was ruled out in our patient in a computed tomography of the head. Furthermore, the MRI of the brain diffusion weighted images showed infarcts in right pons with the pre-existing cerebellar infarcts. Our patient has recurrent stroke, a prior stroke of 5-day duration, and a new stroke. The new stroke onset, right hemiparesis was thrombolysed successfully without deterioration of the recent previous stroke. IV thrombolysis may be safe for the patients with previous stroke or recurrent strokes as shown in our case.

Conclusion

This case highlights that it may be safe and effective to treat a patient with recurrent stroke or a patient with previous stroke with IV thrombolysis. There is no justification to exclude these patients from receiving the highly effective treatment for acute ischemic stroke. The beneficial effect of thrombolysis in patients with prior stroke for young patients should be offered. The protocol deviation for thrombolysis can be permitted for the selected group of patients of recent prior stroke as done in our patient with good outcome.

References

1. Wardlaw JM, Murray V, Berge E, et al. Thrombolysis for acute stroke. *Cochrane Database Syst Rev* 2009;CD000213.
2. Jauch EC, Saver JL, Adams HP, et al. Guidelines for the early management of patients with acute ischemic stroke: a guideline for healthcare professionals from the American Heart Association/American Stroke Association. *Stroke* 2013;44:870-947.
3. Mishra NK, Ahmed N, Davalos A, et al. SITS and VISTA collaborators. Thrombolysis outcomes in acute ischemic stroke patients with prior stroke and diabetes mellitus. *Neurology* 2011;77:1866-1872.
4. Tisserand M, Le Guennec L, Touzé E, et al. Prevalence of MRI defined recent silent ischemia and associated bleeding risk with thrombolysis. *Neurology* 2011;76:1288-1295.
5. Alhazzaa M, Sharma M, Blacquiere D, et al. Thrombolysis despite recent stroke: a case series. *Stroke* 2013;44:1736-1738.
6. Nguyen TH, Vo D, Ngo MB, et al. Thrombolysis in recurrent lacunar stroke: a case example. *Eur J Neurol* 2008;15:1409-1411.