

# Stylocarotid artery syndrome

Joshua David, BS, Michael Lieb, DO, and Saum A. Rahimi, MD, *New Brunswick, NJ*

Stylocarotid artery syndrome is a rare condition that results from compression of the internal or external carotid artery by the styloid process of the temporal bone. Here we present the case of a patient suffering from syncope, monoparesis of the right arm, and dysarthria due to recurrent transient ischemic attacks that resulted from severe compression of the midsegment of the left extracranial internal carotid artery between an elongated styloid process and a C2 vertebral body osteophyte. This case demonstrates successful surgical management of a condition rarely encountered by the vascular surgeon. (*J Vasc Surg* 2014;60:1661-3.)

Stylocarotid artery syndrome, a vascular variant of Eagle syndrome, can result in neurologic symptoms including transient ischemic attack (TIA), syncope, and even stroke. After surgical removal of the styloid process through an extraoral approach, there remained no residual stenosis on follow-up duplex ultrasound imaging, and the patient remained symptom free at 5-month postoperative follow-up. This case offers a perspective of an unusual clinical problem in vascular surgery. We obtained consent to publish from the patient.

## CASE REPORT

The patient, a 69-year-old woman, was transferred from another hospital and presented with recurrent TIAs during the past 3 weeks. She reported weakness in her right upper and lower extremities, with associated syncopal episodes. These episodes lasted 2 minutes, during which she was unable to speak but retained the ability to understand people. She also claimed to notice an aura before episodes, which lasted about 2 minutes. She also described the onset of these symptoms with the movement of her neck to the right and yawning and reported hearing “swooshing” in her left ear. Computed tomography angiography revealed bilateral large and elongated styloid processes, with significant compression of the left internal carotid artery, indicative of Eagle syndrome (Fig 1). In addition, the internal carotid artery was compressed between the styloid and C2 osteophyte (Fig 2).

The patient was nasotracheally intubated, and the incision was carried posterior to the ear to facilitate high exposure. The posterior belly of the digastric muscle was divided, exposing the styloid process. The compressing styloid process was dissected free and then removed. Because of the high exposure, care was taken to identify all cranial nerves, which were protected with vessel loops. After this was completed, on-table angiography was performed, which demonstrated a patent carotid bifurcation with patent

internal carotid artery and no area of stenosis (Fig 3). The patient recovered from the procedure uneventfully. The patient was discharged the following day with no cranial nerve defect and no further TIAs. Follow-up duplex ultrasound showed no stenosis, and the patient remained symptom free at 5-month follow-up.

## DISCUSSION

Eagle syndrome has been described as the various symptoms resulting from an elongated styloid process or mineralized stylohyoid ligament. The styloid process is a slender, bony outgrowth of the temporal bone that serves as an attachment point for the styloglossus, stylopharyngeus, and stylohyoid muscles as well as the stylohyoid and stylomandibular ligaments. In addition, neurovascular structures adjacent to the styloid process, including both of the internal and external carotid arteries, the internal jugular vein, and cranial nerves V, IX, X, and XII, are particularly vulnerable to injury by an elongated structure. The syndrome was originally described in 1937 by Watt W. Eagle, an otolaryngologist, who identified two separate types.<sup>1-3</sup> Ipsilateral facial and neck pain, dysphagia, or a host of other symptoms following pharyngeal trauma or tonsillectomy define the “classic” version of Eagle syndrome, which is therefore well described in oral surgery and otolaryngology literature.<sup>4</sup> The second type, stylocarotid artery syndrome, is of vascular nature and results from the impingement of the internal or external carotid artery by the styloid process. In this type, the styloid process is not necessarily elongated, but it can also be due to lateral or medial deviation.<sup>4</sup> The symptoms in these patients can include cervicofacial pain (due to irritation of the periarterial nerve plexus) or, as in our patient, TIAs. This second type is less common in the literature, and to our knowledge, there are only a few descriptions in the neurosurgery and neuroradiology literature that implicate stylocarotid artery syndrome as the cause of TIAs.<sup>5-8</sup> The incidence of enlarged styloid processes in the population is contested, with estimates ranging from 4% by Eagle himself to as high as 18.2% in an examination of radiographs by Correll et al.<sup>9</sup> However, most researchers agree that symptoms are manifested in only a small minority of patients.<sup>4</sup> The only established treatment for the stylocarotid artery variant of Eagle syndrome is surgical removal of the offending structure.<sup>4</sup> Both intraoral and extraoral approaches are available. The intraoral approach

From the Division of Vascular Surgery, Rutgers - Robert Wood Johnson Medical School.

Author conflict of interest: none.

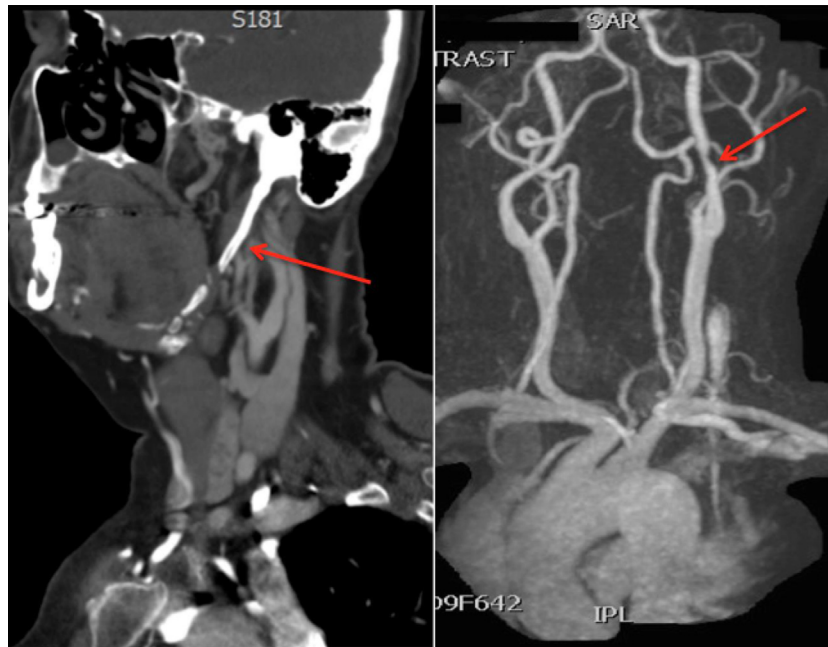Reprint requests: Saum Rahimi, MD, 1 Robert Wood Johnson Place, MEB-541, New Brunswick, NJ 08903 (e-mail: rahimisa@rvjms.rutgers.edu).

The editors and reviewers of this article have no relevant financial relationships to disclose per the JVS policy that requires reviewers to decline review of any manuscript for which they may have a conflict of interest.

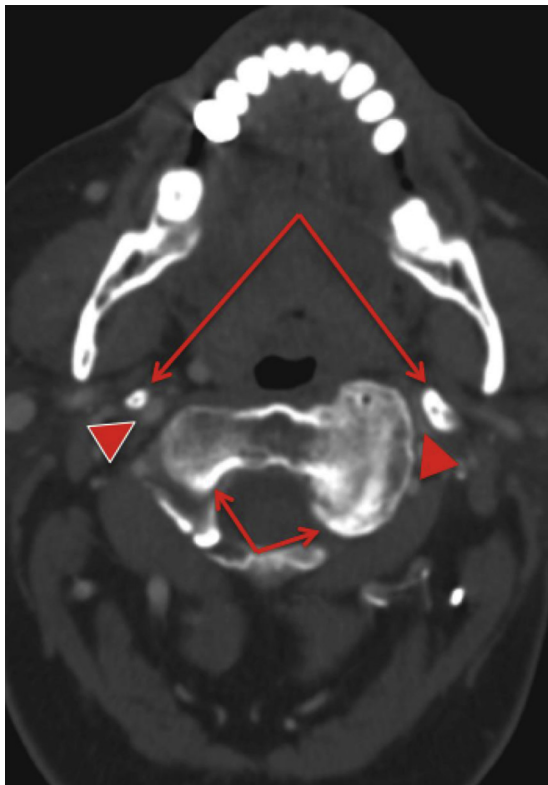
0741-5214/\$36.00

Copyright © 2014 by the Society for Vascular Surgery.

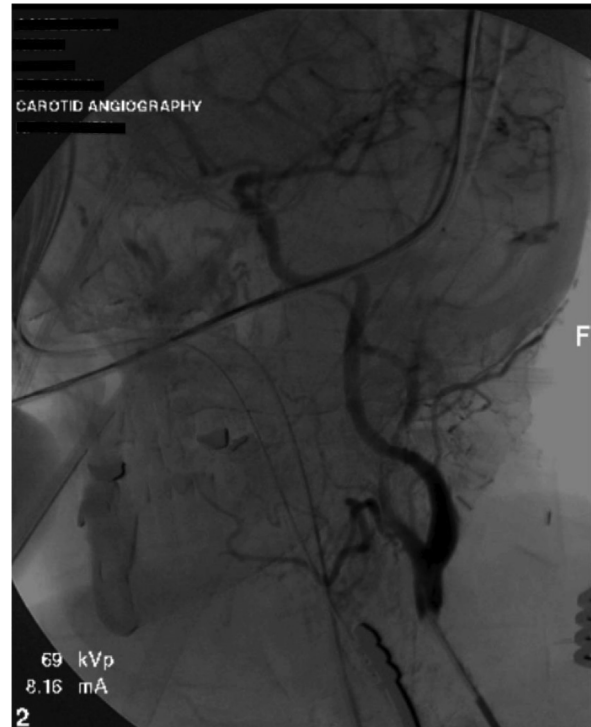<http://dx.doi.org/10.1016/j.jvs.2014.05.048>



**Fig 1.** Sagittal reconstruction view (*left*) and global reconstruction view (*right*). The *arrows* point to the elongated styloid process (*left*) and stenosis of the internal carotid artery (*right*).



**Fig 2.** The *short arrows* point to the normal C2 vertebra (patient's right side) and enlarged C2 osteophyte (patient's left side). The *long arrows* point to the bilateral elongated styloid processes. The internal carotid arteries (*arrowheads*) are seen between these two structures, with unilateral compression on the patient's left side.



**Fig 3.** On-table completion angiogram after removal of the styloid process.

is a shorter procedure, will avoid external scarring, and has less risk for facial nerve injury. The extraoral approach, however, described by Loeser and Caldwell as early as 1942, offers a better view of the surgical field, affords

higher exposure to the carotid artery, and is generally preferred<sup>10,11</sup> High exposure of the carotid artery is further improved with nasotracheal intubation.

## CONCLUSIONS

Although Eagle syndrome may be a finding on imaging, the patient will often be asymptomatic. In this case, nothing should be done. However, stylocarotid artery syndrome has been implicated as the cause of various cerebral neurovascular events, including TIAs, stroke, nerve injury, carotid artery dissection, and even death, and therefore it must be considered on presentation of a wide variety of symptoms ranging from cervicofacial pain to cerebral ischemia.<sup>4,12-15</sup> This case offers an example of surgical management of patients with symptomatic stylocarotid artery syndrome and the unusual combination of the styloid process and osteophyte leading to the symptoms. Vascular surgeons must be aware of this syndrome and its symptoms and keep it as part of the differential diagnosis when faced with TIAs accompanying head or neck movement and flexion.

## REFERENCES

1. Eagle WW. Elongated styloid process. *Arch Otolaryngol* 1937;25:584-7.
2. Eagle WW. Elongated styloid process, further observations and a new syndrome. *Arch Otolaryngol* 1948;47:630-40.
3. Eagle WW. Symptomatic elongated styloid process: report of two cases of styloid process-carotid artery syndrome with operation. *Arch Otolaryngol* 1949;49:490-503.
4. Piagkou M, Anagnostopoulou S, Kouladouros K, Piagkos G. Eagle's syndrome: a review of the literature. *Clin Anat* 2009;22:545-58.
5. Infante-Cossio P, Garcia-Perla A, Gonzalez-Garcia A, Gil-Peralta A, Gutierrez-Perez JL. Compression of the internal carotid artery due to elongated styloid process. *Rev Neurol* 2004;39:339-43.
6. Farhat HI, Elhammady MS, Ziayee H, Aziz-Sultan MA, Heros RC. Eagle syndrome as a cause of transient ischemic attacks. *J Neurosurg* 2009;110:90-3.
7. Chuang WC, Short JH, McKinney AM, Anker L, Knoll B, McKinney ZJ. Reversible left hemispheric ischemia secondary to carotid compression in Eagle syndrome: surgical and CT angiographic correlation. *AJNR Am J Neuroradiol* 2007;28:143-5.
8. Nagakawa D, Ota T, Iijima A, Saito N. Diagnosis of Eagle syndrome with 3-dimensional angiography and near-infrared spectroscopy: case report. *Neurosurgery* 2011;68:E847-9.
9. Correll RW, Jensen JL, Taylor JB, Rhyne RR. Mineralization of the stylohyoid-stylomandibular ligament complex: a radiographic incidence study. *Oral Surg Oral Med Oral Pathol* 1979;48:286-91.
10. Loeser LH, Cardwell EP. Elongated styloid process: a cause of glossopharyngeal neuralgia. *Arch Otolaryngol* 1942;36:198-203.
11. Diamond LH, Cottrell DA, Hunter MJ, Papageorge M. Eagle's syndrome: a report of 4 patients treated using a modified extraoral approach. *J Oral Maxillofac Surg* 2001;59:1420-6.
12. Fini G, Gasparini G, Filippini F, Becelli R, Marcotullio D. The long styloid process syndrome or Eagle's syndrome. *J Craniomaxillofac Surg* 2000;28:123-7.
13. Bensoussan Y, Letourneau-Guillon L, Ayad T. An atypical presentation of Eagle syndrome with hypoglossal nerve palsy and Horner syndrome. *Head Neck* 2014 Mar 11. [Epub ahead of print].
14. Kumar P, Rayamane AP, Subbaramaiah M. Sudden death due to Eagle syndrome: a casereport. *Am J Forensic Med Pathol* 2013;34:231-3.
15. Razak A, Short JL, Hussain SI. Carotid artery dissection due to elongated styloid process: a self-stabbing phenomenon. *J Neuroimaging* 2014;24:298-301.

Submitted Apr 16, 2014; accepted May 21, 2014.