



Section Editor  
Mitchell S.V. Elkind,  
MD, MS

# Clinical Reasoning: A puzzling case of amnesia

Olena Bereznyakova, MD  
Geneviève Milot, MD  
Mélanie Brisson, MD  
Robert Laforce, Jr., MD, PhD

Correspondence to  
Dr. Laforce:  
robert.laforce@fmed.ulaval.ca

## SECTION 1

A 60-year-old right-handed woman was admitted to the hospital and discharged the same day following an uneventful endovascular repair (coil embolization) of an asymptomatic aneurysm. She returned to the emergency department (ED) on the next day with fever and confusion. She was described by family as doing well in the morning, but vomiting several times after lunch. She also showed a brief but sustained deviation of the eyes and head to the left, followed by clonic movements of the left hemibody. On her way to the ED, she showed amnesia for recent events and repeatedly asked why she was going to the hospital. In fact, she could not recall events that occurred in a 2-week period surrounding neurosurgery.

Her medical history included hypertension, hypothyroidism, migraines, and a complex partial seizure 6

months prior to coiling treated with levetiracetam 500 mg BID. She was also followed by neurosurgery for 2 small saccular aneurysms of the right middle cerebral artery. There was no history of alcohol or drug abuse. Family history was negative for neurologic disorders.

Upon arrival to the ED, her blood pressure was 128/84 mm Hg, her temperature was 38.6°C, and she showed confusion. She did not report any headaches. Neurologic examination revealed no focal motor or sensory deficits.

## Questions for consideration:

1. What is your differential at this point?
2. What other investigations would help narrow the differential?

[GO TO SECTION 2](#)

Supplemental data  
at [Neurology.org](#)

From the Faculté de Médecine (O.B., R.L.), Université Laval, Québec; and the Département des Sciences Neurologiques (G.M., R.L.), Département de Radiologie (M.B.), and Clinique Interdisciplinaire de Mémoire (R.L.), CHU de Québec, Canada.

Go to [Neurology.org](#) for full disclosures. Funding information and disclosures deemed relevant by the authors, if any, are provided at the end of the article.

## SECTION 2

The differential diagnosis is broad and includes conditions known to cause fever, confusion, and seizure in the postoperative period. Vascular (postoperative stroke, subarachnoid hemorrhage, venous sinus thrombosis), infectious (meningitis/encephalitis), metabolic (electrolytes or thyroid deficiencies), epilepsy, and a delirium of multifactorial etiology were all considered.

Basic workup included normal complete blood count, electrolytes, thyroid-stimulating hormone, liver enzymes, glucose, ECG, and chest radiography. However, urinalysis showed leukocyturia and her 24-hour urine culture was positive for *Escherichia coli*. CT scan of the brain was negative for acute ischemia, hemorrhage, or space-occupying lesions. EEG showed no epileptiform activity. In light of the relatively sudden onset of confusion and absence of physical signs of meningeal irritation, both meningitis and encephalitis were considered improbable by ED physicians, and lumbar puncture was never performed. The patient was admitted to the internal medicine ward with a working diagnosis of delirium secondary to urinary tract infection and treated with ciprofloxacin 500 mg BID. MRI of the brain performed on the day following her readmission was read as normal.

Over the next 48 hours, the patient's temperature normalized and her cognitive and behavioral profile emerged more clearly. Nursing staff began to report that she could not learn new information or recognize them even after a short delay. The patient could not explain why she was hospitalized but upon questioning stated that she was in the hospital because of her migraines, and that she wanted to leave as soon as possible to go back to work (at the same time admitting being retired). It became apparent that she fabricated several stories. Her family further insisted that "she was not herself anymore." Previously described as a timid and introverted computer technician, she was now talkative and disinhibited with friends, family, and hospital personnel.

### Questions for consideration:

1. What is the differential diagnosis of amnesic syndromes of sudden, subacute, and slowly progressive onset?
2. Based on her clinical evolution and triad of symptoms including amnesia, confabulation, and personality changes, what is your diagnosis, and where do you localize the lesion?
3. What further investigations would you pursue to clarify the diagnosis?

**GO TO SECTION 3**

### SECTION 3

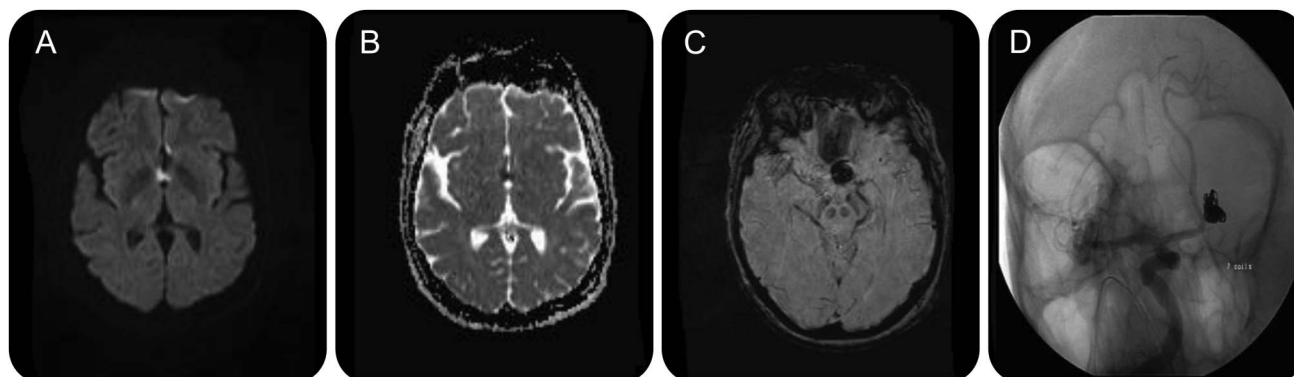
Table e-1 on the *Neurology*<sup>®</sup> Web site at Neurology.org lists the main differential diagnoses to consider when faced with an amnesic syndrome. Neurology was consulted on the third day of the admission in light of “persistent confusion” and the possibility of an ictal etiology. Neurologic examination revealed a cooperative but apathetic patient with flat affect. She was alert but disoriented to time, partially oriented to place, and fully oriented to person. Her attention span was normal and she was able to follow complex 3-step commands. Speech was fluent and coherent with normal comprehension, naming, and repetition. Anterograde memory was significantly impaired—she could not remember recent events. She could not recall any of 5 words after a 5-minute delay. However, she benefited from cueing to improve her performance. She also showed confabulations provoked by direct questioning and that were not bizarre. The rest of the neurologic examination including cranial nerves, motor, sensory, reflexes, and cerebellar function was normal.

Her amnesia, confabulation, and personality changes prompted a number of tests including a 5-hour EEG monitoring, which was normal. Formal neuropsychological testing documented an isolated and highly significant deficit in verbal episodic memory with evidence of a poor learning curve on the California Verbal Learning Test (from 4 to 6 items out of 9 after 4 presentations of the list) and delayed recall ranging between 0 and 2 out of 9 (first percentile, impaired range) on free and cued recall, respectively. This was observed in the absence of marked changes in attention, visuospatial, or executive functions. MRI was reviewed with our neuroradiologist, who confirmed that a small area of infarct involving the basal forebrain had been missed (figure, A and B). These anatomic structures had probably been damaged during her recent elective endovascular

embolization of the anterior communicating artery (ACoA) aneurysm (figure, C and D).

**DISCUSSION** The anterior communicating artery syndrome (ACAS) was first described by Alexander and Freedman<sup>1</sup> and DeLuca and Diamond<sup>2</sup> as a “Korsakoff-like syndrome” following ACoA rupture. It is characterized by a triad of symptoms including anterograde amnesia, confabulation, and personality changes. Despite its relatively small size, the ACoA has significant arterial branches that perfuse the septal nuclei, genu of corpus callosum, anterior cingulum, optic chiasm, columns of the fornix, substantia innominata, anterior hypothalamus, and mesial anterior commissure. Anterior fornices, septum pellucidum, and anterior portion of the cingulate gyrus are supplied by a small branch originating from 1 of 3 posterior arterioles of ACoA—the subcallosal artery.<sup>3</sup> Our patient presented a select infarct in the anterior fornices and anterior cingulum. It is postulated that compromise of the dorsal ACoA branches disconnects the fornix from the hippocampus and leads to inability to form new declarative memories.<sup>4</sup> This disruption also damages the mammillothalamic tract and is considered to be responsible for the neuropsychiatric disturbances (apathy, emotional lability, and disinhibited behavior) observed in ACAS.<sup>5</sup> Confabulations are another hallmark of ACAS for which medial frontal lesions involving anterior cingulum appear to be their neuroanatomic foundation. Two types of confabulations have been described: provoked (by direct questioning) and spontaneous (“fantastical”). Spontaneous confabulations correlate with severity of the amnesia and deficits in executive functions.<sup>6</sup> Unlike other amnesic syndromes, confabulations in ACAS never present alone but accompany anterograde memory deficits. Finally, damage to the anterior corpus callosum can further be used as a prognostic

**Figure** Selected images from our case



(A) Diffusion-weighted imaging and (B) apparent diffusion coefficient: combination of the 2 shows an acute ischemic stroke in the anterior fornices and the anterior cingulate gyrus. (C) T2 fluid-attenuated inversion recovery postembolization of anterior communicating artery aneurysm and (D) CT angiography show coiled saccular anterior communicating artery aneurysm.

marker because of the disruption of bilaterally integrated systems.

There are scarce data on outcome following ACAS. Neuropsychological deficits and functional sequelae appear in most cases to be persistent. Retrospective reports suggest that as many as 70% of affected individuals exhibit a significant long-term memory deficit and frontal-executive dysfunction.<sup>5,7</sup> Management of these patients until recently included active neuropsychological rehabilitation and close follow-up. An open-labeled small study conducted by Benke et al.<sup>7</sup> showed that cholinesterase inhibitors might be effective in the treatment of neuropsychological sequelae associated with ACAS. Indeed, significant increase in memory scores was reported in the group of patients assigned to donepezil 10 mg during 8 consecutive weeks. Our patient was also evaluated by occupational therapists, who started a “memory notebook training” program. On follow-up 3 months later, she showed limited improvement in cognition. The main concern voiced by her family was not the amnesic syndrome but rather her persisting personality changes, for which we have no precise intervention.

To our knowledge, there is no recent literature focused on ACAS after surgery for unruptured aneurysm. However, a number of studies reported the syndrome following aneurysmal rupture.<sup>8–10</sup> The clinical presentation of ACAS should be taken into consideration in the differential diagnosis of memory disorders following neurosurgical procedures that may initially present as a confusional state. Both pharmacologic and nonpharmacologic treatments are available but limited data exist to document their true impact on this devastating strategic infarct location.

#### AUTHOR CONTRIBUTIONS

Dr. Berezhnyakova contributed substantially to conception and design, acquisition of data, and analysis and interpretation of data, and drafted the article and revised it for important intellectual content. Dr. Milot contributed substantially to the acquisition of data and analysis and interpretation of data and revised the article for important intellectual content. Dr. Brisson contributed substantially to the analysis and interpretation of

data and revised the article for important intellectual content; Dr. Laforce contributed substantially to conception and design, acquisition of data, and analysis and interpretation of data and revised the paper for important intellectual content.

#### STUDY FUNDING

No targeted funding reported.

#### DISCLOSURE

The authors report no disclosures relevant to the manuscript. Go to [Neurology.org](http://Neurology.org) for full disclosures.

#### REFERENCES

1. Alexander M, Freedman M. Amnesia after anterior communicating artery aneurism rupture. *Neurology* 1984;34:752–757.
2. DeLuca J, Diamond BJ. Aneurysm of the anterior communicating artery: a review of neuroanatomical and neuropsychological sequelae. *J Clin Exp Neuropsychol* 1995;17:100–121.
3. Moussouttas M, Giacino J, Papamitsakis N. Amnesic syndrome of the subcallosal artery: a novel infarct syndrome. *Cerebrovasc Dis* 2005;19:410–414.
4. Thomas AG, Koumellis P, Dineen R. The fornix in health and disease: an imaging review. *Radiographics* 2011;31:1107–1121.
5. Gade A. Amnesia after operation on aneurysm of the anterior communicating artery. *Surg Neurol* 1982;18:46–49.
6. Fischer R, Alexander M, D’Esposito M, Randal O. Neuropsychological and neuroanatomical correlates of confabulation. *J Clin Exp Neuropsychol* 1995;17:20–28.
7. Benke T, Koylu B, Delazer M, et al. Cholinergic treatment of amnesia following basal forebrain lesion due to aneurysm rupture: an open-label pilot study. *Eur J Neurol* 2005;12:791–796.
8. Cronqvist M, Wirestam R, Ramgren B, et al. Diffusion and perfusion MRI in patients with ruptured and unruptured intracranial aneurysms treated by endovascular coiling. *Neuroradiology* 2005;47:855–873.
9. Gonzalez N, Sedrak M, Martin N, Vinuela F. Impact of anatomic features in the endovascular embolization of 181 anterior communicating artery aneurysms. *Stroke* 2008;39:2776–2782.
10. Proust F, Martinaud O, Gérardin E, et al. Quality of life and brain damage after microsurgical clip occlusion or endovascular coil embolization for ruptured anterior communicating artery aneurysms: neuropsychological assessment. *J Neurosurg* 2009;110:19–29.

# Neurology®

## Clinical Reasoning: A puzzling case of amnesia

Olena Berezhnyakova, Geneviève Milot, Mélanie Brisson, et al.

*Neurology* 2014;83:e73-e76

DOI 10.1212/WNL.0000000000000676

**This information is current as of August 4, 2014**

<b>Updated Information &amp; Services</b>	including high resolution figures, can be found at: <a href="http://www.neurology.org/content/83/6/e73.full.html">http://www.neurology.org/content/83/6/e73.full.html</a>
<b>Supplementary Material</b>	Supplementary material can be found at: <a href="http://www.neurology.org/content/suppl/2014/08/03/WNL.0000000000000676.DC1.html">http://www.neurology.org/content/suppl/2014/08/03/WNL.0000000000000676.DC1.html</a>
<b>References</b>	This article cites 10 articles, 2 of which you can access for free at: <a href="http://www.neurology.org/content/83/6/e73.full.html##ref-list-1">http://www.neurology.org/content/83/6/e73.full.html##ref-list-1</a>
<b>Subspecialty Collections</b>	This article, along with others on similar topics, appears in the following collection(s): <b>All Clinical Neurology</b> <a href="http://www.neurology.org/cgi/collection/all_clinical_neurology">http://www.neurology.org/cgi/collection/all_clinical_neurology</a> <b>Memory</b> <a href="http://www.neurology.org/cgi/collection/memory">http://www.neurology.org/cgi/collection/memory</a> <b>Other Education</b> <a href="http://www.neurology.org/cgi/collection/other_education">http://www.neurology.org/cgi/collection/other_education</a>
<b>Permissions &amp; Licensing</b>	Information about reproducing this article in parts (figures, tables) or in its entirety can be found online at: <a href="http://www.neurology.org/misc/about.xhtml#permissions">http://www.neurology.org/misc/about.xhtml#permissions</a>
<b>Reprints</b>	Information about ordering reprints can be found online: <a href="http://www.neurology.org/misc/addir.xhtml#reprintsus">http://www.neurology.org/misc/addir.xhtml#reprintsus</a>

*Neurology*® is the official journal of the American Academy of Neurology. Published continuously since 1951, it is now a weekly with 48 issues per year. Copyright © 2014 American Academy of Neurology. All rights reserved. Print ISSN: 0028-3878. Online ISSN: 1526-632X.

