

Monitoring epilepsy in the intensive care unit: Current state of facts and potential interest of high density EEG

Melanie Boly & Rama Maganti

Department of Neurology, University of Wisconsin, Madison, WI, USA

Abstract

Primary objective: To assess the current state of the art of epilepsy monitoring in intensive care unit (ICU).

Research design: Review article.

Methods and procedures: A review of current scientific literature, as well as an illustrative case report.

Main outcomes and results: Recent continuous electroencephalography (cEEG) monitoring studies revealed that non-convulsive seizures are very common in ICU. Conventional EEG is insufficient to detect them. However, very long recordings, of more than 24 hours, are needed to reach a good sensitivity. Even if cEEG improves monitoring of epileptic patients in the intensive care unit (ICU), studies using intracranial recordings show that conventional montage cEEG is, however, insufficient to detect all neurological deterioration in patients in the ICU. This review discusses the potential interest of dense array scalp EEG recordings to increase the sensitivity of detection of epileptic events in non-responsive patients in the ICU and to possibly help improve their prognosis, by allowing an earlier start of their treatment.

Conclusions: Studies using dense array scalp EEG could potentially improve the detection and management of seizures in non-responsive patients in the ICU. Studies comparing this technique to conventional cEEG recordings are warranted.

Keywords

Coma, neuroimaging, seizure

History

Received 26 August 2013

Revised 21 December 2013

Accepted 25 January 2014

Published online 25 July 2014

Introduction

Due to technological advances, it is now feasible to record continuous digital EEG (cEEG), i.e. an EEG recorded with or without video for more than 24 hours, instead of the conventional half an hour in critically ill patients, and to review these recordings remotely. Recent studies using this technique showed that a 'routine' EEG will miss half to two-thirds of patients that will go on to have non-convulsive seizures (NCSz, i.e. seizures evidenced on the EEG without convulsive symptoms detectable at the bedside) in intensive care unit (ICU) settings [1]. The current evidence for this matter of fact is reviewed here then the potential interest of the use of high density EEG (HDEEG, 64–256 electrodes) instead of conventional montages is discussed for continuous recording settings, to allow an earlier and more sensitive detection of seizure activity in these patients.

Prevalence of epilepsy in ICU non responsive patients: A review of recent literature

In surveys using cEEG in neuro-ICU [2–4], the incidence of NCSz was estimated between 18–37%. In addition, the

incidence of non-convulsive status epilepticus (NCSE, a state of continuous seizure activity without overt clinical signs or with recurrent non-convulsive seizures occurring ever few minutes) was estimated to be between 10–18% [1, 4]. Following aneurysmal subarachnoid haemorrhage (SAH), 11 out of 300 patients (3%) had NCSE on cEEG, 51 of 68 patients (75%) had epileptiform abnormalities (electrical activity suggestive of an underlying seizing disorder) on cEEG; 40% had periodic discharges on EEG (spikes and/or sharp slow waves occurring with an almost regular rate, typically 0.5–2 Hz, in the EEG; strongly suggestive of underlying active epilepsy) at some point during the course of the monitoring [5].

Why is this important? NCSz/NCSE increase mortality and morbidity. Seizures after traumatic brain injury indeed increase length of stay and are associated with higher mortality [6]. In cases of convulsive status epilepticus, mortality rates at 30 days are between 19–27% [7] and severe neurological sequelae happen in 11–16% of patients [8]. In the case of NCSE, at 30 days mortality rates are ~60% [9]. Mortality rates, however, vary markedly depending on diagnosis delay: 36% if NCSE diagnosed in 30 minutes; and 75% if diagnosis takes 24 hours or longer [10]. Seizures after SAH are also an independent risk factor for poor outcome [5]. NCSE is also an independent risk factor for increased midline shift after intra-parenchymal haemorrhage

Correspondence: Melanie Boly, Department of Neurology, UW Hospital and Clinics, 1685 Highland Avenue, Madison, WI 53705, USA. Tel: +6082635448. E-mail: boly@wisc.edu

[11] and are associated with prolonged increase in intracranial pressure [12]. Even in a medical ICU, strictly electrographic non-convulsive seizures (only seen on the EEG without overt clinical signs) can be associated with unfavourable outcome [13]. Thus, the above-mentioned studies highlight the importance of recognizing and treating NCSz among critically ill patients.

Epileptic seizures have also been reported to be present in 24% of chronic non-communicative brain damaged patients, such as in the vegetative and minimally conscious state [14]. Prevalence of chronic epileptic seizures was 3-times greater in patients in a unresponsive wakefulness/vegetative state (UWS/Vs) than in patients in a minimally conscious state (MCS) [14]. A recent study by the same group reported a negative result for improvement in outcome after anti-epileptic drugs administration in chronic VS/UWS and MCS (studied >50 days after insult) [15]. However, this study was performed in chronic patient populations and more data are desirable in acute settings for such patients.

Continuous EEG monitoring allows the early recognition of NCSz and their rapid treatment. Table I describes common indications for continuous EEG in ICU settings. The Mayo Study [1] compared cEEG to conventional EEG in ICU settings and revealed that routine EEGs could find electrographic seizures in 11% of patients, as opposed to cEEG which found seizures in 27%. Even clinical seizures were found more often with cEEG in patients in the ICU compared to routine bedside EEG (40% vs 20%). Most NCSz will be detected in the first 24 hours of cEEG in non-comatose patients, but longer recording periods may be required in comatose patients or in those with periodic epileptiform discharges. In addition to detecting seizures, monitoring alpha variability or alpha/delta ratio has also been shown to be useful for the real-time detection of ischaemia at a reversible stage and spreading depression associated to vasospasm [16, 17]. Finally, other trending paradigms used in cEEG, especially in an ICU setting, include spectral analysis, trending of inter-burst interval among those in burst-suppression and frequency trending [18].

Even if this technique increases the sensitivity of traditional EEG recordings, a standard 10–20 montage (19 electrodes) cEEG is not sufficient to detect all neurological deterioration events among patients in the ICU. A recent study using intracranial recordings [19] showed that, among 14 patients in the ICU with unexplained deterioration of consciousness, 10 patients had seizures in the intracranial recordings; six of which never had scalp EEG correlates, two showed non-ictal appearing rhythmic delta on the scalp and two showed scalp EEG correlates on occasion only. This study also revealed that standard scalp cEEG is insufficient to detect EEG slowing due to vasospasm in every case, as compared to intracranial recordings. As cEEG is, thus, not yet a gold standard and intracranial recordings are not widely feasible in patients in the ICU, additional non-invasive measurements of brain electrical activity are desirable.

Potential interest of high density EEG (HDEEG) for early seizure detection in ICU settings

Recent years have witnessed the appearance of new neuroimaging, now potentially applicable for routine use in

ICU and non-ICU epileptic patients. One of these techniques, HDEEG, is ideally suited to be applied to epileptic patient population, because of its high portability and potentially widely applicable clinical use. HDEEG is defined by an EEG system of 64–256 electrodes (see Figure 1), usually arranged in a pre-formatted net to be more easily adapted to the head of the patient. An increased number of electrodes allow more sensitivity in the detection of abnormalities in EEG readings and their better localization on the scalp. Because of the increased number of electrodes, some spatial reconstruction can also be used, to infer from where in the brain originate the pathological findings on the scalp.

Clinical monitoring studies using HDEEG have the potential to detect epileptic events and, more generally, focal deleterious changes in brain activity earlier than the conventional cEEG recordings currently used in non-responsive patients in the ICU. HDEEG has indeed previously been shown to help in the non-invasive localization of epileptic seizures in non-ICU patients and to be ideally designed to localize focal changes in brain activity in the human brain [20, 21]. Studies comparing HDEEG to intracranial recordings [22] showed that 256 electrodes recordings using HDEEG increased by 2–3 times the rate of detection of epileptic spikes on the scalp. In another study on temporal lobe epilepsy, 90% of spikes detected by HDEEG could not be found in standard 10–20 EEG montages [21] (Figure 2). HDEEG was proposed as an alternative to intracranial electrodes to improve the sensitivity of electrographic activity detection [21].

HDEEG also allows analysing scalp spikes or ictal events using source modelling in order to provide potentially useful localizing information about the cortical localization of seizure origins in individual patients [23]. Studies using more electrodes and realistic head models were shown to give better results for this purpose [24]. Dipole models are typically used in the context of epilepsy source localization,

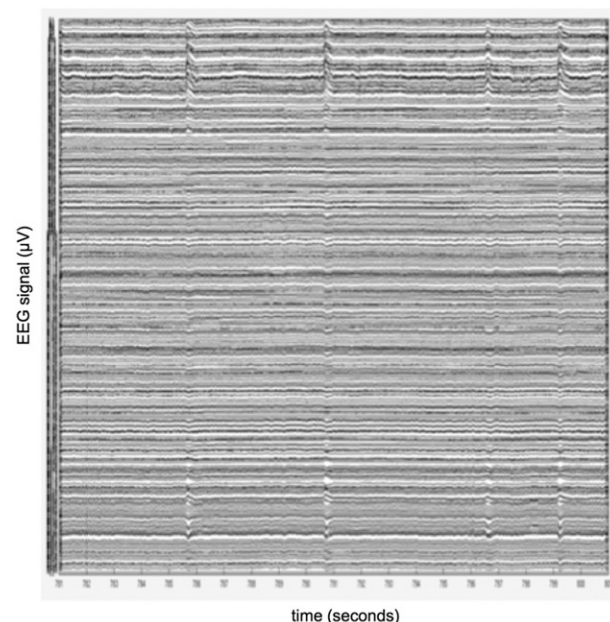


Figure 1. Twenty-seconds epoch of eyes-open 256 electrodes HDEEG recorded at the University of Wisconsin. Each line represents the EEG signal in one electrode.

but distributed source modelling algorithms are also useful methods. This review will illustrate this matter of fact with an exemplar patient. This patient (previously described in Landsness et al. [25], patient VS5) was clinically diagnosed in UWS/Vs after a severe and prolonged hypoglycaemic episode. She was studied in a collaborative effort between the University of Liege and the University of Wisconsin, Madison. The EEG of this patient was characterized by continuous delta waves, interleaved with epileptic spikes every few seconds (Figure 3(A)). While the structural MRI of this patient was normal, a fluoro-deoxyglucose positron emission tomography (PET) scan showed bilateral frontoparietal hypometabolism (Figure 3(B)). This pattern is commonly found in UWS/Vs patients [26]. The PET scan of this patient was, however, atypical by the preservation of metabolism in bilateral temporo-frontal regions (Figure 3(C)). In

order to better understand the patient's condition, the aim was to identify the cortical generators of the patient's ongoing spiking activity using HDEEG. This review acquired 12-hour recordings using a 256 electrodes HDEEG system (Electrical Geodesics, Eugene, OR) sampled at 500 Hz and selected 44 representative spikes among the ongoing epileptic activity present on the patient's spontaneous EEG. Source reconstruction of average spiking activity was then computed using a boundary element method [27], a canonical cortical mesh [28] and a minimum norm and smoothness distributed inverse solution using Statistical Parametric Mapping software. Cortical areas generating the maximum electrical activity during the spikes are displayed in Figure 3(D), and were concordant with the areas of preserved metabolism in PET scan, validating source reconstruction.

Another promising application of HDEEG is a fine grained analysis of epileptic networks dynamics, which can be extracted from the patient's scalp recordings. This can be done by means of various complementary techniques, two leading ones for this purpose are Granger causality (GC) and Dynamic Causal Modelling [29]. GC measures how the past signal of a region improves the prediction of the present signal of another region. The state-space GC model developed by the UW Madison team [30] combines in one single step EEG source reconstruction and cortical GC connectivity estimation, rather than performing them in series. This method has been shown to lead to more accurate results for seizure focus detection as compared to standard two-stage GC estimation technique [31] (Figure 4). Dynamic Causal Modelling is based on different assumptions; it uses a non-linear generative neural model [32] to infer directionality of connectivity between cortical areas. Both methods have been used in the neuroimaging literature to estimate cortical activity directionality in healthy volunteers and in a patient population.

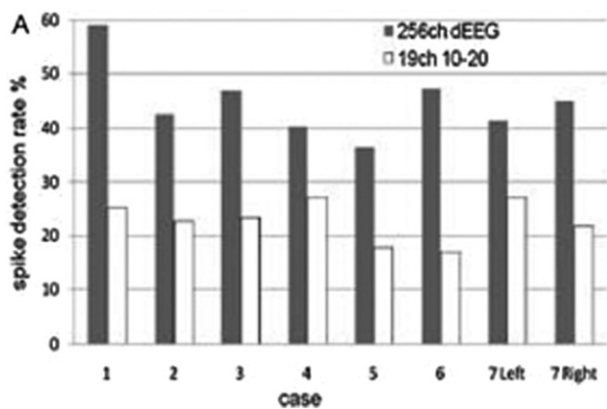


Figure 2. HDEEG recordings (in grey) have been shown to detect twice more spikes than conventional scalp EEG recordings (in white) in non-ICU epileptic patients. ch, channels; dEEG; dense array EEG. Adapted from Yamazaki et al. [22].

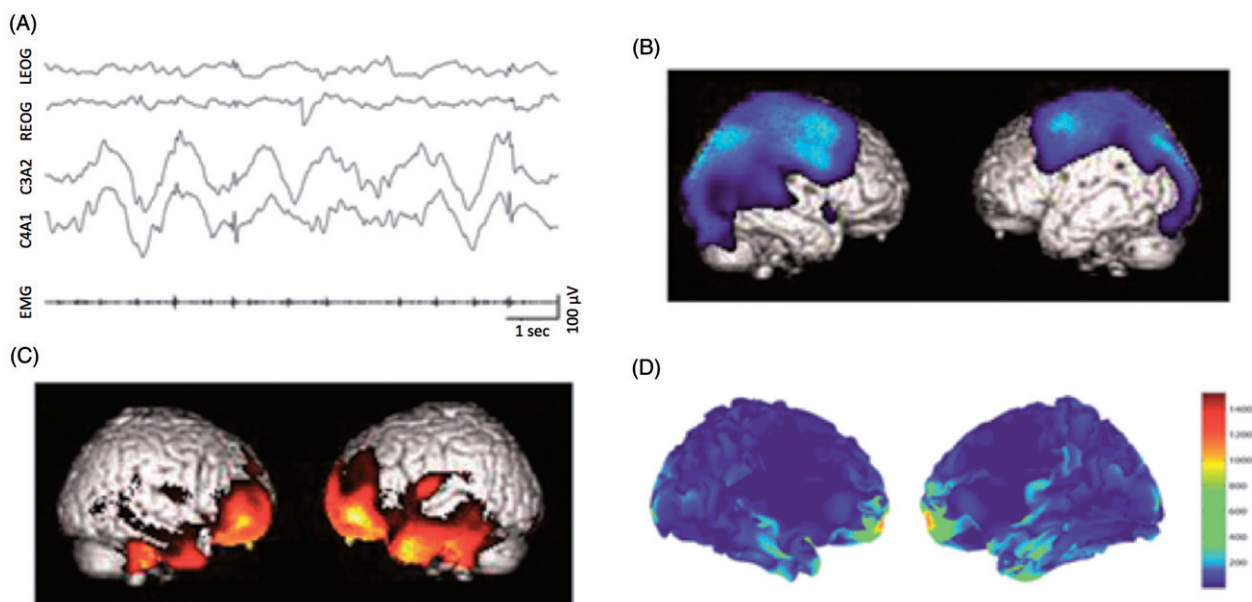


Figure 3. (A) Sample of the patient EEG, showing continuous slow delta waves superimposed with epileptic spikes. (B) The same patient's FDG PET scan, showing bilateral frontoparietal hypometabolism typical of VS. (C) Areas of atypically preserved metabolism in the same VS patient's FDG PET scan. (D) Results of epileptic spike source localization in this patient, showing presumed areas of epileptic of similar topography as compared to the PET scan metabolic preservation.

Figure 4. Granger causality estimation for seizure focus detection, computed over three seizure datasets in a temporal lobe epilepsy patient [31]. (A) Results of the state-based Granger Causality approach, showing the highest causality for temporal channels over parietal channels and consistent with the clinical diagnosis and with the clinical readings of the same recordings. (B) Results from classical two-stage Granger Causality analysis (source reconstruction, then connectivity estimation), led to inaccurate epileptic focus localization, inconsistent with clinical findings. Error bars denote the standard error of the mean. ch, channel; cGC, conditional Granger Causality.

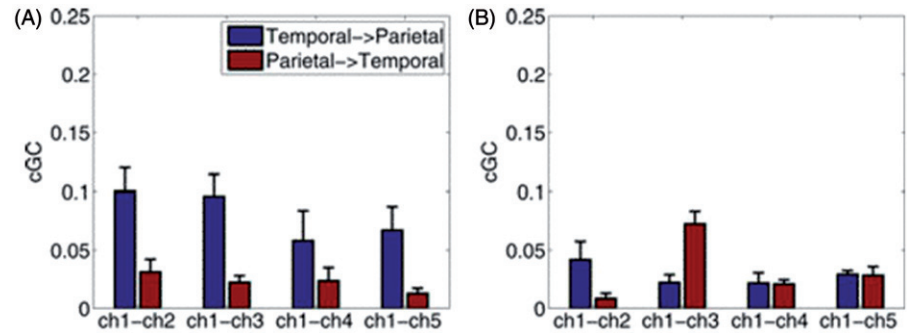


Table I. Indications of continuous EEG monitoring.

NeuroICU	Non-NeuroICU
<ul style="list-style-type: none"> Following TBI in the setting of increased ICP and SAH After aneurysmal SAH as a routine for 72 hours for seizures/NCSE After SAH for delayed vasospasm Any neuro ICU patient with unexplained mental status changes Post-neurosurgical patient who remains encephalopathic 	<ul style="list-style-type: none"> Any patient with unexplained mental status changes, especially those with renal failure Following cardiac arrest during hypothermia/anoxic myoclonus Abnormal movements in an encephalopathic patient During ECMO in paediatric ICUs

ICU, intensive care unit; TBI, traumatic brain injury; ICP, intracranial pressure; SAH, subarachnoid haemorrhage; NCSE, non-convulsive status epilepticus; ECMO, extracorporeal membrane oxygenation.

Note that these two directional connectivity estimation techniques could also be applied to intracranial recordings. Their clinical validation for seizure focus detection in patients in ICU and in epilepsy monitoring unit, using both scalp level and intracranial EEG recordings, is warranted.

Conclusion

Future studies should compare HDEEG to intracranial recordings and conventional cEEG monitoring for early non-convulsive seizures detection in patients in ICU. In parallel, other validation studies should continue to compare HDEEG to conventional EEG and intracranial recordings in the epilepsy monitoring unit for localizing interictal spikes and seizure onset zones. Progress in this field will likely benefit from co-ordinated research efforts using similar seizure detection techniques applied to both ICU and epilepsy monitoring unit patients.

Acknowledgements

Melanie Boly is an Honorary Postdoctoral Research Fellow at the University of Wisconsin-Madison Psychiatry Department.

Declaration of interest

The authors report no conflicts of interest. The authors alone are responsible for the content and writing of the paper.

References

- Pandian JD, Cascino GD, So EL, Manno E, Fulgham JR. Digital video-electroencephalographic monitoring in the neurological-neurosurgical intensive care unit: Clinical features and outcome. *Archives of Neurology* 2004;61:1090–1094.
- Jordan KG. Continuous EEG monitoring in the neuroscience intensive care unit and emergency department. *Journal of Clinical Neurophysiology* 1999;16:14–39.
- Privitera MD, Strawsburg RH. Electroencephalographic monitoring in the emergency department. *Emergency Medicine Clinics of North America* 1994;12:1089–1100.
- Claassen J, Mayer SA, Hirsch LJ. Continuous EEG monitoring in patients with subarachnoid hemorrhage. *Journal of Clinical Neurophysiology* 2005;22:92–98.
- Little AS, Kerrigan JF, McDougall CG, Zabramski JM, Albuquerque FC, Nakaji P, Spetzler RF. Nonconvulsive status epilepticus in patients suffering spontaneous subarachnoid hemorrhage. *Journal of Neurosurgery* 2007;106:805–811.
- Vespa PM, Nenov V, Nuwer MR. Continuous EEG monitoring in the intensive care unit: Early findings and clinical efficacy. *Journal of Clinical Neurophysiology* 1999;16:1–13.
- Legriel S, Mourvillier B, Bele N, Amaro J, Fouet P, Manet P, Hilpert F. Outcomes in 140 critically ill patients with status epilepticus. *Intensive Care Medicine* 2008;34:476–480.
- Riviello Jr JJ, Holmes GL. The treatment of status epilepticus. *Seminars in Pediatric Neurology* 2004;11:129–138.
- Treiman DM, Meyers PD, Walton NY, Collins JF, Colling C, Rowan AJ, Handforth A, Faught E, Calabrese VP, Uthman BM, et al. A comparison of four treatments for generalized convulsive status epilepticus. *Veterans Affairs Status Epilepticus Cooperative Study Group*. *New England Journal of Medicine* 1998;339:792–798.
- Young GB, Jordan KG, Doig GS. An assessment of nonconvulsive seizures in the intensive care unit using continuous EEG monitoring: An investigation of variables associated with mortality. *Neurology* 1996;47:83–89.
- Vespa PM, O'Phelan K, Shah M, Mirabelli J, Starkman S, Kidwell C, Saver J, Nuwer MR, Frazee JG, McArthur DA, et al. Acute seizures after intracerebral hemorrhage: A factor in progressive midline shift and outcome. *Neurology* 2003;60:1441–1446.
- Vespa PM, Miller C, McArthur D, Eliseo M, Etchepare M, Hirt D, Glenn TC, Martin N, Hovda D. Nonconvulsive electrographic seizures after traumatic brain injury result in a delayed, prolonged increase in intracranial pressure and metabolic crisis. *Critical Care Medicine* 2007;35:2830–2836.
- Kamel H, Betjemann JP, Navi BB, Hegde M, Meisel K, Douglas VC, Josephson SA. Diagnostic yield of electroencephalography in the medical and surgical intensive care unit. *Neurocrit Care* 2013;19:336–41.
- Bagnato S, Boccagni C, Galardi G. Structural epilepsy occurrence in vegetative and minimally conscious states. *Epilepsy Research* 2013;103:106–109.
- Bagnato S, Boccagni C, Sant'angelo A, Galardi G. A range of antiepileptic drugs do not affect the recovery of consciousness in vegetative and minimally conscious states. *Epilepsy & Behavior* 2013;27:365–370.

16. Claassen J, Hirsch LJ, Kreiter KT, Du EY, Connolly ES, Emerson RG, Mayer SA. Quantitative continuous EEG for detecting delayed cerebral ischemia in patients with poor-grade subarachnoid hemorrhage. *Clinical Neurophysiology* 2004;115:2699–2710.
17. Friedman D, Claassen J, Hirsch LJ. Continuous electroencephalogram monitoring in the intensive care unit. *Anesthesia & Analgesia* 2009;109:506–523.
18. Claassen J. How I treat patients with EEG patterns on the ictal-interictal continuum in the neuro ICU. *Neurocritical Care* 2009;11:437–444.
19. Waziri A, Claassen J, Stuart RM, Arif H, Schmidt JM, Mayer SA, Badjatia N, Kull LL, Connolly ES, Emerson RG, et al. Intracortical electroencephalography in acute brain injury. *Annals of Neurology* 2009;66:366–377.
20. Holmes MD, Tucker DM, Quiring JM, Hakimian S, Miller JW, Ojemann JG. Comparing noninvasive dense array and intracranial electroencephalography for localization of seizures. *Neurosurgery* 2010;66:354–362.
21. Yamazaki M, Terrill M, Fujimoto A, Yamamoto T, Tucker DM. Integrating dense array EEG in the presurgical evaluation of temporal lobe epilepsy. *ISRN Neurology* 2012;2012:924081.
22. Yamazaki M, Tucker DM, Fujimoto A, Yamazoe T, Okanishi T, Yokota T, Enoki H, Yamamoto T. Comparison of dense array EEG with simultaneous intracranial EEG for interictal spike detection and localization. *Epilepsy Research* 2012;98:166–173.
23. Ray A, Tao JX, Hawes-Ebersole SM, Ebersole JS. Localizing value of scalp EEG spikes: A simultaneous scalp and intracranial study. *Clinical Neurophysiology* 2007;118:69–79.
24. Wang G, Worrell G, Yang L, Wilke C, He B. Interictal spike analysis of high-density EEG in patients with partial epilepsy. *Clinical Neurophysiology* 2011;122:1098–1105.
25. Landsness E, Bruno MA, Noirhomme Q, Riedner B, Gosseries O, Schnakers C, Massimini M, Laureys S, Tononi G, Boly M. Electrophysiological correlates of behavioural changes in vigilance in vegetative state and minimally conscious state. *Brain* 2011;134:2222–2232.
26. Laureys S. The neural correlate of (un)awareness: Lessons from the vegetative state. *Trends in Cognitive Sciences* 2005;9:556–559.
27. Fuchs M, Wagner M, Kastner J. Boundary element method volume conductor models for EEG source reconstruction. *Clinical Neurophysiology* 2001;112:1400–1407.
28. Daunizeau J, Vaudano AE, Lemieux L. Bayesian multi-modal model comparison: A case study on the generators of the spike and the wave in generalized spike-wave complexes. *Neuroimage* 2010;49:656–667.
29. Friston K, Moran R, Seth AK. Analysing connectivity with Granger causality and dynamic causal modelling. *Current Opinion in Neurobiology* 2013;23:172–178.
30. Cheung BL, Riedner BA, Tononi G, Van Veen BD. Estimation of cortical connectivity from EEG using state-space models. *IEEE Transactions in Biomedical Engineering* 2010;57:2122–2134.
31. Cheung BL, Nowak R, Lee HC, van Drongelen W, Van Veen BD. Cross validation for selection of cortical interaction models from scalp EEG or MEG. *IEEE Transactions in Biomedical Engineering* 2012;59:504–514.
32. Friston KJ, Harrison L, Penny W. Dynamic causal modelling. *Neuroimage* 2003;19:1273–302.