

Review

A review of cavernous malformations with trigeminal neuralgia[☆]Kazuhide Adachi^{*}, Mitsuhiro Hasegawa, Takuro Hayashi, Shinya Nagahisa, Yuichi Hirose

Department of Neurosurgery, School of Medicine, Fujita Health University, 1-98, Kutsugake Dengakugakubo, Toyoake City, Aichi 470-1192, Japan

ARTICLE INFO

Article history:

Received 15 April 2014

Received in revised form 16 July 2014

Accepted 20 July 2014

Available online 30 July 2014

Keywords:

Trigeminal neuralgia

Cavernous malformation

Anterior transpetrosal approach

Pons

Operative approach

ABSTRACT

Cavernous malformation with trigeminal neuralgia is relatively rare; only 10 cases have been reported. In deciding treatment strategies, it is helpful to classify cavernous malformation according to its origin, as follows: in the Gasserian ganglion (Type G); between the cisternal and intra-axial portions of the trigeminal nerve root (Type C); in the intra-axial trigeminal nerve root in the pons (Type P); or in the spinal tract of the trigeminal nerve root (Type S). A 62-year-old male presented with left trigeminal neuralgia (V2 area) and left facial hypoesthesia. Imaging studies revealed a cerebellopontine angle mass lesion with characteristics of a cavernous malformation and evidence of hemorrhage. The lesion was completely removed via a left anterior transpetrosal approach. The mass was attached to the trigeminal nerve root; it was located between the cisternal and intra-axial portions of the nerve root, and feeding off microvessels from the trigeminal nerve vascular plexus. Histological examination confirmed a cavernous malformation. In this case, the cavernous malformation was Type C. We review cases of cavernous malformation with trigeminal neuralgia and discuss therapeutic strategies according to the area of origin.

© 2014 Elsevier B.V. All rights reserved.

Contents

1. Introduction	151
2. Case report	151
3. Discussion	152
4. Conclusion	154
References	154

1. Introduction

Idiopathic trigeminal neuralgia is mainly caused by microvascular compression. The causes of symptomatic trigeminal neuralgia include herpes zoster and tumor compression or involvement. Neoplastic trigeminal neuralgia is generally caused by a schwannoma, meningioma, or epidermoid. In addition, rare cases of trigeminal neuralgia due to cavernous malformation (CM) have been reported.

CM of the central nervous system, also called cavernous angioma or cavernoma, is found in approximately 0.4–0.9% of the population [1,2]. CM may be intra-axial, occurring in areas such as the brain stem, cerebellum, and cerebral hemisphere [3], or extra-axial.

Extra-axial CMs are believed to arise from the capillary plexus related to the dura mater [4–6], and are generally associated with the floor of the middle cranial fossa, especially in the cavernous sinus [2–4,6]. CMs have been reported to involve cranial nerves such as the optic nerves and chiasm, the third nerve, the seventh nerve in the temporal bone, the vestibular nerve [7], and the seventh–eighth nerve complex in the internal auditory canal [1,8]. The presenting symptoms are related to the nerve involved in the lesion.

2. Case report

A 62-year-old male patient was referred to our department with a three-month history of left facial pain triggered by facial compression. He had consulted a neighborhood hospital, where magnetic resonance imaging (MRI) revealed a mass lesion of the left cerebellopontine angle (CPA). Follow-up MRIs at our hospital showed that the lesion was attached to the trigeminal nerves. The lesion

[☆] This study was not supported by grants or other funding sources, and none of the authors has industry affiliations related to the materials or procedures used in this study.

^{*} Corresponding author. Tel.: +81 562 93 2111; fax: +81 3 3354 8053.
E-mail address: kazu-adachi@rio.odn.ne.jp (K. Adachi).

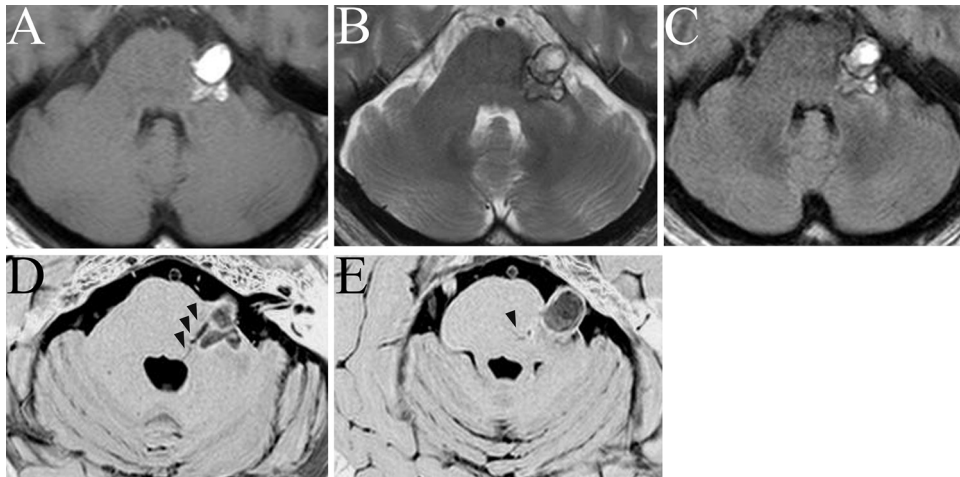


Fig. 1. MRI findings showing a left cerebellopontine angle mass 3 cm in diameter in contact with the trigeminal nerve. Highintense axial T1-weighted images (A) and isointense to highintense T2-weighted (B) and FLAIR-weighted (C) MRIs show a left trigeminal mass with hemosiderin rims. Axial CISS-weighted findings (D, E) show a low-intense mass with a hemosiderin rim and DVA (arrowheads).

appeared hyperintense on T1-weighted MRI; heterogeneous, high-intense, and isointense with a hemosiderin rim on T2-weighted MRI; and as a mass with a hemosiderin rim and a developmental venous anomaly (DVA) medially on CISS-weighted MRI (Fig. 1A–E). Based on these findings, the patient was diagnosed with a CM of the left trigeminal nerve, and was admitted for surgical treatment because of hemorrhage-related symptoms.

Neurological examination revealed left facial hypoesthesia. The patient had no particular previous medical history, and laboratory findings were normal. The operation was performed using a left anterior transpetrosal approach. The mass was blue-gray in color and was buried in the drawn-out area shown in Fig. 2A, between the cisternal and intra-axial portions of the trigeminal nerve. Hemosiderin depositions and xanthosis were observed in the trigeminal nerve around the CM. The tumor was resected en bloc, and feeder microvessels were treated. The DVA was allowed to remain. Hemosiderin had caused degeneration in the trigeminal nerve, although it was preserved morphologically (Fig. 2B). Microscopically, granulation tissue with hemosiderosis was observed. There was no intervening neural or glial tissue (Fig. 3). These findings were compatible with a diagnosis of CM.

After the surgery, left facial numbness remained without trigeminal neuralgia. Postoperative MRI revealed no residual CM (Fig. 4). The postoperative course was uneventful, and the patient was discharged.

3. Discussion

CM of the trigeminal nerve with trigeminal neuralgia was first described in 1988 by Fehlings et al. [9]. Since then, 11 well-documented cases of histologically confirmed CM with trigeminal neuralgia have been reported in English, including the present case (Table 1) [9–18].

We classified these cases into four types according to the origin of the CM: Type G, which originates in the Gasserian ganglion (3 cases); Type C, which originates between the cisternal and intra-axial portions of the trigeminal nerve root (2 cases, including ours); Type P, originating in the intra-axial trigeminal nerve root in the pons (4 cases); and Type S, which originates in the spinal tract of the trigeminal nerve root below the medulla oblongata (2 cases) (Fig. 5). When discussing CM and its treatment, it is important to consider these distinct areas of origin. Type G develops from the vascular plexus of the dura or cranial nerve; Type C develops from

the vascular plexus of the cranial nerve; and Types P and S develop from the vascular plexus of the cerebral parenchyma.

CM was treated surgically in 8 of the 11 reported cases. Postoperatively, facial numbness remained but trigeminal neuralgia was relieved in 7 of the 8 cases [9–12,16,17]. The patient complains of dysesthesia in the left occipital area and sensory disturbance of the

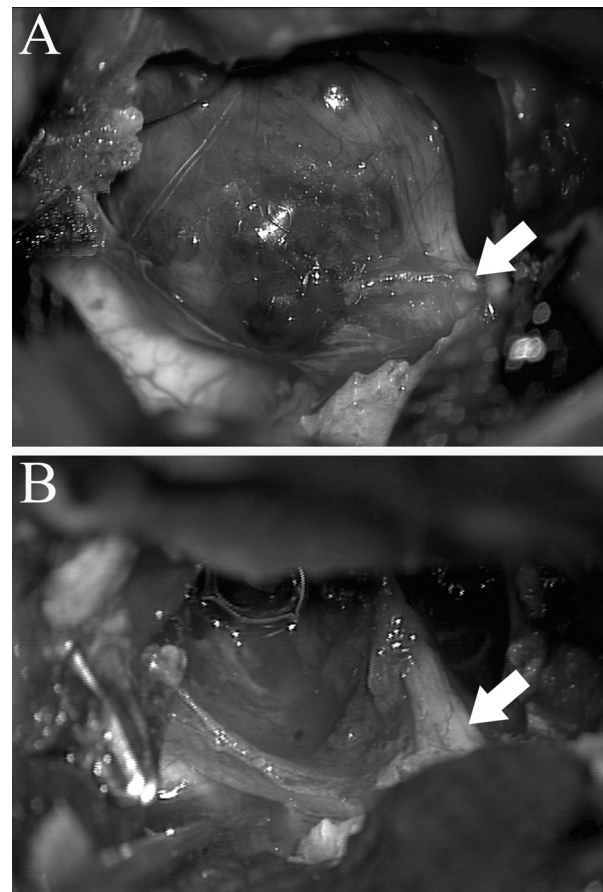


Fig. 2. Intraoperative photography. (A) The mass was blue-gray in color with microvessels, and was buried in the trigeminal nerve, which is drawn out in the photographs (white arrow); hemosiderin deposition and xanthosis were present. (B) The tumor was completely removed from beneath the trigeminal nerve (white arrow), which was preserved morphologically.

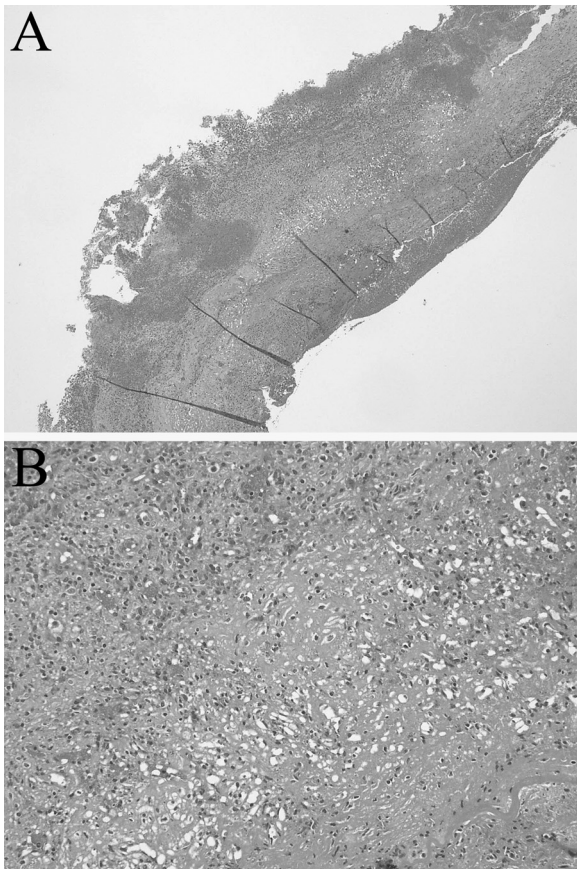


Fig. 3. Photomicrographs showing clustered dilated empty vascular channels with a single layer of endothelium, no muscular tissue in the walls, and no intervening neural or glial tissue, with thrombi in some channels (H&E). Original magnification: 4× (A), 40× (B).

right side of the body in surgically treated Type S CM [17]. In one case involving a Type P CM [13], the patient died from postoperative bleeding.

In the remaining 3 cases that were not treated surgically, one patient with a Type S CM [18] experienced spontaneous remission of symptoms, and two patients with Type P CM [14,15] were able to control the pain with medication. All the non-operated CMs were tiny lesions that were entirely intra-axial.

Surgical resection should be considered for symptomatic brainstem CMs that abut a pial surface or are surrounded by a thin rim of brainstem tissue. Indeed, the natural history is worse for CM in the brainstem than for CM in other CNS locations. Brainstem CM has

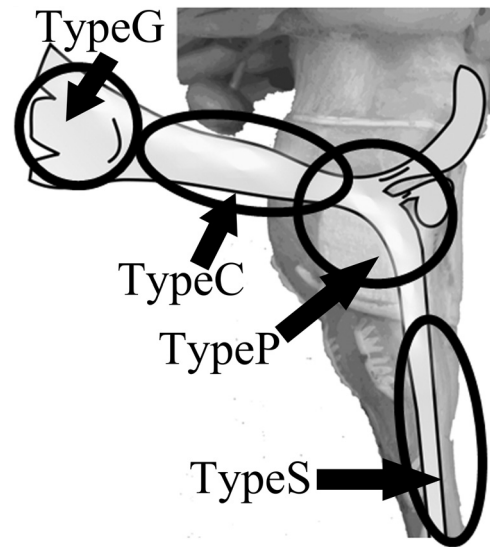


Fig. 5. Schematic drawing of the trigeminal nerve root, lateral view. We classified trigeminal root cavernous malformations into 4 types according to the location of origin: Type G: Gasserian ganglion; Type C: between the cisternal portion and intra-axial trigeminal nerve root; Type P: the intra-axial trigeminal nerve root in the pons; Type S: the origin of the spinal tract of the trigeminal nerve root below the medulla oblongata.

a higher hemorrhage rate, and is more likely to hemorrhage again than CMs located elsewhere [19]. Some authors have reported that radiation-related complications (19–41%) [20,21] and hemorrhage (12–40%) [22,23] occur frequently with stereotactic radiosurgery for CM. Based on this information, resection should be the primary management strategy for CM whenever it can be accomplished with an acceptable risk of morbidity.

The surgical approach for CM with trigeminal neuralgia should consider the type of CM. A suboccipital approach has been used for Type S CM [17], which is appropriate for the tumor location. Type G CM has been treated using a subtemporal [9], front-temporal [10], or pterional approach [11]. The Type C CM in our present case was resected using an anterior transpetrosal approach, although another reported Type C case [12] was treated using a lateral suboccipital approach. Type P CMs have been treated with a lateral suboccipital [16] or subtemporal approach [13]. In one case of a Type P CM treated using a subtemporal approach, the patient died of postoperative bleeding [13], which can be caused by incomplete excision. An anterior transpetrosal approach was suitable for dissecting the tumor in that case. A Type P CM is located below the tentorium, making dissection from a subtemporal approach difficult. Cenzato et al. [16] reported that incomplete excision is

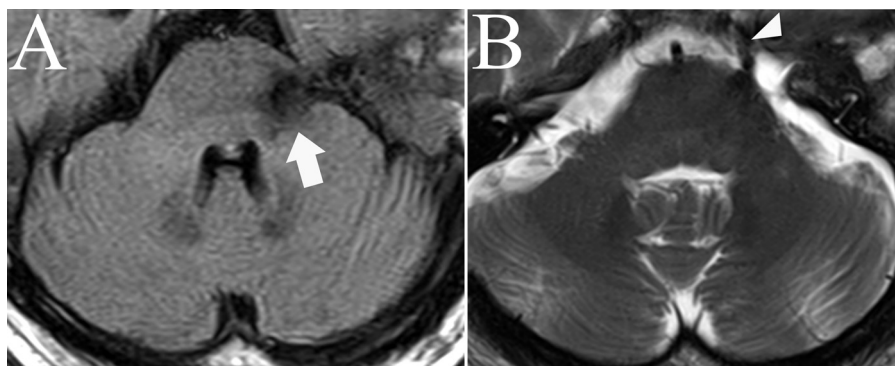


Fig. 4. Axial postoperative FLAIR-weighted (A) and T2-weighted MRI (B) scan verifying complete resection of the cavernous malformation (white arrow) and continuity of the trigeminal nerve (arrowheads).

Table 1
Reported cases of CM with trigeminal neuralgia.

Type	Year	Author	Other symptoms	Final treatment	Pain controlled
Type G	1988	Fehlings et al.	Hypoesthesia, V3 weakness	Surgery (subtemporal approach)	Good
Type C	2006	Mascarenhas et al.	–	Surgery (front-temporal approach)	Good
	2009	Seckin et al.	V3 anesthesia	Surgery (pterional approach)	Good
	2005	Deshmukh et al.	Hearing loss, anesthesia	Surgery (lateral suboccipital approach)	Good
Type P	2013	Our case	Hypoesthesia	Surgery (anterior transpetrosal approach)	Good
	1996	De Benedittis	SUNCT	Surgery (subtemporal approach)	Death
	2000	Shimpo	Anisocoria	Carbamazepin	Good
	2002	Vitek and Tettenborn	–	Gabapentin	Good
Type S	2010	Cenzato et al.	–	Surgery (lateral suboccipital approach)	Good
	1989	Saito et al.	Hyperpathia (lt C2 area), lt hypoesthesia (C2–7 dermatome)	Surgery (lateral suboccipital approach)	Good
	2007	Stellmann et al.	Ptosis, hypaesthesia	Spontaneously disappeared	Good

SUNCT: short-lasting, unilateral neuralgiform headache attacks with conjunctive injection and tearing.

probably more dangerous than abstention, since the risk of new hemorrhage from the fragments left by incomplete surgical excision can be as high as 43%. Complete surgical excision, conducted while facing the field of operation, may be especially important for brainstem CM.

One Type C CM was approached suboccipitally, and the petrosal vein was sacrificed to secure the operating field [12]. Sacrificing the petrosal vein could cause venous congestion and brain swelling, which would make dissection more difficult when using a lateral suboccipital approach.

For Type C or P CMs, we believe an anterior transpetrosal approach is better than a lateral suboccipital or subtemporal approach, because it provides good exposure, and the surgeon can face the pontine surface and trigeminal nerve root, although the working axis of the lateral suboccipital approach, which is essentially sagittal, uses the windows created by the petrous bone, petrosal vein and cerebellum [24,25].

4. Conclusion

CM with trigeminal neuralgia is rare. Resection should be the primary management strategy whenever it can be accomplished with an acceptable risk of morbidity, although pain has been controllable with medication in some cases, and a spontaneous remission of symptoms was reported in one case. Surgery for CM should be performed facing the field of operation, since incomplete excision may be more dangerous than abstention due to the risk of new hemorrhage from any fragments. With the exception of Type G and Type S CMs, an anterior transpetrosal approach is usually suitable for dissecting a CM causing trigeminal neuralgia, since this approach faces the lesion in the center of trigeminal nerve.

References

- [1] Beskonakli E, Kaptanoglu E, Okutan O, Solaroglu I, Taskin Y. Extra-axial cavernomas of the cerebellopontine angle involving the seventh–eighth nerve complex. *Neurosurg Rev* 2002;25:222–4.
- [2] Kim M, Rowed DW, Cheung G, Ang LC. Cavernous malformation presenting as an extra-axial cerebellopontine angle mass: case report. *Neurosurgery* 1997;40:187–90.
- [3] Barrera JE, Jenkins H, Said S. Cavernous hemangioma of the internal auditory canal: a case report and review of the literature. *Am J Otolaryngol* 2004;25:199–203.
- [4] Brunori A, Chiappetta F. Cystic extra-axial cavernoma of the cerebellopontine angle. *Surg Neurol* 1996;46:475–6.
- [5] Iplikcioglu AC, Benli K, Bertan V, Ruacan S. Cystic cavernous hemangioma of the cerebellopontine angle: case report. *Neurosurgery* 1986;19:641–2.
- [6] Sasaki T, Okamoto K, Ishida T, Kirino T. Cavernous angioma of the internal acoustic meatus – case report. *Neurol Med Chir (Tokyo)* 1999;39:847–51.
- [7] Adachi K, Yoshida K, Akiyama T, Kawase T. Cavernous angioma of the vestibular nerve: case report and literature review. *Surg Neurol* 2008;70:82–6, discussion 86.
- [8] Matias-Guiu X, Alejo M, Sole T, Ferrer I, Noboa R, Bartumeus F. Cavernous angiomas of the cranial nerves. Report of two cases. *J Neurosurg* 1990;73:620–2.
- [9] Fehlings MG, Tucker WS. Cavernous hemangioma of Meckel's cave. Case report. *J Neurosurg* 1988;68:645–7.
- [10] Mascarenhas L, Magalhaes F, Magalhaes Z, Romao H, Resende M, Resende-Pereira J, Honavar M, Rocha Vaz A. Cavernous malformation of the trigeminal nerve. *Neurocirugia (Astur)* 2006;17:64–6, discussion 67.
- [11] Seckin H, Patel N, Avci E, Dempsey RJ, Baskaya MK. Removal of cavernous malformation of the Meckel's cave by extradural pterional approach using Heros muscle dissection technique. *Surg Neurol* 2009;72:733–6, discussion 736.
- [12] Deshmukh VR, Hott JS, Tabrizi P, Nakaji P, Feiz-Erfan I, Spetzler RF. Cavernous malformation of the trigeminal nerve manifesting with trigeminal neuralgia: case report. *Neurosurgery* 2005;56:E623, discussion E623.
- [13] De Benedittis G. SUNCT syndrome associated with cavernous angioma of the brain stem. *Cephalalgia* 1996;16:503–6.
- [14] Shimpo T. Trigeminal neuralgia in pontine cavernous angioma. *J Neurol* 2000;247:139.
- [15] Vitek L, Tettenborn B. Cavernous angioma in the brachium pontis presenting with trigeminal neuralgia: a case report. *Eur Neurol* 2002;48:226–8.
- [16] Cenzato M, Stefini R, Ambrosi C, Latronico N, Milani D. Surgical resolution of trigeminal neuralgia due to intra-axial compression by pontine cavernous angioma. *World Neurosurg* 2010;74:544–6.
- [17] Saito N, Yamakawa K, Sasaki T, Saito I, Takakura K. Intramedullary cavernous angioma with trigeminal neuralgia: a case report and review of the literature. *Neurosurgery* 1989;25:97–101.
- [18] Stellmann JP, Kuhn M, Topper R. Chronic facial pain due to a brainstem cavernoma. *Fortschr Neurol Psychiatr* 2007;75:552–4.
- [19] Porter RW, Detwiler PW, Spetzler RF, Lawton MT, Baskin JJ, Derksen PT, Zabramski JM. Cavernous malformations of the brainstem: experience with 100 patients. *J Neurosurg* 1999;90:50–8.
- [20] Amin-Hanjani S, Ogilvy CS, Candia GJ, Lyons S, Chapman PH. Stereotactic radiosurgery for cavernous malformations: Kjellberg's experience with proton beam therapy in 98 cases at the Harvard Cyclotron. *Neurosurgery* 1998;42:1229–36, discussion 1236–8.
- [21] Pollock BE, Garces YI, Stafford SL, Foote RL, Schomberg PJ, Link MJ. Stereotactic radiosurgery for cavernous malformations. *J Neurosurg* 2000;93:987–91.
- [22] Mathiesen T, Edner G, Kihlstrom L. Deep and brainstem cavernomas: a consecutive 8-year series. *J Neurosurg* 2003;99:31–7.
- [23] Hasegawa T, McInerney J, Kondziolka D, Lee JY, Flickinger JC, Lunsford LD. Long-term results after stereotactic radiosurgery for patients with cavernous malformations. *Neurosurgery* 2002;50:1190–7, discussion 1197–8.
- [24] Francois P, Ben Ismail M, Hamel O, Bataille B, Jan M, Velut S. Anterior transpetrosal and subtemporal transtentorial approaches for pontine cavernomas. *Acta Neurochir (Wien)* 2010;152:1321–9, discussion 1329.
- [25] Cantore G, Missori P, Santoro A. Cavernous angiomas of the brain stem. Intra-axial anatomical pitfalls and surgical strategies. *Surg Neurol* 1999;52:84–93, discussion 93–4.