

Left carotid-anterior cerebral artery anastomosis diagnosed by MR angiography: a case report

Nanami Okano · Akira Uchino · Naoko Saito ·
Hajime Maruyama

Received: 10 May 2014 / Accepted: 4 August 2014
© Springer-Verlag France 2014

Abstract Anastomosis of the carotid-anterior cerebral artery (ACA) is a rare anomalous vessel that arises from the internal carotid artery (ICA) at the level of the ophthalmic artery and takes an infraoptic and prechiasmatic path to anastomose with the ACA. It has known right-sided predominance. We report the case of an 83-year-old man with a left carotid-ACA anastomosis that was diagnosed by magnetic resonance (MR) angiography from the neck to the head during investigation of transient left hemiplegia. The right ICA was occluded at its origin. Our literature search revealed only six reported cases of left carotid-ACA anastomoses. We believe ours is the first case diagnosed by MR angiography.

Keywords Anterior cerebral artery · Arterial variation · Internal carotid artery · MR angiography

Introduction

Carotid-anterior cerebral artery (ACA) anastomosis is a rare intracranial vascular anomaly in which an abnormal vessel arises from the internal carotid artery (ICA) at the level of the ophthalmic artery and takes an infraoptic and prechiasmatic path to anastomose with the ACA [5]. It is also

referred to as “infraoptic course of ACA” [4]. There is a marked right-sided predominance, and it is rarely observed bilaterally [8, 9]. Only six cases of left carotid-ACA anastomosis have been reported [8]. We report the first left-sided case diagnosed by magnetic resonance (MR) angiography.

Case report

An 83-year-old man suffered transient left hemiplegia without loss of consciousness. Ten days before his admission to our hospital, during investigation for his transient dizziness at another hospital, he was diagnosed with severe stenosis of the right ICA at its origin. His medical history included a right maxillary tumor that required resection and idiopathic hypertension. MR imaging of the brain at hospital admission demonstrated multiple embolic infarctions in the territory of the right middle cerebral artery. MR angiography showed obstruction of the right ICA at its origin. The right vertebral artery was hypoplastic, and a large anomalous vessel branching from the left ICA at its ophthalmic segment ran anterior to the optic chiasm to join the anterior communicating artery. The bilateral A1 segments of the ACA were present but hypoplastic (Fig. 1). Schematic illustration of this anomaly is shown in Fig. 2.

Conservative treatment of the patient included intravenous administration of free radical scavengers, glycerol, argatroban, and clopidogrel. He was discharged home and reported no neurological sequelae after 30 days.

Discussion

Carotid-ACA anastomosis is a rare anomaly first reported by Robinson in 1959 [5]. It has been variously described as

N. Okano (✉) · A. Uchino · N. Saito
Department of Diagnostic Radiology, Saitama Medical
University International Medical Center,
1397-1 Yamane, Hidaka, Saitama 350-1298, Japan
e-mail: nanami@saitama-med.ac.jp

H. Maruyama
Department of Neurology and Cerebrovascular Medicine,
Saitama Medical University International Medical Center,
1397-1 Yamane, Hidaka, Saitama 350-1298, Japan

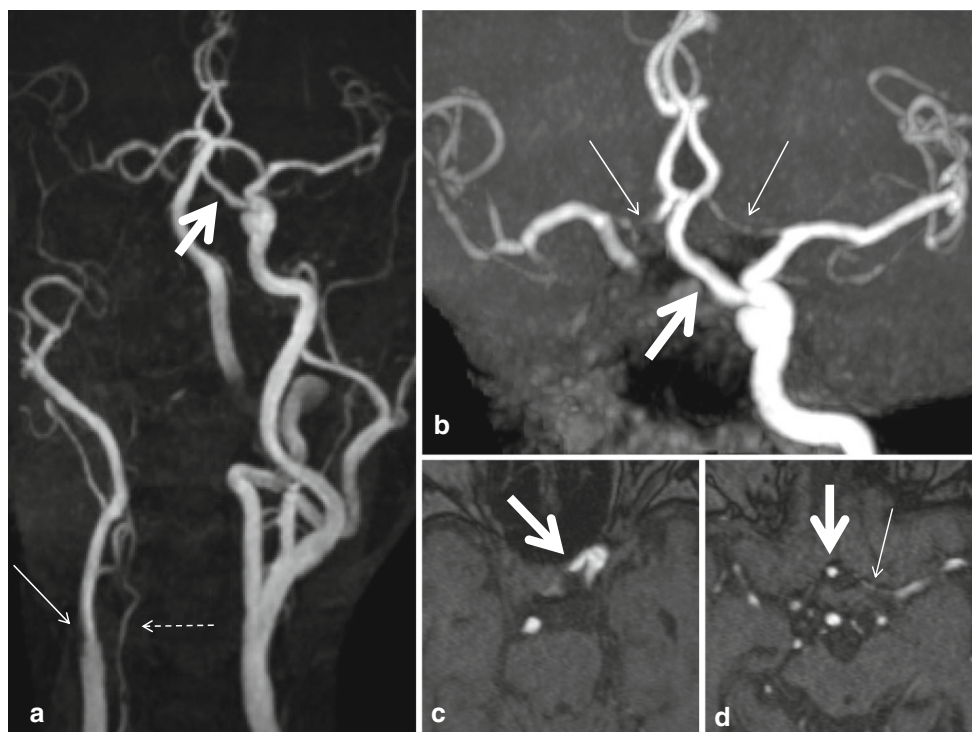
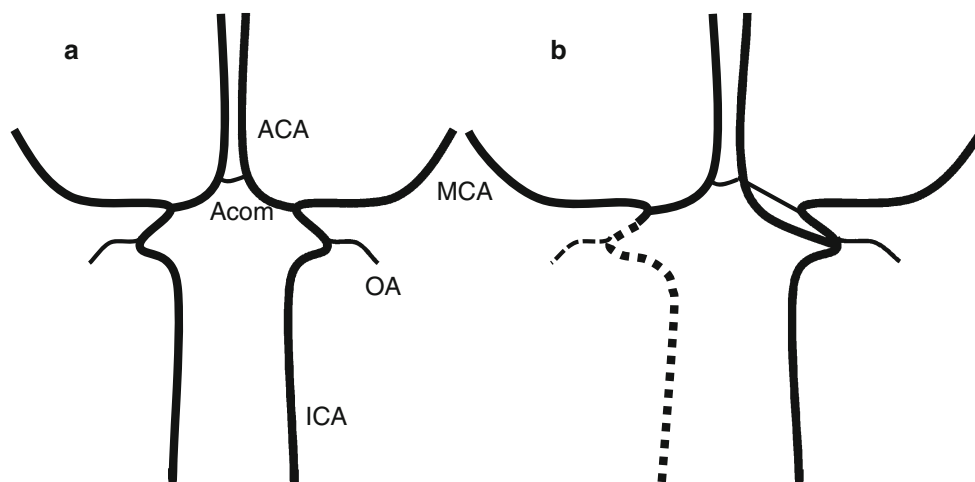


Fig. 1 Magnetic resonance (MR) angiography obtained using a 1.5-T scanner. **a** A maximum-intensity-projection (MIP) image of the anteroposterior projection of the craniocervical MR angiography shows an anomalous artery arising from the left internal carotid artery (ICA) at the level of the ophthalmic artery (*thick arrow*). The right ICA is occluded at its origin (*thin arrow*). The right vertebral artery is hypoplastic (*dotted arrow*). **b** Partial MIP MR angiography, from

which the vertebrobasilar system was deleted, clearly demonstrates the anomalous artery connecting to the anterior communicating artery (*thick arrow*). The bilateral A1 segments of the anterior cerebral artery (ACA) are present but hypoplastic (*thin arrows*). **c, d** MR angiographic source images show the origin of the anomalous artery (*arrow* on **c**) and its prechiasmatic course (*thick arrow* on **d**). The *thin arrow* on **d** indicates the A1 segment of the left ACA

Fig. 2 Schematic illustration of the carotid system in the antero-posterior projection. **a** Normal subject, **b** this case



infraoptic course of the ACA, carotid siphon-pericallosal arterial anastomosis, interoptic course of the ACA, and preoptic origin of the ACA [9]. Despite its small caliber, like that in our patient, there is an ipsilateral A1 segment of the ACA in some cases. Thus, the anomalously originating artery should not be regarded as an anomalous origin of the

A1. Therefore, we use the term “carotid-ACA anastomosis” in this paper.

In 2011, Turkoglu and associates [8] reviewed 47 cases of this variation. The anomaly occurred on the right side in 32 patients, on the left in 6, and bilaterally in 9. Thus, they observed marked right-sided predominance. Since their

review, only two cases of bilateral carotid-ACA anastomoses have been reported [7, 9]; no case of the anomaly on the left has been reported. We believe this is the seventh patient with left carotid-ACA anastomosis, and our case is the first diagnosed by MR angiographic image.

Wong and colleagues [11] classified this anastomosis into three major types. In Type I, there is an ipsilateral normal A1. In Type II, there is no normally originating (supraoptic) A1. In Type III, the bilateral A1 segments are absent. The three types can be regarded as a progression from hypoplasia to aplasia of the bilateral normal A1 segments. Wong's review included 12 cases of Type I, 14 of Type II, and 10 of Type III. Our case had a normally originating ipsilateral A1, and is therefore classified as Type I. In some patients, a tiny (hypoplastic) A1 segment like that in our patient can be identified only on a partial maximum-intensity-projection image (Fig. 1b) or source image (Fig. 1d) of MR angiography. Therefore, Type I with hypoplastic A1 may be misinterpreted as Type II on MR angiography.

This anomaly frequently accompanies a cerebral aneurysm, especially on the anterior communicating artery, possibly because of hemodynamic stress resulting from the anomalous blood flow [2, 6]. Wong's group [11] reported associated cerebral aneurysms in 61 % of patients with this anomaly. However, this may represent a strong selection bias because most reported cases were found during examination or surgery of subarachnoid hemorrhage. Indeed, after the introduction of MR angiography in clinical practice, the anomaly was found incidentally in many patients without associated aneurysm [9].

In most cases, the carotid-ACA anastomosis has no clinical significance itself, but some cases have associated arterial variations/anomalies [1, 4] or brain abnormalities [2, 3]. Our patient had no other abnormality than hypoplasia of the right (contralateral) vertebral artery. His contralateral ICA was occluded at its origin, and this anastomosis played an important role as collateral circulation to the territories of the contralateral ACA and middle cerebral artery.

The literature offers several explanations of the embryogenesis of carotid-ACA anastomosis [4, 6], but the reason for its marked right-sided predominance remains unknown. There is also right-sided predominance of the ophthalmic artery arising from either the middle meningeal artery or the cavernous segment of the ICA [10].

In conclusion, we reported the seventh case of left carotid-ACA anastomosis, the first case diagnosed by MR angiography. Although the reason is unclear, this rare arterial anomaly demonstrates marked right-sided predominance.

Acknowledgments We thank Rosalyn Uhrig, M.A., for her editorial assistance in the preparation of this manuscript.

Conflict of interest We declare that we have no conflict of interest.

References

- Gupta V, Chugh M, Vaishya S (2008) Infraoptic azygous anterior cerebral artery. *Neurol India* 56(4):487–488
- Kan P, Yashar P, Chmuczuk AJ, Levy EI, Hopkins LN, Siddiqui AH (2012) Letter to the editor: Multimodal treatment of co-existent callosal cavernous malformation and anterior communicating artery aneurysm associated with an infraoptic anterior cerebral artery. *Neuroradiology* 54(2):181–183
- McLaughlin N, Bojanowski MW (2007) Infraoptic course of anterior cerebral arteries associated with abnormal gyral segmentation. *Case report. J Neurosurg* 107(2):430–434
- Mercier P, Velut S, Fournier D, Lescalie F, Guy G, Pillet J, Cronier P (1989) A rare embryologic variation: carotid-anterior cerebral artery anastomosis or infraoptic course of the anterior cerebral artery. *Surg Radiol Anat* 11(1):73–77
- Robinson LR (1959) An unusual human anterior cerebral artery. *J Anat* 93(1):131–133
- Spinnato S, Pasqualin A, Chioffi F, Da Pian R (1999) Infraoptic course of the anterior cerebral artery associated with an anterior communicating artery aneurysm: anatomic case report and embryological considerations. *Neurosurgery* 44(6):1315–1319
- Stevenson CB, Chambless LB, Rini DA, Thompson RC (2011) Bilateral infraoptic A1 arteries in association with a craniopharyngioma: case report and review of the literature. *Surg Neurol Int* 2:89
- Turkoglu E, Arat A, Patel N, Kertmen H, Başkaya MK (2011) Anterior communicating artery aneurysm associated with an infraoptic course of anterior cerebral artery and rare variant of the persistent trigeminal artery: a case report and literature review. *Clin Neurol Neurosurg* 113(4):335–340
- Uchino A, Saito N, Okada Y, Inoue K (2012) Carotid-anterior cerebral artery anastomosis on MR angiography: a university hospital-based study. *Neuroradiology* 54(1):13–18
- Uchino A, Saito N, Takahashi M, Kozawa E, Mizukoshi W, Nakajima R, Okano N (2013) Persistent dorsal ophthalmic artery and ophthalmic artery arising from the middle meningeal artery diagnosed by MR angiography at 3 T. *Surg Radiol Anat* 35(9):775–782
- Wong ST, Yuen SC, Fok KF, Yam KY, Fong D (2008) Infraoptic anterior cerebral artery: review, report of two cases and an anatomical classification. *Acta Neurochir (Wien)* 150(10):1087–1096