

- [3] Reddy GK, Bollam P, Shi R, et al. Management of adult hydrocephalus with ventriculoperitoneal shunts: long-term single-institution experience. *Neurosurgery* 2011;69:774–80 [discussion 780–1].
- [4] Wong JM, Ziewacz JE, Ho AL, et al. Patterns in neurosurgical adverse events: cerebrospinal fluid shunt surgery. *Neurosurg Focus* 2012;33:E13.
- [5] Rehman AU, Rehman TU, Bashir HH, et al. A simple method to reduce infection of ventriculoperitoneal shunts. *J Neurosurg Pediatr* 2010;5:569–72.
- [6] Vacca V. Diagnosis and treatment of idiopathic normal pressure hydrocephalus. *J Neurosci Nurs* 2007;39:107–11.
- [7] Veeravagu A, Ludwig C, Camara-Quintana JQ, et al. Fungal infection of a ventriculoperitoneal shunt: histoplasmosis diagnosis and treatment. *World Neurosurg* 2013;80:222.e5–13.
- [8] Ingram CW, Haywood HB, Morris VM, et al. Cryptococcal ventricular-peritoneal shunt infection: clinical and epidemiological evaluation of two closely associated cases. *Infect Control Hosp Epidemiol* 1993;14:719–22.
- [9] Mirza SA, Phelan M, Rimland D, et al. The changing epidemiology of cryptococcosis: an update from population-based active surveillance in 2 large metropolitan areas, 1992–2000. *Clin Infect Dis* 2003;36:789–94.
- [10] Zarrin M, Zarei Mahmoudabadi A. Central nervous system fungal infections; a review article. *Jundishapur J Microbiol* 2010;3:41–7.
- [11] To KK, Cheng VC, Tang BS, et al. False-negative cerebrospinal fluid cryptococcal antigen test due to small-colony variants of *Cryptococcus neoformans* meningitis in a patient with cystopleural shunt. *Scand J Infect Dis* 2006;38:1110–4.
- [12] Yadav SS, Perfect J, Friedman AH. Successful treatment of cryptococcal ventriculoatrial shunt infection with systemic therapy alone. *Neurosurgery* 1988;23:372–3.
- [13] Mangham D, Gerding DN, Peterson LR, et al. Fungal meningitis manifesting as hydrocephalus. *Arch Intern Med* 1983;143:728–31.

<http://dx.doi.org/10.1016/j.jocn.2014.04.013>

Endovascular thrombectomy and stenting in the management of carotid fibromuscular dysplasia presenting with major ischemic stroke



José E. Cohen^{a,b,*}, Eyal Itshayek^a, Galina Keigler^c, Roni Eichel^c, Ronen R. Leker^c

^a Department of Neurosurgery, Hadassah-Hebrew University Medical Center, POB 12000, Jerusalem 91120, Israel

^b Department of Endovascular Neurosurgery and Interventional Neuroradiology, Hadassah-Hebrew University Medical Center, Jerusalem, Israel

^c Department of Neurology, Hadassah-Hebrew University Medical Center, Jerusalem, Israel

ARTICLE INFO

Article history:

Received 24 July 2014

Accepted 28 July 2014

Keywords:

Carotid artery
Fibromuscular dysplasia
Ischemic stroke
Stent
Thrombectomy

ABSTRACT

Fibromuscular dysplasia (FMD) affecting the internal carotid artery (ICA) is considered a benign condition; however, retinal and cerebral ischemic events may occur. We present a patient with carotid FMD presenting with a major ischemic stroke due to major embolic occlusion of the ICA in conjunction with a hemodynamic component caused by narrowing and beading of the lumen associated with FMD. The patient was successfully treated with intracranial stent-assisted thrombectomy followed by cervical ICA stenting that aimed to reconstruct and angioplasty the FMD-affected arterial segment. Recently, stent-based thrombectomy has emerged as the most effective endovascular option for the rapid revascularization of major intracranial occlusions; however, to our knowledge, its use in a rare case of FMD-associated major stroke has not yet been reported.

© 2014 Elsevier Ltd. All rights reserved.

1. Introduction

Fibromuscular dysplasia (FMD) affecting the internal carotid artery (ICA) is considered a benign condition, and is usually detected incidentally [1,2]. However, it is an infrequent cause of retinal and cerebral ischemic events and, in rare cases, of major ischemic stroke. It most commonly occurs in middle-aged women [1–4]. We present a patient with carotid FMD presenting with a major ischemic stroke, successfully treated by intracranial stent-assisted thrombectomy followed by cervical ICA stenting.

2. Case presentation

A 47-year-old woman with an unremarkable medical history except for hypertension and chronic headaches was admitted through the emergency room 3 hours after presenting with an episode of sudden onset speech alterations and right-side hemiparesis. Upon admission, gaze deviation, global aphasia and dense right hemiparesis were evident (National Institutes of Health Stroke Scale 24). Urgent noncontrast head CT scan ruled out intracranial hemorrhage but showed incipient signs of insular cortex

grey-white matter effacement. CT angiogram confirmed occlusion of the distal left ICA.

The patient was urgently brought to the neurointerventional suite and general anesthesia was induced. Diagnostic angiogram confirmed complete “T” occlusion of the left ICA and showed the “string of beads” pattern preceded by a tapered luminal stenosis that is characteristic of FMD, but there were no signs of dissection (Fig. 1).

The distal ICA was rapidly recanalized by way of stent-based thrombectomy, as described in a previous technical note [5]. Briefly, an 8 French balloon-tipped guiding catheter was placed at the proximal ICA. Coaxially, a 0.02 inch microcatheter was navigated across the occluded arterial segment and a self-expandable microstent (Solitaire, Covidien/eV3, Plymouth, MN, USA) was deployed across the embolus and retrieved under proximal occlusion and aspiration. After complete ICA recanalization was confirmed (Fig. 2), 300 mg of aspirin and 600 mg of clopidogrel were administered per nasogastric tube and the ICA segment affected by FMD was covered by a single carotid stent to achieve angiographic reconstruction of the artery (Fig. 3).

Coagulation tests performed at admission and cardiovascular studies at admission and on follow-up were unremarkable. No cardioembolic sources were detected on prolonged Holter, echocardiographic and tomographic cardiovascular studies. The renal arteries were not found to be affected by FMD. The patient was

* Corresponding author. Tel.: +972 2 677 7092; fax: +972 2 641 6281.

E-mail address: jcohenns@yahoo.com (J.E. Cohen).

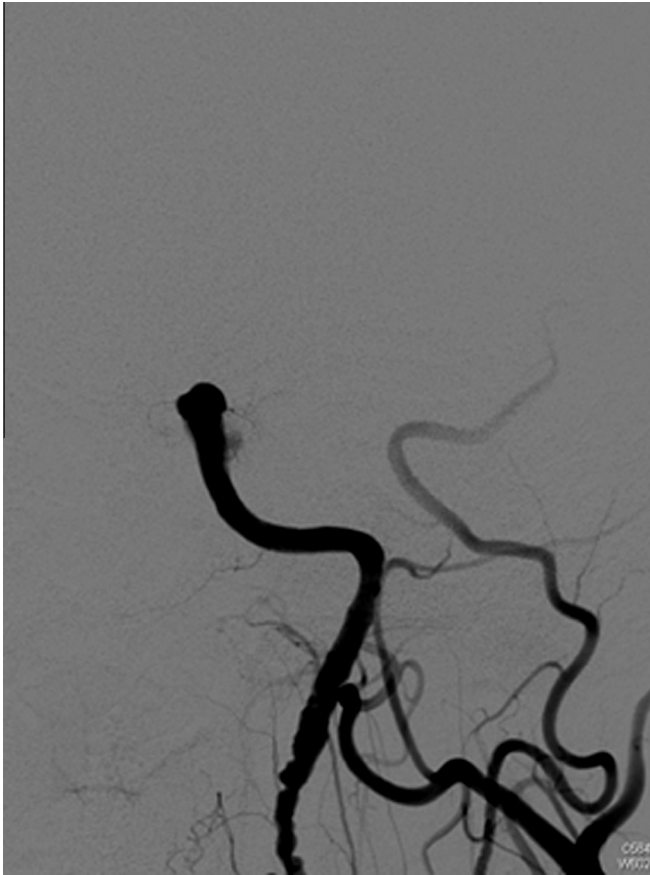

Fig. 1. Selective angiogram of the left common carotid artery showing complete “T” occlusion of the distal left internal carotid artery and demonstrating the characteristic “string of beads” pattern, preceded by a tapered luminal stenosis, associated with fibromuscular dysplasia. There are no signs of an associated dissection.

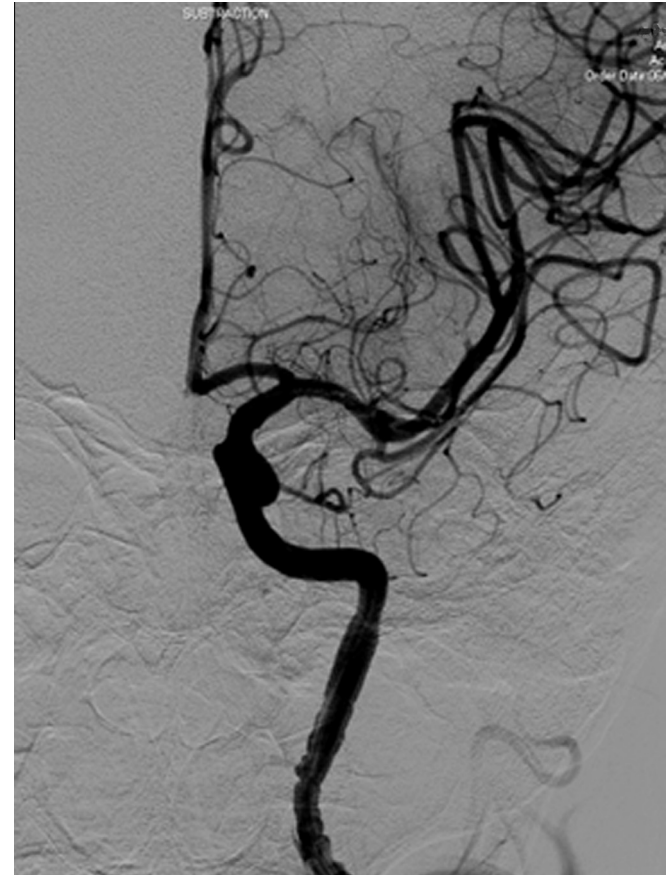

Fig. 2. The distal internal carotid artery was rapidly recanalized with a standard stent-based thrombectomy procedure. Immediately afterwards, angioplasty was performed in the fibromuscular dysplasia segment before stent implantation.

continued on aspirin and clopidogrel therapy, and made a rapid and uneventful neurological recovery. She was discharged home after 7 days with only mild residual right arm paresis. At 90 days, the patient achieved complete neurological recovery (modified Rankin Scale score 0).

3. Discussion

FMD is a systemic arteriopathy with a predilection for the renal arteries, followed by the cervical vessels. FMD of the extracranial ICA is an infrequent and generally incidental finding that is usually asymptomatic [1,2]. The prevalence of FMD is 0.5–0.7% by angiography and in the vast majority of patients it presents a benign natural history. It usually occurs in middle-aged women and is secondary to medial fibrodysplasia or, less commonly, intimal fibrodysplasia. On vascular studies in patients with FMD, the ICA may be elongated or kinked, and may show the characteristic “string of beads” luminal narrowing, in some cases with associated aneurysms. Antiplatelet agents represent the cornerstone of therapy in these patients. Rarely, ICA FMD can present with thromboembolic or hemodynamic ischemic events, spontaneous or posttraumatic dissection, aneurysmal degeneration, or intracranial hemorrhage [6]. Transient ischemic attack or stroke are uncommon, but may occur due to low flow or embolization of platelet aggregates [3,4]. Major ischemic stroke may occur after a flow-limiting complicating dissection or luminal narrowing associated

with FMD, emboli secondary to luminal irregularities or complicating dissection, or after a combination of these mechanisms.

The presented patient debuted with a major embolic occlusion of the ICA in conjunction with a hemodynamic component caused by narrowing and beading of the lumen associated with FMD. The therapeutic strategy consisted of intracranial stent-assisted thrombectomy using a technique comparable to the approach we have described in more typical embolic occlusions of the intracranial circulation, followed by cervical ICA stenting that aimed to reconstruct and angioplasty the FMD-affected arterial segment. Percutaneous angioplasty has emerged as the preferred treatment for symptomatic ischemic cerebrovascular FMD without intracranial occlusions [7], but surgical and hybrid procedures are still practiced by different groups with acceptable results [8]. Recently, stent-based thrombectomy has emerged as the most effective endovascular option for the rapid revascularization of major intracranial occlusions [9]; however, to our knowledge, its use in a rare case of FMD-associated major stroke has not yet been reported.

The endovascular repair sequence chosen for this patient (that is, intracranial thrombectomy followed by ICA stenting) is analogous to the procedural sequence already proposed for the revascularization of tandem middle cerebral artery and ICA occlusions [10]. In patients with tandem occlusions, extracranial stenting is performed before intracranial stent-based thrombectomy, and we recommend the use of closed-cells stents (such as Wallstent, Boston Scientific, Marlborough, MA, USA). Alternatively, the guiding catheter should be advanced beyond the implanted stent to reduce the risk of trapping the thrombectomy device in the implanted carotid stent.

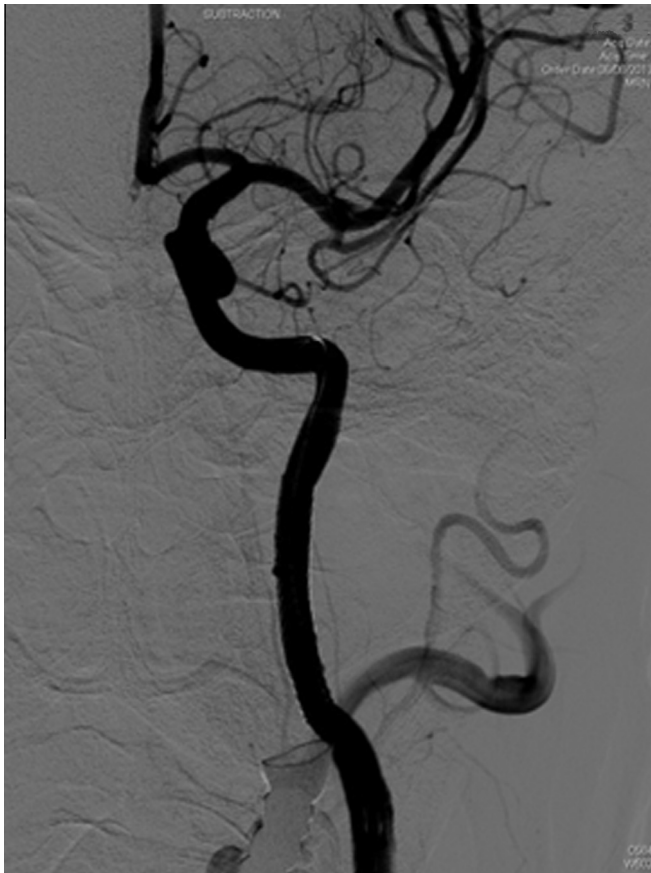


Fig. 3. Angiogram obtained immediately after carotid stent implantation shows reconstruction of the fibromuscular dysplasia-affected internal carotid artery segment.

The current patient contributes to the rapidly growing body of evidence on the endovascular management of major ischemic

<http://dx.doi.org/10.1016/j.jocn.2014.07.008>

stroke using a two-step procedure, namely revascularization of the intracranial occlusion with immediate subsequent correction of the causative condition.

Conflicts of Interest/Disclosures

The authors declare that they have no financial or other conflicts of interest in relation to this research and its publication.

Acknowledgements

The authors wish to thank Shifra Fraifeld, a research associate and senior medical writer in the Department of Neurosurgery at the Hadassah-Hebrew University Medical Center, for her editorial contribution during the preparation of the manuscript.

References

- [1] Olin JW, Froehlich J, Gu X, et al. The United States Registry for fibromuscular dysplasia: results in the first 447 patients. *Circulation* 2012;125:3182–90.
- [2] Slovut DP, Olin JW. Fibromuscular dysplasia. *N Engl J Med* 2004;350:1862–71.
- [3] Matonti F, Prost Magnin O, Galland F, et al. Internal carotid artery dissection on arterial fibromuscular dysplasia causing a central retinal artery occlusion: a case report. *J Fr Ophthalmol* 2006;29:e15.
- [4] Altun A, Altun G, Olcaysu OO, et al. Central retinal artery occlusion in association with fibromuscular dysplasia. *Clin Ophthalmol* 2013;7:2253–5.
- [5] Cohen JE, Rabinstein AA, Ramirez-de-Noriega F, et al. Excellent rates of recanalization and good functional outcome after stent-based thrombectomy for acute middle cerebral artery occlusion. Is it time for a paradigm shift? *J Clin Neurosci* 2013;20:1219–23.
- [6] Stewart MT, Moritz MW, Smith 3rd RB, et al. The natural history of carotid fibromuscular dysplasia. *J Vasc Surg* 1986;3:305–10.
- [7] Slovut DP, Olin JW. Fibromuscular dysplasia. *Curr Treat Options Cardiovasc Med* 2005;7:159–69.
- [8] Assadian A, Senekowitsch C, Assadian O, et al. Combined open and endovascular stent grafting of internal carotid artery fibromuscular dysplasia: long term results. *Eur J Vasc Endovasc Surg* 2005;29:345–9.
- [9] Leker RR, Eichel R, Gomori JM, et al. Stent-based thrombectomy versus intravenous tissue plasminogen activator in patients with acute middle cerebral artery occlusion. *Stroke* 2012;43:3389–91.
- [10] Cohen JE, Gomori M, Rajz G, et al. Emergent stent-assisted angioplasty of extracranial internal carotid artery and intracranial stent-based thrombectomy in acute tandem occlusive disease: technical considerations. *J Neurointerv Surg* 2013;5:440–6.

Pediatric cerebral ganglioneuroblastoma

Sean P. Steenberge, Richard A. Prayson*

Cleveland Clinic Lerner College of Medicine and Department of Pathology, L25 9500 Euclid Avenue, Cleveland, OH 44195, USA



ARTICLE INFO

Article history:

Received 15 July 2014

Accepted 28 July 2014

Keywords:

Brain tumor

Ganglioneuroblastoma

Pediatric brain tumor

Primitive neuroectodermal tumor

ABSTRACT

We describe a 4-year-old girl with acute onset headaches and transient blindness who underwent surgical intervention, chemotherapy, and radiotherapy for an intracranial mass. This mass was pathologically confirmed as a primary intracranial ganglioneuroblastoma, a rare finding in the pediatric population. The literature on pediatric primary intracranial ganglioneuroblastoma is reviewed.

© 2014 Elsevier Ltd. All rights reserved.

* Corresponding author. Tel.: +1 216 444 8805; fax: +1 216 445 6967.

E-mail address: prayson@ccf.org (R.A. Prayson).