



## Short communication

## Central retinal artery occlusion with concomitant ipsilateral cerebral infarction after cosmetic facial injections



Jeong-Ho Hong<sup>a,1</sup>, Seong Joon Ahn<sup>b,1</sup>, Se Joon Woo<sup>b</sup>, Cheolkyu Jung<sup>c</sup>, Jun Young Chang<sup>d</sup>, Jin-Heon Chung<sup>d</sup>, Moon-Ku Han<sup>d,\*</sup>

<sup>a</sup> Department of Neurology, Keimyung University Dongsan Medical Center, Daegu, Republic of Korea

<sup>b</sup> Department of Ophthalmology, Seoul National University Bundang Hospital, Seongnam, Republic of Korea

<sup>c</sup> Department of Radiology, Seoul National University Bundang Hospital, Seongnam, Republic of Korea

<sup>d</sup> Department of Neurology, Seoul National University Bundang Hospital, Seongnam, Republic of Korea

## ARTICLE INFO

## Article history:

Received 25 July 2014

Received in revised form 19 August 2014

Accepted 20 August 2014

Available online 28 August 2014

## Keywords:

Autologous fat

Filler

Cerebral infarction

Retinal artery occlusion

Cosmetic

Ophthalmic artery

## ABSTRACT

We report 2 cases of central retinal artery occlusion with concomitant ipsilateral cerebral infarction after cosmetic facial injections and a literature review. The 2 patients were two healthy women, in which cosmetic facial injections with autologous fat and filler were performed, respectively. The patients had no light perception at the final visit and their conditions led to memory retrieval disturbance in case 1 and right arm weakness, dysarthria, facial palsy, and ophthalmoplegia in case 2. Neuroimaging showed multifocal small infarctions in the ipsilateral frontal lobe with occlusion of the ophthalmic artery in case 1 and multiple infarctions in the ipsilateral anterior and middle cerebral artery territories with subsequent hemorrhagic transformation in case 2. Poor visual prognosis and neurological complications can occur in healthy adults undergoing cosmetic facial injection, and all patients should be informed of this risk before the procedure.

© 2014 Elsevier B.V. All rights reserved.

### 1. Introduction

Facial autologous fat injections for esthetic soft-tissue augmentation are becoming popular. Hyaluronic acid filler is also becoming a material of choice in cosmetic soft-tissue correction. Although cosmetic facial injections of autologous fat or hyaluronic acid filler are considered safe, post-procedural retinal and ophthalmic artery occlusion and facial skin damage have been reported [1–8]. In previous cases, central retinal artery occlusion (CRAO), an ocular vascular occlusive disorder that leads to permanent vision loss, occurred in healthy patients.

We report 2 cases that experienced concomitant ipsilateral cerebral infarction and CRAO after cosmetic facial injections and conducted a systematic review of related literature. Retinal and cerebral parenchymal

abnormalities were investigated using optical coherence tomography (OCT) and magnetic resonance imaging (MRI).

### 2. Case reports

#### 2.1. Case 1

A 27-year-old woman presented with vision loss in the left eye immediately after autologous fat injection performed under local anesthesia. She had received an autologous fat injection into her glabella, forehead, and cheeks for cosmetic purposes. During the injection, she had experienced sudden, severe periocular pain. Her consciousness was normal, and brief neurologic examinations in the emergency room were not remarkable.

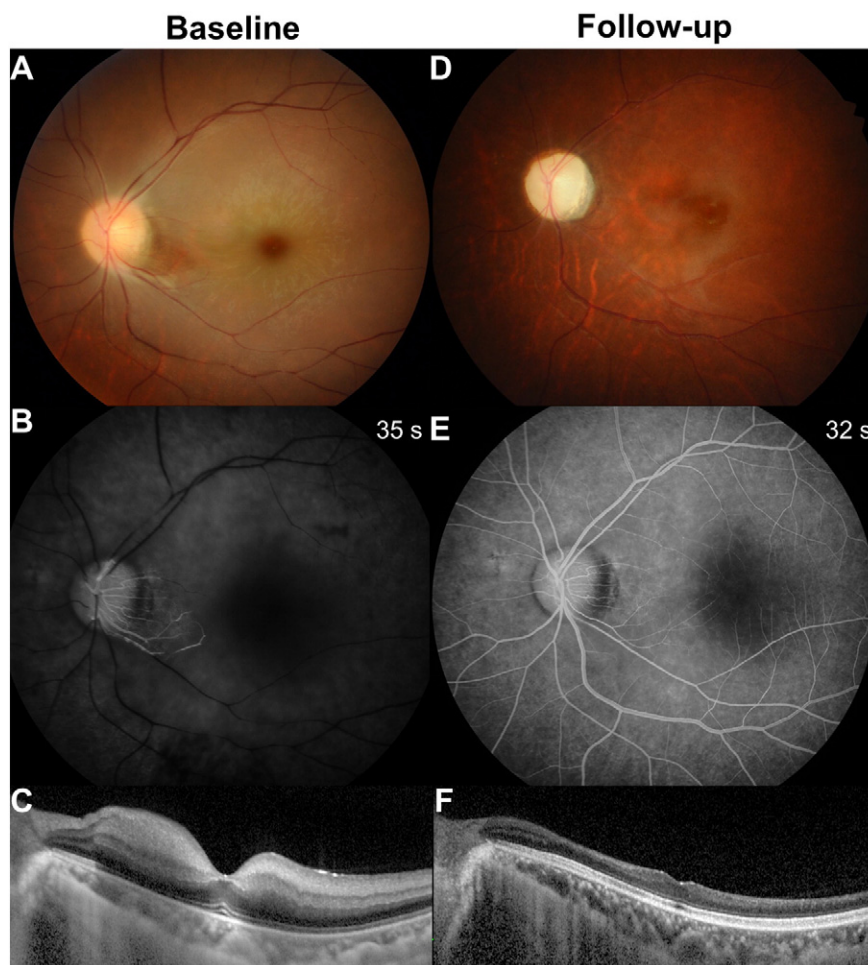
Her vision was 20/20 in the right eye, but she had no light perception in the left eye. Ocular examination showed a dilated pupil without light reflex in the left eye. Ophthalmoplegia was not noted. Fundoscopic examination of the affected eye showed retinal whitening with arteriolar narrowing (Fig. 1A), but fat emboli were not identifiable. Fundus fluorescein angiography (FA) showed significant delay of retinal arterial perfusion (Fig. 1B), and OCT showed inner retinal edema in the left eye compatible with typical CRAO (Fig. 1C).

*Abbreviations:* CRAO, central retinal artery occlusion; OCT, optical coherence tomography; MRI, magnetic resonance imaging; FA, fluorescein angiography; MRA, magnetic resonance angiography; MRC, Medical Research Council.

\* Corresponding author at: Department of Neurology, Seoul National University Bundang Hospital, Seoul National University College of Medicine, 300 Gumi-dong, Bundang-gu, Seongnam-si, Gyeonggi-do 463-707, Republic of Korea. Tel.: +82 31 787 7464; fax: +82 31 787 4059.

E-mail address: [mkhan@snu.ac.kr](mailto:mkhan@snu.ac.kr) (M.-K. Han).

<sup>1</sup> The authors contributed equally to this work.



**Fig. 1.** Case 1 with central retinal artery occlusion after autologous fat injection at baseline (A–C) and at the 1-year follow-up examination (D–F). A and D, Fundus photographs show retinal whitening with cherry red spot at baseline and a pale disc at follow-up examination. B and E, Fluorescein angiographs show remarkably delayed retinal perfusion at baseline and improved perfusion at the follow-up examination. Text in the upper right corner indicates the time at which images were taken. C and F, Optical coherence tomography images demonstrate inner retinal edema at baseline, which subsequently underwent atrophic changes. At the follow-up examination, the retina is thin and the layer-by-layer structure is indefinite, especially in the inner retinal layers.

Diffusion-weighted brain imaging showed multifocal small acute infarctions in the left frontal lobe (Fig. 2A). Magnetic resonance angiography (MRA) revealed occlusion of the left ophthalmic artery (arrows, Fig. 2B).

On admission, she complained of short-term memory disturbance and naming difficulty, which was assessed as memory retrieval disturbance by neuropsychological screening battery.

At the 1-year follow-up visit, the patient's vision had not improved. The follow-up fundus photography revealed a pale optic disc and diffuse retinal atrophy with arteriolar narrowing (Fig. 1D). Retinal arterial perfusion was restored on FA (Fig. 1E), but significant inner retinal thinning was observed on OCT (Fig. 1F). Neurologic deficits had improved mildly but were still present.

## 2.2. Case 2

A 50-year-old woman who previously had normal vision in both eyes presented with vision loss in the left eye and right arm weakness 1 day after facial filler (hyaluronic acid) injection into her glabella and cheeks. Her neurologic examination revealed dysarthria and facial palsy on the right side. Her right upper extremity showed Medical Research Council (MRC) grade 1, and her lower limb showed MRC grade 4.

Her vision was 20/20 in the right eye and no light perception in the left eye. Conjunctival injection, cataract, and diffuse corneal stromal edema in the left eye were also noted. The corneal edema and cataract

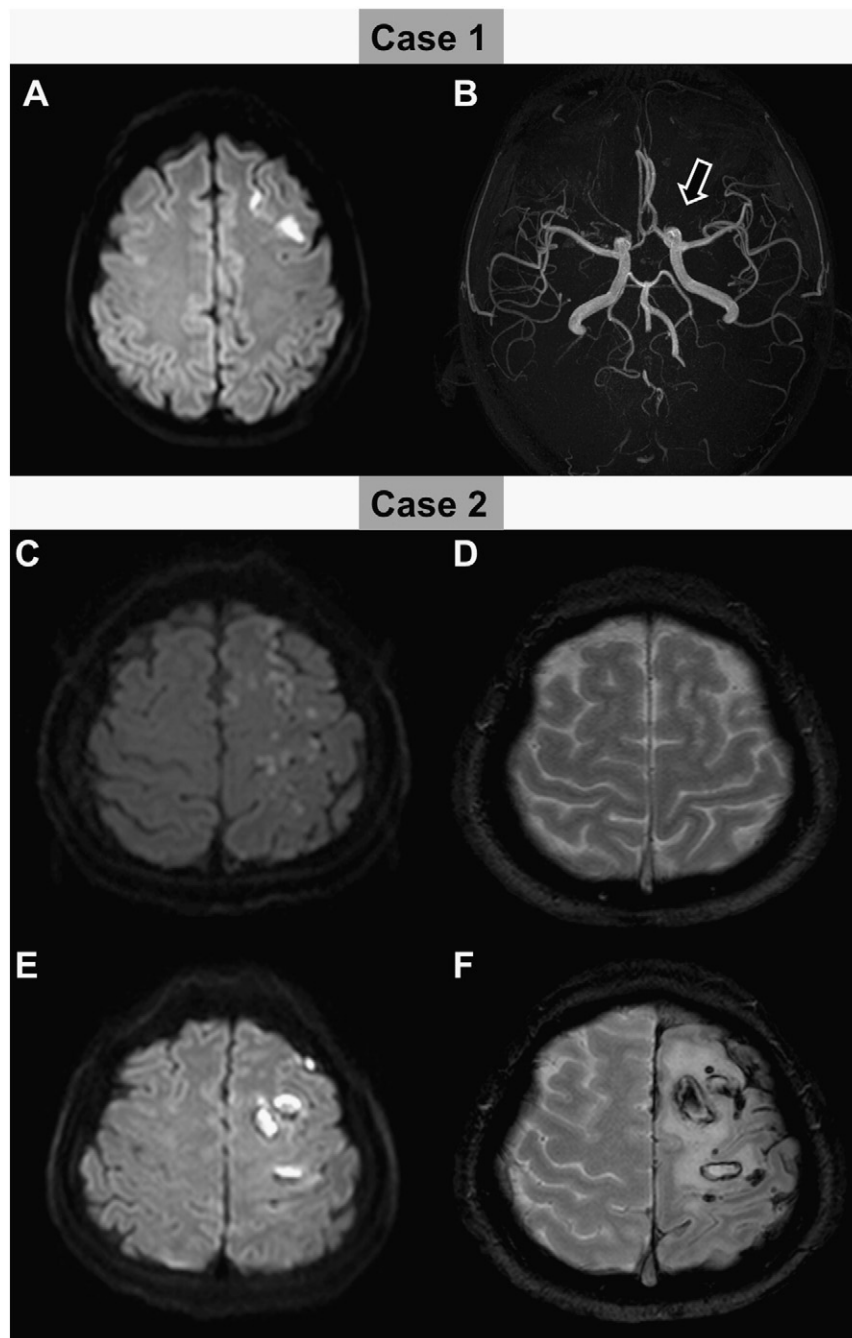
in the left eye obscured the fundoscopic view. The superior retina was visible only on FA, which revealed retinal and choroidal perfusion delay, compatible with CRAO. Ptosis in the left eye and left exotropia of 35-prism diopter were observed using the Krimsky method. Near-total ophthalmoplegia (limitation of adduction, elevation, and depression and mild limitation of abduction) was found in the left eye.

An initial outside MRI revealed multiple small acute infarctions in the left anterior and middle cerebral artery territories without hemorrhagic transformation (Fig. 2C–D). However, at a 2-week follow-up examination, MRI showed hemorrhagic transformation in the infarcted area (Fig. 2E–F).

Two months later, she had no light perception in the left eye. Her ophthalmoplegia in the left eye resolved, but showed a mild limitation of elevation. Conjunctival injection and corneal edema resolved. However, the cataract in the left eye had progressed, and the view of the fundus was occluded by the cataract. At 6 months, she was able to walk without assistance but required some help because of moderate disability of her upper limb (MRC grade 3).

## 3. Discussion

We report the clinical manifestations, angiographic features, retinal and brain parenchymal changes, and final visual and neurologic outcomes in 2 cases of combined CRAO and ipsilateral cerebral ischemia after cosmetic facial injections of fillers. The 2 patients were healthy



**Fig. 2.** Magnetic resonance imaging (MRI). A and B, Initial brain MR images in case 1. A, Diffusion-weighted MRI shows multifocal small acute infarctions in the left frontal lobe. B, Magnetic resonance angiography reveals occlusion of the left ophthalmic artery. C–F, Brain MR images in case 2 at the initial and follow-up examination. C and D, Diffusion-weighted MRI (C) and gradient echo image (D) show multiple small acute infarctions in the left anterior and middle cerebral artery territories without hemorrhagic transformation. E and F, Follow-up MR images at 2 weeks show hemorrhagic transformation in the infarcted area.

women, i.e., typical patients undergoing cosmetic facial injections, without any risk factors for CRAO and cerebral infarction such as hypertension, diabetes, dyslipidemia and cardioembolism. Visual outcomes in the patients were very poor (no light perception in both cases), even compared with other cases of CRAO.

Several authors have reported cases of ocular and cerebral ischemia after autologous fat ( $n = 9$ , including our case) and filler ( $n = 2$ , including our case) injections in the glabellar or paranasal area (Table 1). However, abnormalities of the retina and brain in these cases were not well documented on neurologic imaging with brain MRI and MRA or retinal imaging with OCT. From the brain and retinal sectional images obtained at baseline and follow-up, our report demonstrated

both retinal and brain abnormalities, which led to significant structural and functional losses in the retina and brain.

Retrograde embolic infarction was suggested as the mechanism underlying the combined CRAO and cerebral infarction after cosmetic facial injections [1,8,9]. The materials injected into the facial peripheral branches of the ophthalmic artery during cosmetic procedures can migrate to more proximal sites of the arterial system by the force of the injection. When the substance reaches the ophthalmic or central retinal artery or cerebral arteries by anterograde embolism. This hypothesis is supported by our additional finding that lesion of cerebral infarction has the same laterality as CRAO in the previous and our cases.

**Table 1**  
Summary of the clinical characteristics of ours and previously reported cases of combined central retinal artery occlusion and cerebral infarction after cosmetic facial injections.

Author	Year	Age, years	Sex	Underlying disease	No. of cases	Cosmetic injection		Ophthalmic examinations					Neurologic symptom	Infarcted territory (diagnostic tool)	Neurologic sequelae (follow-up period)
						Material used	Site	Side	Baseline BCVA	Final BCVA (follow-up period)	Ophthalmoplegia	Ptosis			
Egido et al. [4]	1993	47	F	None	1	Autologous fat	Glabellar area	R	No light perception	Remained blind (3 weeks)	Present	N/A	Anosognosia and L. unilateral spatial neglect, L. hemiplegia and facial palsy	R. frontal and parietal lobe (CT)	L. hemiplegia (3 weeks)
Lee et al. [7]	1996	42	F	N/A	1	Autologous fat	Nasolabial groove	L	N/A	No light perception (3 months)	N/A	N/A	Mental change and headache	L. caudate head, thalamus, and subcortical white matter (MRI)	N/A
Feinendegen et al. [6]	1998	47	F	None	1	Autologous fat	Periorbital area	L	N/A	N/A	Present	N/A	R. hemiplegia and global aphasia	L. hemisphere at the ACA–MCA and MCA–PCA border zones (CT and MRI)	L. hemiparesis (a few weeks)
Danesh-Meyer et al. [2]	2001	43	M	N/A	1	Autologous fat	Paranasal area, nasolabial fold, and the upper and lower lips	L	No light perception	Remained blind (N/A)	Absent	Absent	R. hemiparesis and aphasia	N/A	Normal (N/A)
Yoon et al. [11]	2003	39	F	None	1	Autologous fat	Glabellar area	L	N/A	N/A	Present	N/A	R. hemiplegia and aphasia	L. total hemisphere (CT and MRI)	Died (4 days)
Lee et al. [12]	2012	26	F	N/A	1	Autologous fat	N/A (face)	R	N/A	N/A	Present	N/A	L. hemiparesis and facial palsy	R. frontoparietal lobe (CT and MRI)	N/A
Park et al. [1]	2012	24/26	F	None	2	Autologous fat/Autologous fat	Glabellar area	L/L	No light perception/light perception	No light perception (56 months)/light perception (16 months)	Present/absent	Present/absent	N/A	L. MCA territory/L. MCA and B. ACA territories (MRI)	N/A
He et al. [9]	2013	52	F	N/A	1	Hyaluronic acid	Glabellar area	R	No light perception	Remained blind	N/A	N/A	L. hemianopia	R. ACA, MCA, and PCA territories (MRI)	L. hemianopia (1 month)
Present study	2014	27/50	F	None	2	Autologous fat/Hyaluronic acid	Glabella, forehead, and cheeks	L/L	No light perception	No light perception	Absent/present	Absent/present	Short-term memory disturbance and naming difficulty/R. hemiparesis and facial palsy	L. frontal lobe with occlusion of ophthalmic artery (MRI and MRA)/L. multiple small acute infarctions in ACA and MCA territories with hemorrhagic transformation (MRI)	Memory retrieval disturbance (1 year)/R. hemiparesis and facial palsy (6 months)

R, right; L, left; B, both; ACA, anterior cerebral artery; BCVA, best corrected visual acuity; CT, computed tomography; F, female; F/U, follow-up; M, male; MCA, middle cerebral artery; MRA, magnetic resonance angiography; MRI, magnetic resonance imaging; N/A, not applicable or mentioned; PCA, posterior cerebral artery.

Compared with the first case, our second case showed more extensive ocular and cerebral ischemia, represented by (1) anterior segment ischemia of the eye and ophthalmoplegia and (2) greater ischemic lesion of the brain with hemorrhagic transformation. We suspected complete obstruction of the ophthalmic artery and cerebral arteries, which commonly results from the retrograde migration of the injected substance and anterograde embolism.

Slow and superficial fat injections with small needles and aspiration before the injection have been suggested to minimize the risk of embolization [10]. Additionally, patients should also be informed of the possibility of these complications, which may lead to permanent visual and neurological deficits.

In conclusion, we report that concomitant CRAO and ipsilateral cerebral infarction may occur after cosmetic facial injections, and these may result in poor visual prognosis and neurological complications in healthy adults. Therefore, cosmetic facial injection should be performed carefully, and the risk of brain and ocular damage should be explained to all patients considering this procedure.

#### Funding sources

None.

#### Disclosures

None.

#### Acknowledgments

None.

#### References

- [1] Park SW, Woo SJ, Park KH, Huh JW, Jung C, Kwon OK. Iatrogenic retinal artery occlusion caused by cosmetic facial filler injections. *Am J Ophthalmol* 2012;154:653–62 [e651].
- [2] Danesh-Meyer HV, Savino PJ, Sergott RC. Case reports and small case series: ocular and cerebral ischemia following facial injection of autologous fat. *Arch Ophthalmol* 2001;119:777–8.
- [3] Dreizen NG, Framm L. Sudden unilateral visual loss after autologous fat injection into the glabellar area. *Am J Ophthalmol* 1989;107:85–7.
- [4] Egido JA, Arroyo R, Marcos A, Jimenez-Alfaro I. Middle cerebral artery embolism and unilateral visual loss after autologous fat injection into the glabellar area. *Stroke* 1993;24:615–6.
- [5] Feinendegen DL, Baumgartner RW, Schroth G, Mattle HP, Tschopp H. Middle cerebral artery occlusion and ocular fat embolism after autologous fat injection in the face. *J Neurol* 1998;245:53–4.
- [6] Feinendegen DL, Baumgartner RW, Vuadens P, Schroth G, Mattle HP, Regli F, et al. Autologous fat injection for soft tissue augmentation in the face: a safe procedure? *Aesthetic Plast Surg* 1998;22:163–7.
- [7] Lee DH, Yang HN, Kim JC, Shyn KH. Sudden unilateral visual loss and brain infarction after autologous fat injection into nasolabial groove. *Br J Ophthalmol* 1996;80:1026–7.
- [8] Park KH, Kim YK, Woo SJ, Kang SW, Lee WK, Choi KS, et al. Iatrogenic occlusion of the ophthalmic artery after cosmetic facial filler injections: a national survey by the Korean retina society. *JAMA Ophthalmol* 2014;132:714–23.
- [9] He MS, Sheu MM, Huang ZL, Tsai CH, Tsai RK. Sudden bilateral vision loss and brain infarction following cosmetic hyaluronic acid injection. *JAMA Ophthalmol* 2013;131:1234–5.
- [10] Lazzeri D, Agostini T, Figus M, Nardi M, Pantaloni M, Lazzeri S. Blindness following cosmetic injections of the face. *Plast Reconstr Surg* 2012;129:995–1012.
- [11] Yoon SS, Chang DI, Chung KC. Acute fatal stroke immediately following autologous fat injection into the face. *Neurology* 2003;61:1151–2.
- [12] Lee KM, Kim EJ, Jahng GH, Chang DI. Magnetic resonance findings in two episodes of repeated cerebral fat embolisms in a patient with autologous fat injection into the face. *J Korean Neurosurg Soc* 2012;51:312–5.