

2. Fontaine R, Breton G, Fontaine S, et al: MRI in panic disorders: atrophy and decreased signal in T1 (presented at the 141st Annual Meeting of the American Psychiatric Association, May 7-12, 1988, Montreal, Quebec, Canada), in 1988 CME Syllabus and Proceedings Summary. Washington, DC, American Psychiatric Association, 1988, p 173
3. Swanson LW: The hippocampus and the concepts of the limbic system, in *Neurobiology of the Hippocampus*. Edited by Seifert W. New York, Academic Press, 1983, pp 3-19
4. Rosene DL, Van Hoesen GW: Hippocampal efferents reach widespread areas of cerebral cortex and amygdala in the rhesus monkey. *Science* 1977; 198:315-317
5. Smith OA, De Vito J: Central neural integration for the control of autonomic responses associated with emotion. *Annu Rev Neurosci* 1984; 7:43-65
6. Reiman E, Raichle ME, Robins E, et al: The application of positron emission tomography to the study of panic disorder. *Am J Psychiatry* 1986; 143:469-477
7. Stewart RS, Devous MD, Rush AJ, et al: Cerebral blood flow changes during sodium-lactate-induced panic attacks. *Am J Psychiatry* 1988; 145:442-449
8. American Psychiatric Association: *Diagnostic and Statistical Manual of Mental Disorders, Third Ed, Revised*. Washington, DC, American Psychiatric Association, 1987
9. Liebowitz MR, Gorman JM, Fyer AJ, et al: Lactate provocation of panic attacks: II. biochemical and physiological findings. *Arch Gen Psychiatry* 1985; 42:709-719
10. Largent JW Jr, Smith RC, Calderon M, et al: Abnormalities of brain structure and density in schizophrenia. *Biol Psychiatry* 1984; 19:991-1013
11. Winer BJ: *Statistical Principles on Experimental Design*. New York, McGraw-Hill, 1962, pp 4-57
12. Crowe RR, Noyes R, Paulo OL, et al: A family study of panic disorder. *Arch Gen Psychiatry* 1983; 40:1065-1069
13. Post RM, Uhde TW: Anticonvulsants in nonepileptic psychosis, in *Aspects of Epilepsy and Psychiatry*. Edited by Bolwig TG, Trimble MR. Chichester, NY, Wiley, 1986, pp 177-212
14. Adamec RE, Stark-Adamec C: Limbic kindling and animal behavior implications for human psychopathology associated with complex partial seizures. *Biol Psychiatry* 1983; 18:269-292
15. Gorman JM, Uy U: Respiratory physiology and pathological anxiety. *Gen Hosp Psychiatry* 1987; 9:410-419
16. Uhde TW, Kellner CH: Cerebral ventricular size in panic disorder. *J Affect Disord* 1987; 12:175-178

Emotional Behavior After a Wada Test in a Patient With Secondary Mania

Sergio E. Starkstein, M.D.
 Marcelo L. Berthier, M.D.
 Pedro L. Lylyk, M.D.
 Alfredo Casasco, M.D.
 Robert G. Robinson, M.D.
 Ramon Leiguarda, M.D.

Soon after treatment of a right basotemporal vascular malformation using an embolization procedure, a 25-year-old patient developed an acute episode of mania. Two months later the patient was still manic, and a second embolization was scheduled. Before it was conducted, a Wada test was carried out to determine speech dominance. No changes in manic symptoms were observed after amytal injections into the left middle cerebral, right frontopolar, or right middle cerebral arteries. This finding suggests that secondary mania may not be the result of "release" of the left hemisphere following a right hemisphere lesion but instead may be related to specific disturbances within the right hemisphere.

(*The Journal of Neuropsychiatry and Clinical Neurosciences* 1989; 1:408-412)

The amytal test was introduced by Wada in order to determine hemisphere language dominance in patients who were to undergo neurosurgical procedures.¹ Milner et al.² later demonstrated that the amytal test was also suitable for assessing the risk of postoperative amnesia in patients undergoing unilateral temporal lobectomy.

The amytal test involves the injection of sodium amytal (75 mg to 200 mg) into the internal carotid artery. When injected into the speech-dominant hemisphere, the amytal induces a brief (usually lasting three to five minutes) global aphasia, amnesia for verbal material, and contralateral hemiplegia. Recent advances in catheterization

Received June 16, 1989; revised August 10, 1989; accepted August 21, 1989. From the Institute of Neurological Research "Dr. Raul Carrea," Buenos Aires, Argentina; the Department of Psychiatry and Behavioral Sciences, Johns Hopkins University School of Medicine, Baltimore, Md.; and the University of Buenos Aires, Buenos Aires, Argentina. Address reprint requests to Dr. Leiguarda, Instituto de Investigaciones Neurológicas "Dr. Raul Carrea," Ayacucho 2166, 1112 Buenos Aires, Argentina.

Copyright © 1989 American Psychiatric Press, Inc.

technique have made it possible to perform selective injections in small arterial branches using smaller amounts of amytal. This not only avoids the global hemispheric effects produced by the carotid injection but also allows the study of more circumscribed brain regions.

Emotional changes may frequently follow amytal injections. Terzian³ reported that a catastrophic reaction followed the injection of amytal in the left carotid of right-handed subjects, while amytal injection of the right carotid elicited euphoria.

Recent studies have suggested that the occurrence of manic symptoms following brain injury (secondary mania) may be the result of specific right hemisphere lesions.⁴⁻⁶ These lesions have frequently been located in limbic or limbic-connected structures.⁴⁻⁶ A positive family history of affective disorder or subcortical atrophy may provide important predisposing factors for the development of secondary mania.⁵⁻⁷ Some investigators have suggested that the presence of euphoria after right hemisphere lesions or right intracarotid amytal injection may result from the release of transcallosal inhibitory fibers.⁸ Thus, in the case of mania, a right hemisphere lesion, after releasing the left hemisphere from a tonic inhibition, would allow the "positive" tendencies of the left hemisphere to emerge.⁸

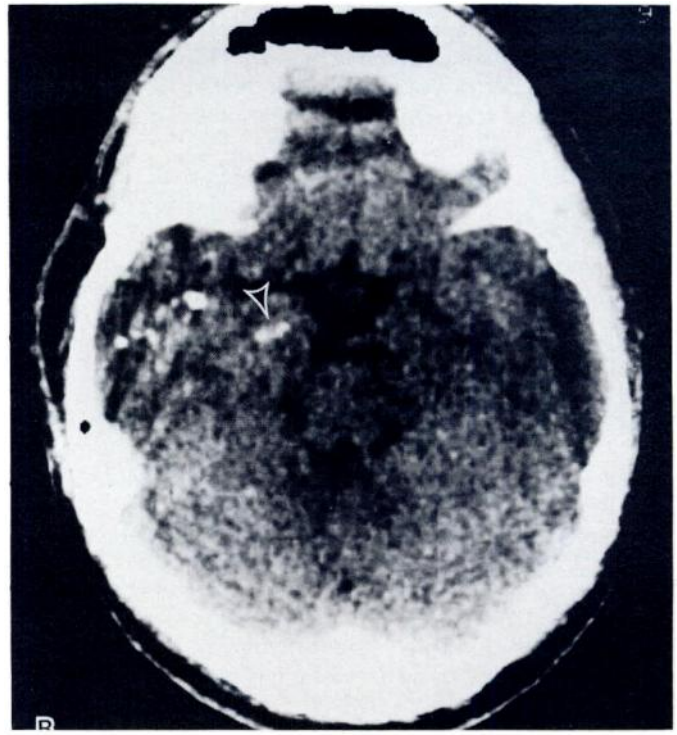
In the present study, we report the results of an amytal test performed on a patient who developed mania after undergoing an embolization procedure to correct a right basotemporal lobe vascular malformation. The hypothesis that mania may have resulted from a left hemisphere release phenomenon was explored.

CASE REPORT

The patient was a 25-year-old right-handed man (score of +100 on the Edinburgh Handedness Inventory⁹). Two years before his admission, he suffered frequent headaches, and a computerized tomography (CT) scan showed a vascular malformation involving the right basotemporal lobe. Six months before admission, the patient suffered a small bleed within the malformation but had no focal signs, and he was referred to our institute for therapeutic embolization. Before the procedure, a brief neuropsychological evaluation was conducted that showed no abnormalities in mental status or mood.

The embolization was carried out without complications, but, minutes later, a striking change in the patient's mood was observed. He became euphoric and very talkative, and he said that the surgical procedure changed his life. He reported that he was a "new person," and that this was the best moment of his life. A nonenhanced CT scan showed the presence of embolic material in the right basotemporal lobe (including the amygdala) (figure 1), and an enhanced CT showed the full extent of the vascular malformation (figure 2). No hemorrhagic lesions or ischemic infarctions were noted.

FIGURE 1. Nonenhanced CT scan showing embolic material within the right inferior temporal lobe. The arrow points to embolic material within the amygdala.



Eight weeks after the initial embolization, the patient continued to be euphoric, showing pressured speech, tangential thoughts, grandiose delusions, and hypersexuality. Although he had no personal history of psychiatric disorder, his family history was positive for bipolar affective disorder in his mother and her twin sister. Psychiatric evaluation using a structured interview (the modified Present State Exam¹⁰) elicited symptoms indicative of an organic affective disorder, manic type.¹¹ He scored in the manic range (18 points) on the Bech mania-rating scale.¹²

Because the embolization procedure only partially occluded the vascular malformation (figure 3), it was decided to repeat it. However, before conducting the new embolization procedure, the patient gave informed consent to a Wada test designed to determine speech dominance. The amytal test was carried out through transfemoral catheterization of the internal carotid artery. A control angiogram was done to determine the absence of an occlusion of the internal carotid artery or its major branches, and to rule out anomalous vessel patterns other than the malformation itself (for example, cross-filling of the contralateral anterior cerebral artery). A selective technique was used, involving catheterization of small arterial branches using a 5F catheter. Small dosages of diluted amytal (30 mg) were injected into each artery. The entire procedure was carried out under electroencephalograph (EEG) monitoring.

The patient was asked a series of questions before the first

CLINICAL AND RESEARCH REPORTS

amytal injection and after each subsequent injection. The questions were:

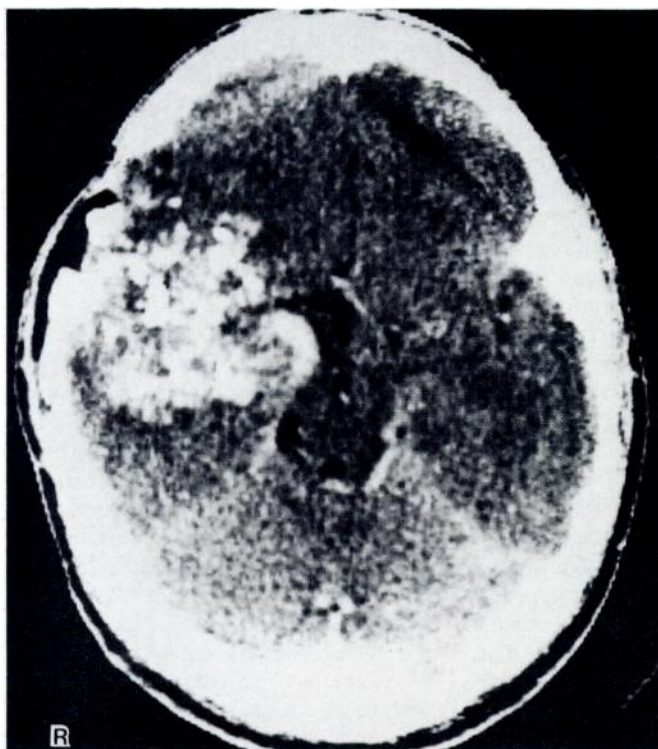
1. How are you feeling right now?
2. What was the happiest moment of your life?
3. What was the saddest moment of your life?
4. How would you feel if your father died?
5. How would you feel if you won the lottery?

Before the amytal injection, the patient gave the following answers:

1. "A great willingness to carry out this procedure."
2. "This one."
3. "When my aunt Adela died."
4. "I would aim at gaining my own independence, and I would think about growing as a man."
5. "I would like to help the most people I could."

The catheter was advanced into the M1 segment of the left middle cerebral artery (which was visualized with digital subtraction angiography), and 30 mg of diluted amytal were injected. During the first 13 seconds after the injection, the patient was globally aphasic and showed a right hemiplegia. He produced guttural sounds 57 seconds later and single words 2 minutes and 48 seconds after the injection. Normal verbal comprehension returned 3 minutes and 40 seconds

FIGURE 2. Enhanced CT scan showing the full extent of the vascular malformation

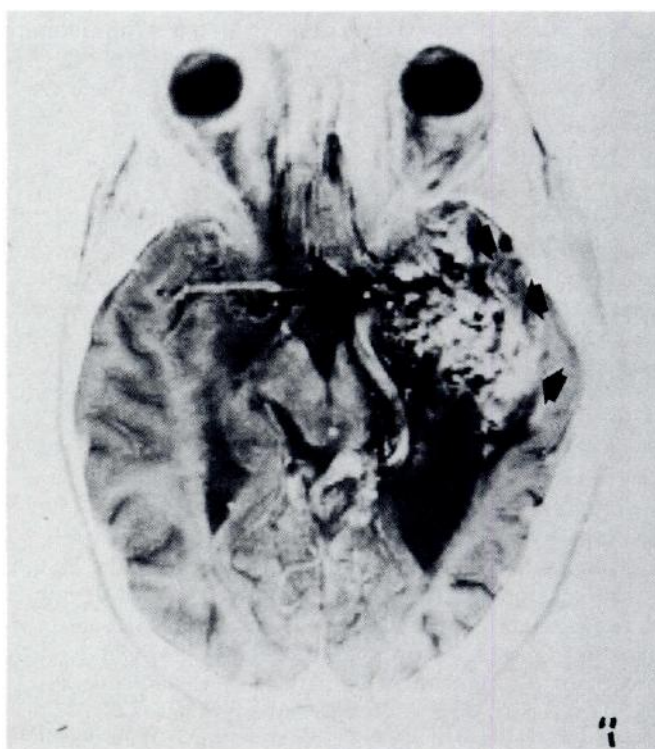


after the injection. Answers to the standardized questions in the minutes following the injection were as follows:

1. (4 minutes, 33 seconds, after the injection) "I am fine because I know you are here because of me. . . . What the hell is going on with me?" (he laughs) "I am mad about being like this. . . . I want to cooperate." (Note: patient was dysarthric.)
2. (4 minutes, 58 seconds, after the injection) "Good. . . . there were many...between those many...was in the villa I was...my mouth is burning! . . . in the year 1973 when I was 9 years old...but my family, my cousins, and all the people. . . . you all make me feel very happy."
3. (5 minutes, 58 seconds, after the injection) "The death of my aunt Adela, my cousin Bocha's mother...great cousin."
4. (6 minutes, 11 seconds, after the injection) "Look forward to growing in life in order to achieve a complete spirituality (sic) in every sense of life. . . . You guys! Make me speak properly because I am losing my patience!"
5. (6 minutes, 37 seconds, after the injection) "To grow...and to help lots of people...lots of people."

At 6 minutes, 54 seconds, the examiner asked the patient a sixth question, "How do you feel?" The patient responded, "I am fine because I know that through your questions you are helping me, and that implies the general and approximated

FIGURE 3. Axial magnetic resonance imaging scan (inverted T2-weighted technique) with arrows pointing to embolic material within the vascular malformation



healing...the complete healing of the angioma...and that is one of the most happiest moments in my life. . . . I hate speaking like this...because I did not expect this" (he laughs). "...As compared to all the cooperation I did with you in the first healing (sic), that was excellent."

After injection of amytal into the right frontopolar artery, the patient was asked the same series of questions. His responses were:

1. (9 seconds after the injection) "I feel great because I am surrounded by all of you."
2. (19 seconds after the injection) "I was thinking about that...there were so many...give me some time to think, and I will tell you. . . . I feel very safe by all of you. . . . I am full of strength, full of optimism because...the happiest of my life, I could almost say...the always incurable and unreachable angioma, with this type of things became curable and reachable, and that means settling down in life, to mature and grow..." (Note: the patient could not be interrupted.) "...to value life by what it is, isn't it?. . . . I could almost say this is my happiest moment, with an enormous happiness."
3. (1 minutes, 25 seconds, after the injection) "Sad...well...the saddest moment...well...sad, sad...no...none, none..."
4. (1 minute, 52 seconds, after the injection) "To look for independence in all the levels of life...and grow."
5. (2 minutes, 15 seconds, after the injection) "I could do several things...to invest in a safe place, but with the goal of helping lots of people, trying to produce a general wealth."

A right amytal injection into the M1 segment of the right middle cerebral artery was also carried out, but most of the injection material went into the malformation, and the patient's subsequent answers were similar to those obtained after the right frontopolar injection.

DISCUSSION

We presented a patient who developed mania immediately after therapeutic embolization for a right basotemporal arteriovenous malformation. A mental status examination completed before a second embolization procedure showed that the patient was elated. After an amytal injection into the left middle cerebral artery, the patient was elated and irritable, laughed inappropriately, and showed tangential thoughts and pressured speech. A right frontopolar amytal injection was followed by elation, grandiose delusions, tangential thoughts, and pressured speech.

Before making further comments on these findings, we should acknowledge the limitations of this study. The patient's euphoria could have disappeared during the period of global aphasia following amytal injection of the left middle cerebral artery and returned with the lan-

guage recovery. In previous studies, however, mood changes following left amytal injections were found after patients had recovered from the aphasia.³ Moreover, the most common mood change reported after a left carotid amytal injection—that is, the catastrophic reaction¹³—was not observed in our patient. Another limitation is that because we did not readminister the mania scale after each injection, we cannot be sure that the patient's mood did not change at all after the injections. Within the limitations of our methodology, however, the patient appeared to show the same degree of euphoria both before and after the injection.

Although the patient developed mania immediately after the right basotemporal embolization procedure, he also had a family history of bipolar disease, and the association between the embolization and the mood change could have occurred by chance alone. However, in a previous study we found a significant association between mania and lesions to limbic areas of the right hemisphere, including the right basotemporal cortex.⁶ In addition, we recently performed [¹⁸F]fluorodeoxyglucose positron emission tomography scans in three patients with secondary mania and subcortical lesions and found hypometabolism within the right basotemporal cortex in all three.¹⁴ Thus, we believe that the embolization and subsequent local damage to the right inferior temporal lobe played an important role in the production of secondary mania in this patient. As we suggested in a previous study,⁵ the genetic loading for bipolar illness may have played a facilitatory role.

One possible mechanism for the production of affective disorders after brain lesions is that damage of one hemisphere may "release" the contralateral hemisphere.⁸ Thus, secondary mania may be explained as the "release" of the "cheerful-prone" left hemisphere after a lesion of the "depression-prone" right hemisphere. According to this hypothesis, the amytal injection of our patient's left hemisphere should have briefly abolished his manic symptoms. Although it is possible that amytal injection within regions other than those supplied by the middle cerebral artery (MCA) (that is, anterior or posterior cerebral arteries) could have abolished the manic symptoms, the fact that MCA injection did not abolish them suggests that secondary mania may not be mediated by release of transcallosal inhibitory effects on the left hemisphere. In fact, in a previous study we reported that patients with left frontal lesions developed a depressed mood independent of the location or temporal sequence of a coexisting right hemisphere lesion.¹⁵

In conclusion, this case report is consistent with the hypothesis that secondary mania results from lesions in the limbic portions of the right hemisphere, and that secondary mania is not the result of a left hemisphere

CLINICAL AND RESEARCH REPORTS

"release," but is related to dysfunction of limbic regions within the right hemisphere.

This work was supported in part by grants from the National Institutes of Health (Research Scientist Award MH00163 to Dr. Robinson, MH40355, and NS15080); from the University of Buenos Aires to Dr. Starkstein; and from the Instituto Di Tella to Dr. Berthier.

References

1. Wada J: A new method for determining the side of cerebral dominance: a preliminary report of the intra-carotid injection of sodium amytal in man. *Igaku Seibutsugaki (Medicine and Biology)* 1949;14:221-222
2. Milner B, Branch C, Rasmussen T: Study of short-term memory after intracarotid injection of sodium amytal. *Trans Am Neurol Assoc* 1962;87:224-226
3. Terzian H: Behavioral and EEG effects of intracarotid sodium amytal injection. *Acta Neurochir* 1964;12:230-239
4. Cummings JL, Mendez MF: Secondary mania with focal cerebrovascular lesions. *Am J Psychiatry* 1984; 141:1084-1087
5. Robinson RG, Boston JD, Starkstein SE, et al: Comparison of mania and depression after brain injury: causal factors. *Am J Psychiatry* 1988; 145:172-178
6. Starkstein SE, Boston JD, Robinson RG: Mechanism of mania after brain injury: 12 case reports and review of the literature. *J Nerv Ment Dis* 1988; 176:87-100
7. Starkstein SE, Pearlson GD, Boston GD, et al: Mania after brain injury: a controlled study of causative factors. *Arch Neurol* 1987; 44:1069-1073
8. Flor-Henry P: On certain aspects of the localization of the cerebral systems regulating and determining emotion. *Biol Psychiatry* 1979; 14:677-698
9. Oldfield RC: The assessment and analysis of handedness: the Edinburgh inventory. *Neuropsychologia* 1971; 9:97-113
10. Wing JK, Cooper JK, Sartorius N: *Measurements and Classification of Psychiatric Symptoms*. New York, Cambridge University Press, 1974, pp 189-228
11. American Psychiatric Association: *Diagnostic and Statistical Manual of Mental Disorders, Third Ed, Revised*. Washington, DC, American Psychiatric Association, 1987
12. Bech P, Kastrup M, Rafaelsen OJ: Mini-compendium of rating scales for states of anxiety, depression, mania, schizophrenia, with corresponding *DSM-III* syndromes. *Acta Psychiatr Scand* 1986; 73(S236):29-31
13. Perria L, Rossadini G, Rossi GF: Determination of side of cerebral dominance with amobarbital. *Arch Neurol* 1961; 4:173-181
14. Starkstein SE, Mayberg HS, Robinson RG, et al. Focal PET scan abnormalities in secondary mania (presented at the 142nd Annual Meeting of the American Psychiatric Association, May 6-11, 1989, San Francisco, California), in 1989 CME Syllabus and Proceedings Summary. Washington, DC, American Psychiatric Association, 1989, p 85
15. Lipsey JR, Robinson RG, Pearlson GD, et al: Mood change following bilateral hemisphere brain injury. *Br J Psychiatry* 1983; 143:266-273