

Illustrative Teaching Case

Section Editors: Daniel Strbian, MD, PhD, and Sophia Sundararajan, MD, PhD

Young Patient With Isolated Tongue Deviation

Karoliina Aarnio, MD; Mika Leppä, MD; Juha Martola, MD, PhD;
Sophia Sundararajan, MD, PhD; Daniel Strbian, MD, PhD

Case Description

We describe a case of a 40-year-old white man with a history of transient idiopathic thrombocytopenia. He had no regular medication and worked as a lifeguard. His cholesterol levels were slightly elevated and he smoked 7 cigarillos a day. He did not have a history of obvious head or neck trauma but used to practice martial arts. In his family history, his mother had a cerebral infarction in her 60s.

Four days before admission to our emergency room he realized he could not move his tongue to the left side while chewing bread. He visited his primary care physician, who suspected angioedema and prescribed him prednisolone. The medication did not alleviate the symptoms and he gradually developed dysarthria and slight subjective difficulty swallowing food because of difficulty moving his tongue. A few days later the patient went again to see the same physician. He was then sent to a tertiary care unit where an ENT specialist examined the patient and performed endoscopy of the nose, pharynx, and larynx. No peripheral reason for the symptoms was found and he was referred to the neurologist. During clinical examination, the patient had difficulty moving his tongue to the left on protrusion, mild atrophy on the left side of the tongue, and slight dysarthria. A hypoglossal nerve lesion was suspected. He also had subjective feelings of dysphagia. The neurological examination was otherwise normal. He had no cervical lymphadenopathy or fasciculations of the tongue. MRI of the brain showed old infarctions in the right cerebellum. The brain stem, basal ganglia, liquor spaces, and gray matter were normal. There was no mechanical compression found of the hypoglossal nerve in the brain MRI. The chest radiograph was normal. The laboratory tests including blood count, routine coagulation markers, electrolytes, and creatinine were normal. Thereafter, a MR angiography was performed. What do you expect to be the finding?

Answer

MR angiography of the neck (Figure) showed dolichoectasia of the left internal carotid artery near the hypoglossal canal, which was a sequela of an older dissection according to the neuroradiologist. This 9-mm dilatation (compared with 4 mm of the normal vessel wall) could have caused hypoglossal

nerve compression and the symptoms. The slight dysarthria and dysphagia were caused by impaired motor function of the tongue.

According to our written institutional guidelines, we start warfarin in patients with acute carotid dissections; however, because of the chronic nature of the dissection in this case, warfarin was not started. Of note, because of the old cerebellar infarcts, cardiologist was consulted and no source of cardio-genic emboli was found on transesophageal echocardiography. Patent foramen ovale was not detected. A 48-hour ECG was normal. No thrombophilia was detected. Routine secondary preventive medications were prescribed, including aspirin, dipyridamole, simvastatin, and enalapril.

A speech therapist checked for swallowing disturbances. According to the report the patient did not actually have dysphagia, but difficulties eating as a result of impaired movements of the tongue. The dysarthria almost completely resolved during the hospitalization. He was discharged with a recommendation to avoid sudden movements of the head and neck and to quit smoking. A follow-up visit was appointed.

Discussion

Solitary hypoglossal nerve (cranial nerve XII) palsy is relatively uncommon. The 12th cranial nerve emerges from the medulla between the ventrolateral sulcus, the olive, and the pyramids and exits the cranium through the hypoglossal foramen in the posterior cranial fossa. It passes downward near the inferior ganglion of the vagus to lie between the internal carotid artery and the internal jugular vein. The nerve then courses laterally to the bifurcation of the common carotid artery and loops above the hyoid bone before going ventrally to supply the muscles of the tongue.¹ The hypoglossal nerve is purely motor. It innervates the genioglossus, hyoglossus, styloglossus (extrinsic muscles), and the intrinsic muscles of the tongue, as well as the lower hyoid group of muscles by ansa cervicalis.

The genioglossus muscle forms the main bulk of the tongue. The hypoglossus muscle is a thin, flat, quadrilateral muscle and the styloglossus muscle interdigitates with the hyoglossus muscle. The extrinsic palatoglossus muscle is the only tongue muscle, which is innervated by the vagus nerve.

Received August 25, 2014; final revision received August 25, 2014; accepted August 25, 2014.

From the Department of Neurology (K.A., M.L., D.S.) and Helsinki Medical Imaging Center (J.M.), Helsinki University Central Hospital, Helsinki, Finland; and Department of Neurology, Stroke Unit University Hospitals of Cleveland/Case Medical Center, OH (S.S.).

Correspondence to Karoliina Aarnio, MD, Department of Neurology, Helsinki University Central Hospital, Haartmaninkatu 4, 00290 Helsinki, Finland. E-mail karoliina.aarnio@hus.fi

(*Stroke*. 2014;45:e226-e228.)

© 2014 American Heart Association, Inc.

Stroke is available at <http://stroke.ahajournals.org>

DOI: 10.1161/STROKEAHA.114.006701

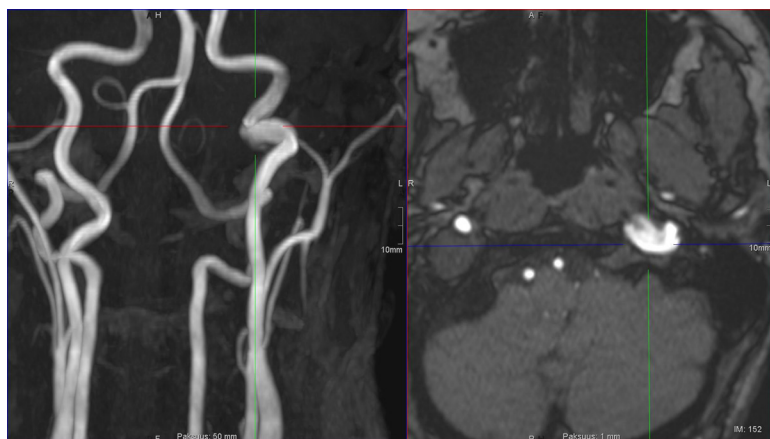


Figure. MR angiography of the neck. Dolichoectasia (9 mm) of the left internal carotid artery near the hypoglossal canal.

The paired extrinsic muscles are attached to the surrounding structures. The ansa hypoglossi, which innervates the infrahyoid strap muscles, is constituted from C-1 fibers and the hypoglossal nerve.²

Lesions of the hypoglossal nerve can be divided into supranuclear, nuclear, and infranuclear according to the lesion site. To protrude the tongue in the midline, a balanced action of both genioglossus muscles is required. A supranuclear palsy will cause motor dysfunction contralateral to the side of the lesion without atrophy or fasciculations. The tongue will deviate away from the side of the lesion. Nuclear or infranuclear lesions cause difficulty moving the tongue ipsilaterally, and later, unilateral muscle atrophy and even fasciculations may occur, which may cause dysarthria. If innervation of the infrahyoid strap muscles is involved, the disease can be localized to the segments of the hypoglossal nerve distal to the point at which it is joined by the C1-fibers.²

The nuclear and infranuclear hypoglossal nerve can be divided into 5 segments to help, which provide clues not only to localization but also aid in determining the likely pathogenesis. These segments are the medullary, cisternal, skull base, nasopharyngeal/oropharyngeal carotid space, and sublingual segments. Each segment is associated with a distinct set of likely pathologies. For example, the carotid space segment is associated with primary cancers, metastasis, and vessel dissection. Both computed tomography and MRI are useful in assessing structural lesions such as these that may compress the 12th cranial nerve.²

According to a study of 100 cases with 12th nerve palsy, nearly half of the cases were caused by cancer (49%), 12% were caused by trauma, and only 6% by stroke. Other reasons for hypoglossal nerve dysfunction were multiple sclerosis (6%), surgery (5%), Guillain-Barré neuropathy (4%), and infection (4%).³ In another study, 2 of 7 patients with hypoglossal nerve palsy and suspected tongue-base masses had internal carotid artery dissection (ICAD).⁴

Cervical artery dissection is an underlying cause of stroke in young patients in 16% of cases, of which nearly half are caused by ICAD.⁵ Dissections arise, with or without obvious head or neck trauma, from an intimal tear that allows

arterial blood under pressure to enter the arterial wall and form an intramural hematoma. This space is also known as the false lumen.⁶ Dissection of the internal carotid artery typically presents as pain on 1 side of the head, face, or neck accompanied by partial Horner syndrome and followed by late cerebral or retinal ischemia. This classical triad is present in <50% of ICAD cases.⁷ Most patients have ≥ 2 of these symptoms, but dissection can occur with only 1 or none of these obvious symptoms. In a study, the 12th cranial nerve was affected in >5% of all patients with ICAD making it the most affected cranial nerve.⁸ Less than 5% of patients with ICAD had isolated cranial nerve findings, whereas 12% of patients had ≥ 1 cranial nerve deficits.⁸ Isolated hypoglossal nerve deficit, without any other findings as the only presentation of ICAD is rare.^{8,9} There are no randomized clinical trials of treatment of ICAD to date, but anticoagulation for 3 to 6 months has been accepted treatment historically,⁷ although more recent data suggest no difference between the 2 options.¹⁰ Most dissections heal spontaneously, and surgical or endovascular treatment should be reserved for patients who have worsening symptoms of ischemia despite adequate anticoagulation.⁶ The long-term prognosis of ICAD is relatively good with a 16-year cumulative risk of death of only 3.0% (95% confidence interval, 0–6.9) and the average annual rate for mortality is only 0.2%.⁶

TAKE-HOME POINTS

- Isolated hypoglossal nerve palsy has many possible pathophysiologies including tumor, trauma, sequelae of arterial dissection, infection, multiple sclerosis, and surgery.
- Treatment of the 12th nerve palsy is focused on the underlying pathophysiology.
- Internal carotid artery dissection may occur without obvious head trauma and should be ruled out in young adults presenting with hypoglossal nerve palsy.

Disclosures

None.

References

1. Brannagan TH, Weimer LH. The hypoglossal nerve (cranial nerve XII). In: Rowland LP, Pedley TA, eds. *Merritt's Neurology*. 12th ed. Philadelphia, PA: Lippincott Williams & Wilkins; 2010:510.
2. Thompson EO, Smoker WR. Hypoglossal nerve palsy: a segmental approach. *Radiographics*. 1994;14:939–958.
3. Keane JR. Twelfth-nerve palsy. Analysis of 100 cases. *Arch Neurol*. 1996;53:561–566.
4. Learned KO, Thaler ER, O'Malley BW Jr, Grady MS, Loevner LA. Hypoglossal nerve palsy missed and misinterpreted: the hidden skull base. *J Comput Assist Tomogr*. 2012;36:718–724.
5. Aarnio K, Haapaniemi E, Melkas S, Kaste M, Tatlisumak T, Putaala J. Long-term mortality after first-ever and recurrent stroke in young adults. *Stroke*. 2014;45:2670–2676.
6. Schievink WI. Spontaneous dissection of the carotid and vertebral arteries. *N Engl J Med*. 2001;344:898–906.
7. Steinke W, Rautenberg W, Schwartz A, Hennerici M. Noninvasive monitoring of internal carotid artery dissection. *Stroke*. 1994;25:998–1005.
8. Mokri B, Silbert PL, Schievink WI, Piepgras DG. Cranial nerve palsy in spontaneous dissection of the extracranial internal carotid artery. *Neurology*. 1996;46:356–359.
9. Lindsay FW, Mullin D, Keefe MA. Subacute hypoglossal nerve paresis with internal carotid artery dissection. *Laryngoscope*. 2003;113:1530–1533.
10. Kennedy F, Lanfranconi S, Hicks C, Reid J, Gompertz P, Price C, et al; CADISS Investigators. Antiplatelets vs anticoagulation for dissection: CADISS nonrandomized arm and meta-analysis. *Neurology*. 2012;79:686–689.

KEY WORD: carotid arteries

Young Patient With Isolated Tongue Deviation

Karoliina Aarnio, Mika Leppä, Juha Martola, Sophia Sundararajan and Daniel Strbian

Stroke. 2014;45:e226-e228; originally published online September 11, 2014;
doi: 10.1161/STROKEAHA.114.006701

Stroke is published by the American Heart Association, 7272 Greenville Avenue, Dallas, TX 75231
Copyright © 2014 American Heart Association, Inc. All rights reserved.

Print ISSN: 0039-2499. Online ISSN: 1524-4628

The online version of this article, along with updated information and services, is located on the
World Wide Web at:

<http://stroke.ahajournals.org/content/45/11/e226>

Permissions: Requests for permissions to reproduce figures, tables, or portions of articles originally published in *Stroke* can be obtained via RightsLink, a service of the Copyright Clearance Center, not the Editorial Office. Once the online version of the published article for which permission is being requested is located, click Request Permissions in the middle column of the Web page under Services. Further information about this process is available in the [Permissions and Rights Question and Answer](#) document.

Reprints: Information about reprints can be found online at:
<http://www.lww.com/reprints>

Subscriptions: Information about subscribing to *Stroke* is online at:
<http://stroke.ahajournals.org/subscriptions/>