

---

# Case Report

---

## Neurofibromatosis Type 1 Associated with Vertebrobasilar Dolichoectasia and Pontine Ischemic Stroke

Nadia Mariagrazia Giannantoni, MD, Aldobrando Broccolini, MD, PhD, Giovanni Frisullo, MD, PhD, Fabio Pilato, MD, PhD, Paolo Profice, MD, Roberta Morosetti, MD, PhD, Giuseppe Di Lella, MD, Giuseppe Zampino, MD, Giacomo Della Marca, MD, PhD

From the Institute of Neurology, Catholic University, Rome, Italy (NMG, AB, GF, FP, PP, RM, GDM); Department of Bioimaging and Radiological Sciences, Catholic University, Rome, Italy (GDL); and Department of Pediatrics, Catholic University, Rome, Italy (GZ).

---

### ABSTRACT

Neurofibromatosis type 1 (NF1) is a heterogeneous, common, neurocutaneous disorder presenting different complications during a life span, including cerebrovascular dysplasia. To our knowledge this is the first reported case of NF1 associated with vertebrobasilar dolichoectasia and pontine ischemic stroke. We describe a 57-year-old man with NF1 who presented an acute onset right-sided facial palsy and hemiplegia, dysarthria, and gait imbalance. Magnetic resonance imaging showed an acute left paramedian pontine infarct and a hypoplastic right vertebral artery. Brain Computed Tomography Angiography revealed the occurrence of vertebrobasilar dolichoectasia. Co-occurrence of VBD and NF1 might not be merely casual and it may significantly heighten the mortality rate in this multisystem disorder. We suggest a possible role of VBD in the genesis of our patient's clinical-radiological features and prompt the early detection of asymptomatic arteriopathy in individuals with NF1 in order to ameliorate patients' quality of life and life expectancy.

**Keywords:** Neurofibromatosis, vertebrobasilar dolichoectasia, stroke.

**Acceptance:** Received March 3, 2014, and in revised form May 14, 2014. Accepted for publication May 25, 2014.

**Correspondence:** Address correspondence to Nadia Mariagrazia Giannantoni, Institute of Neurology, Catholic University, Rome, Italy, Policlinico Universitario "A. Gemelli" L.go A. Gemelli, 8-00168 Rome, Italy. E-mail: nadia.giannantoni@gmail.com.

J Neuroimaging 2015;25:505-506.  
DOI: 10.1111/jon.12160

### Case Report

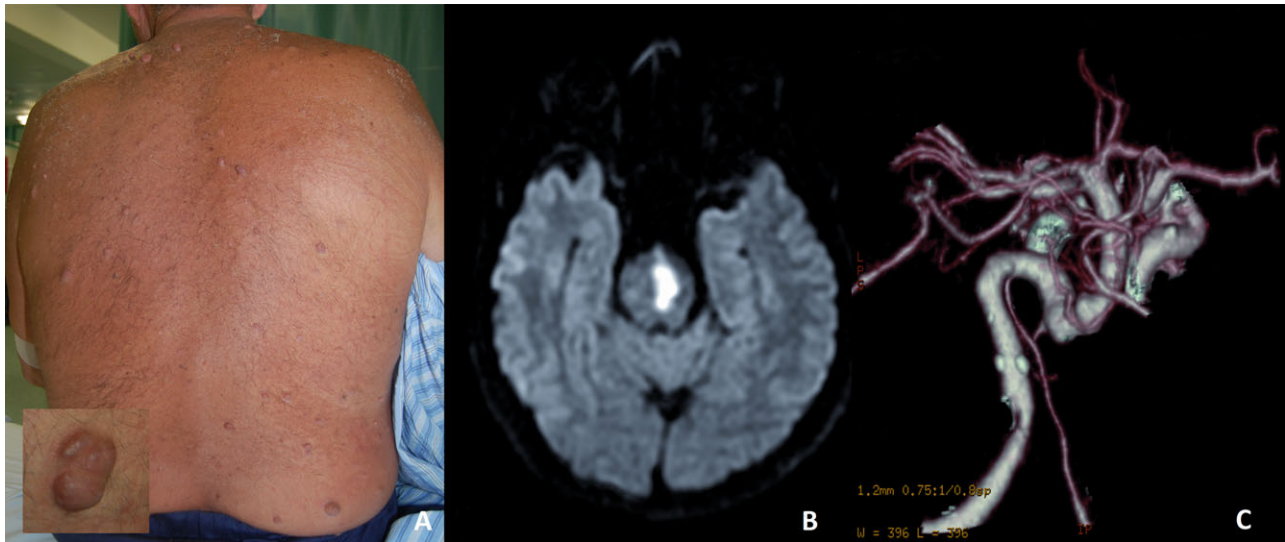
Neurofibromatosis type 1 (NF1) is a common heterogeneous and progressive neurocutaneous disorder with an autosomal dominant inheritance and an incidence of 1 in 3,500 live births, presenting different complications during a life span. It is caused by a loss of function mutation in a histogenesis control gene on chromosome 17q11.2 that codes for the neurofibromin tumor suppressor protein, ubiquitously expressed in the nervous system and in the endothelial and smooth muscle cells of blood vessels, which ultimately leads to increased cellular proliferation, differentiation and to impairment of vascular maintenance and repair.<sup>1</sup>

We describe a Caucasian 57-year-old man who presented an acute onset right-sided facial palsy and hemiplegia, dysarthria, and gait imbalance. No other pathologies were reported with the exception of a recent diagnosis of hypertension. On anamnesis his mother was supposedly mildly affected by NF1 but has never had a formal diagnosis. Physical examination revealed multiple cutaneous neurofibromas (Fig 1A), axillary and groin freckling and some café au lait macules; thus a diagnosis of NF1 was clinically made, fulfilling three of the major criteria required by NIH consensus development conference 1988.<sup>1</sup> Magnetic resonance imaging was performed with T2, fluid-attenuated-inversion-recovery, T1, Fast Spin Echo, Gradient Echo, Diffusion Weighted Imaging (DWI), and angiographic

sequences (Angio-MRI) showing a left paramedian pontine infarct on DWI (Fig 1B) and an hypoplastic right vertebral artery on Angio-MRI. Brain Computed Tomography Angiography (Angio-CT) revealed the occurrence of vertebrobasilar dolichoectasia (VBD) (Fig 1C). Extracranial and intracranial echo-color Doppler showed the absence of other relevant findings in the carotid system. After 5 days of hospitalization, the patient was dismissed and an oral antiplatelet therapy at low doses was started. At a 4 month follow-up a complete remission of his symptoms was observed.

To the best of our knowledge, in literature there are 2 patients that were reported to have an association between VBD and NF1, but none of the two had a well-defined pontine ischemic stroke as our patient did.<sup>2,3</sup> In addition, our patient did not have documented stenotic lesions involving the carotid axis, unlike the previously described case reports.

Moreover, even though vasculopathy in NF1 is multifocal, patchy, and frequently asymptomatic, it mostly affects the kidneys and the brain and it seldom involves vertebral and basilar arteries causing dolichoectasia. Certainly, taking into account that cerebrovascular dysplasia commonly implicates stenotic lesions in the carotid axis, including the internal carotid artery (44%), the middle cerebral artery (19.3%), the anterior cerebral artery (16.4%), and the posterior cerebral artery (8.2%), and that these frequently underestimated lesions might lead to potential



**Fig 1.** (A) Back image of our patient with familiarity for NF1 displays multiple, soft skin-colored nodules hence fulfilling the criteria set by the NIH consensus development conference. A detail of a cutaneous neurofibroma is evident in the lower left corner. (B) Magnetic Resonance Diffusion-Weighted Imaging (DWI) shows a left hyperintense signal in the paramedian pontine consistent with an acute ischemic stroke. (C) Three-dimensional CT (3-D-CT) angiography of the intracranial circulation exhibits a clearly visible vertebrobasilar dolichoectasia.

life-threatening sequelae, an early disclosure of these vascular complications in patients with NF1 should be encouraged.<sup>4</sup>

A possible role of VBD in the genesis of our patient's clinical-radiological features can be easily hypothesized given that VBD is a relatively rare multifactorial, systemic, and advancing intracranial condition, consequent to functional and structural impairments of large vessels' connective tissue, that may produce a wide clinical scenario at the expense of medulla and pons, including posterior circulation stroke and cranial nerve disorders. In particular, we speculate that the finding of VBD in our patient might be an unusual symptomatic manifestation of the large spectrum of vascular abnormalities caused by NF1; hence the rare co-occurrence of these two uncommon conditions might be causal rather than casual, supposedly sharing the same pathogenesis.<sup>5</sup>

To conclude, VBD may significantly heighten the mortality rate in NF1, especially considering the frequent thrombus recurrence in this vascular condition. Since the incidence of ischemic stroke and arterial dolichoectasia might be higher than expected in patients with NF1 vascular dysplasia, routine vas-

cular screening for these patients should be considered. Indeed, early detection of asymptomatic arteriopathy by thorough neuroimaging surveillance in individuals with NF1, a relatively common and high-risk genetic disorder, may impact patients' quality of life and life expectancy.

## References

1. Ferner RE, Huson SM, Thomas N, et al. Guidelines for the diagnosis and management of individuals with neurofibromatosis 1. *J Med Genet* 2007;44:81-88.
2. De Pablo-Fernández E, Correas-Callero E, Sierra-Hidalgo F, et al. Hemifacial spasm, vertebrobasilar dolichoectasia and neurofibromatosis type 1. *J Clin Neurosci* 2012;19(7):1046-1047.
3. Papapetropoulos S, Argyriou AA, Guevara A, et al. Hemifacial spasm and pontine compression caused by a giant vertebrobasilar dolichoectasia. *Cerebrovasc Dis* 2009;27(4):413-414.
4. Cairns AG, North KN. Cerebrovascular dysplasia in neurofibromatosis type 1. *J Neurol Neurosurg Psychiatry* 2008;79:1165-1170.
5. Lou M, Caplan LR. Vertebrobasilar dilatative arteriopathy (dolichoectasia). *Ann N Y Acad Sci* 2010;1184:121-133.

Copyright of Journal of Neuroimaging is the property of Wiley-Blackwell and its content may not be copied or emailed to multiple sites or posted to a listserv without the copyright holder's express written permission. However, users may print, download, or email articles for individual use.