



Clinical Observations

Cerebrospinal Fluid Oxidative Stress Marker Levels and Cytokine Concentrations in a Neonate With Incontinentia Pigmenti



Natsuki Ohkawa MD^a, Akihisa Okumura MD, PhD^{b,c,*}, Rie Miyata MD, PhD^d, Naoyuki Tanuma MD, PhD^d, Masaharu Hayashi MD, PhD^d, Hiroaki Sato MD^a, Toshiaki Shimizu MD, PhD^b

^a Neonatal Intensive Care Unit, Juntendo Shizuoka Hospital, Izunokuni, Japan

^b Department of Pediatrics, Faculty of Medicine, Juntendo University, Tokyo, Japan

^c Department of Pediatrics, Aichi Medical University, Nagakute, Japan

^d Department of Brain Development and Neural Regeneration, Tokyo Metropolitan Institute of Medical Science, Tokyo, Japan

ABSTRACT

BACKGROUND: Some children with incontinentia pigmenti exhibit encephalopathic features with severe seizures and disturbed consciousness, from the neonatal through the early infantile period. However, the pathological mechanism of brain lesion development is not fully understood. **METHODS:** We measured the cerebrospinal fluid levels of cytokines and oxidative stress markers (8-hydroxy-2-deoxyguanosine and the hexanoyl-lysine adduct) in a young girl with incontinentia pigmenti complicated by an encephalopathic event that occurred on her first day of life. Magnetic resonance imaging revealed widespread reduction of water diffusion in the basal ganglia, the periventricular and subcortical white matter, and the corpus callosum. **RESULTS:** Oxidative stress markers were elevated at 4 days of age but decreased mildly by 25 days of age. Elevated levels of soluble tumor necrosis factor receptor 1 were observed at both 4 and 25 days of age, although tumor necrosis factor- α levels were below the limit of detection. No other cytokine levels were elevated, except for those of interleukin-10 at 25 days of age. **CONCLUSIONS:** Tumor necrosis factor- α expression and oxidative stress are involved in the pathogenesis of brain lesions in children with incontinentia pigmenti, and elevated cerebrospinal fluid cytokine levels may not be apparent during encephalopathic events.

Keywords: incontinentia pigmenti, cytokines, 8-hydroxy-2-deoxyguanosine, hexanoyl-lysine adduct, soluble tumor necrosis factor receptor 1

Pediatr Neurol 2014; 51: 737-740

© 2014 Elsevier Inc. All rights reserved.

Introduction

Incontinentia pigmenti (IP) is a rare neurocutaneous syndrome characterized by skin lesions and disorders of various organs including the central nervous system (CNS), eyes, teeth, and hair. IP is caused by mutation of the *NEMO* (nuclear factor- κ B [NF- κ B] essential modulator) gene,¹ which is required for the activation of NF- κ B. One third of

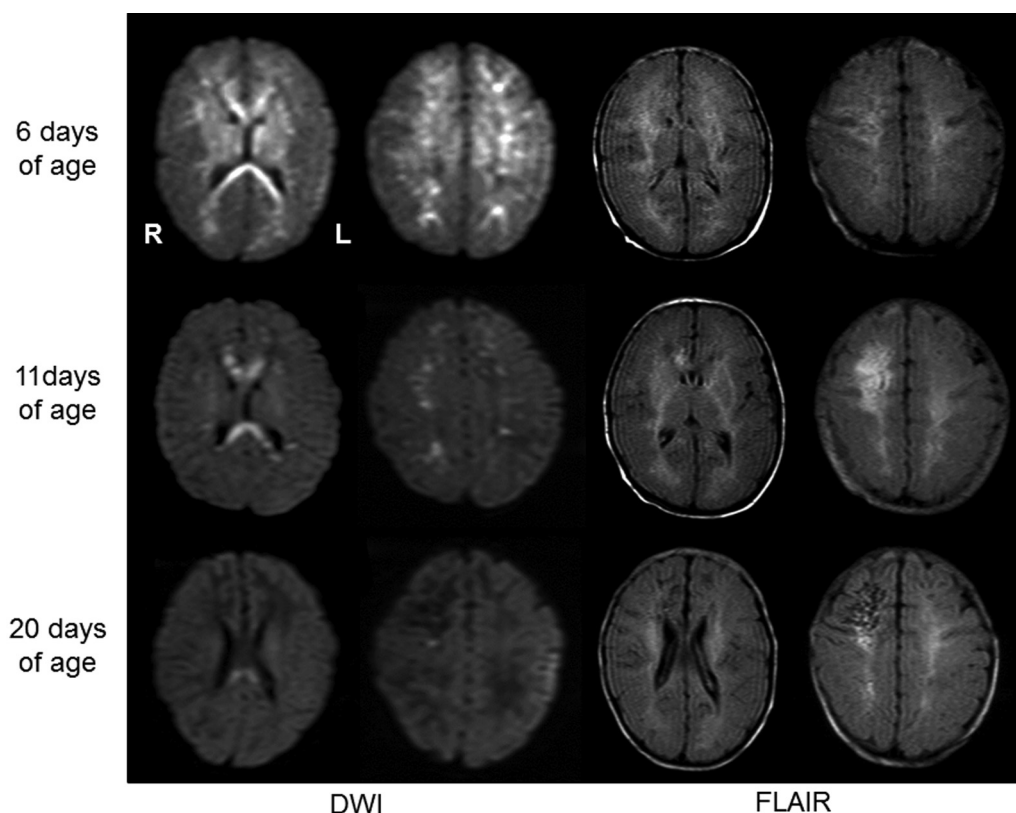
the patients with IP exhibit CNS dysfunction. Several authors have reported disturbed consciousness and encephalopathic manifestations with severe seizures in IP patients from the neonatal through the early infantile period.²⁻⁷ However, the pathogenic mechanisms triggering brain lesions in IP patients remain poorly understood. Several studies have suggested that cytokines may contribute to the pathogenesis of acute encephalopathies in children.⁸⁻¹⁰ As regulation of cytokine levels in infants with IP is presumed to be different from that in normal infants, analysis of cytokine levels might yield crucial information on the pathogenesis of brain lesions. Our previous studies suggested that children with acute encephalopathy were exposed to oxidative stress.¹¹ We postulated that such oxidative stress might be associated with the pathogenesis

Article History:

Received April 8, 2014; Accepted in final form July 17, 2014

* Communications should be addressed to: Dr. Okumura; Department of Pediatrics; Aichi Medical University; 1-1 Yazako Karimata; Nagakute, Aichi 480-1195, Japan.

E-mail address: okumura.akhisa.479@mail.aichi-med-u.ac.jp

**FIGURE.**

MRI findings. Top: MRI at 6 days of age. Increased signal intensities in the basal ganglia, periventricular and subcortical white matter, and corpus callosum were evident on DWI. FLAIR images illustrated lesions in the periventricular and subcortical white matter. Middle: MRI at 11 days of age. The extent of diffusion abnormalities was reduced, but high-intensity areas evident on FLAIR images became wider and more intense. Bottom. MRI at 20 days of age. High-intensity regions on DWI had disappeared, except in the splenium of the corpus callosum. FLAIR images revealed curvilinear low-intensity areas in the subcortical white matter, predominantly in the right frontal lobe. DWI = Diffusion-weighted images; FLAIR = Fluid-attenuated inversion-recovery; MRI = Magnetic resonance imaging.

of brain lesions in IP infants. To explore this idea, we measured the levels of cytokines and oxidative stress markers in the cerebrospinal fluid (CSF) of a neonate with IP during an encephalopathic event.

Patient Description

This girl was born at 39 weeks gestation via spontaneous delivery to a 27-year-old mother with IP. The pregnancy was uneventful. Our patient had two sisters, one of whom had IP. Characteristic skin lesions developed on the trunk and lower extremities on the third day of life. First, erythematous skin lesions were evident and then vesicles appeared. A diagnosis of IP was confirmed by skin biopsy performed at 20 days of age.

At 12 hours of age, she manifested a seizure with apnea, cyanosis, left eye deviation, and jerking of the arms. She was admitted to our hospital at 4 days of age because her seizures had become frequent. On admission, she was mildly stuporous and sometimes irritable. Physical examination was unremarkable except for the presence of erythema and vesicles on the limbs and trunk. Initial hematological and chemical workup data were normal, except that eosinophilia was noted (an eosinophil count of 5822 cells/mm^3 ; 17% of all leukocytes). CSF examination recorded cells at 5 cells/mm^3 , a protein level of 141 mg/dL and a glucose level of 62 mg/dL. Cranial ultrasonography revealed no abnormality. Electroencephalography performed at 8 days of age revealed multifocal paroxysmal discharges in both hemispheres. We prescribed IV infusion of phenobarbital and midazolam. The seizures disappeared by 7 days of age, and antiepileptic drugs were discontinued on day 9.

Magnetic resonance imaging (MRI) performed at 6 days of age revealed increased signal intensities of the basal ganglia, the periventricular and subcortical white matter, and the corpus callosum (Figure) on diffusion-weighted images (DWIs). On fluid-attenuated inversion-recovery (FLAIR) images, the periventricular and subcortical white matter exhibited abnormally high intensities. The extent of abnormalities revealed on DWIs was reduced on day 11, but the abnormally high intensities evident on FLAIR images expanded and became more intense (Figure). Increased signal intensities were also observed in the internal and external capsules. At 20 days of age, the DWI abnormalities had disappeared, except for those in the splenium of the corpus callosum. FLAIR images exhibited curvilinear low-intensity areas in the subcortical white matter, predominantly in the right frontal lobe (Figure).

She exhibited delayed psychomotor development. At the last follow-up (at 48 months of age), she could speak only simple two-word sentences. She exhibited spasticity (predominantly in the lower extremities) and could walk only with support. No epileptic seizures were observed after discharge.

The levels of CSF cytokines and oxidative stress markers

The levels of the nucleoside oxidative stress marker, 8-hydroxy-2-deoxyguanosine (8-OHdG), and the early-stage lipid peroxidation marker, hexanoyl-lysine adduct (HEL), were measured using ELISA kits (Japan Institute for the Aging, Shizuoka, Japan) and a Model 680 plate reader (Bio-Rad Laboratories, Burlingame, CA). Cytokine levels were measured using a multiplex bead-based assay (BioPlex 200 system; Bio-Rad Laboratories). The levels of soluble tumor necrosis factor- α

receptor 1 (sTNFR1) were determined via ELISA (Mitsubishi Chemical Medience Corp, Tokyo, Japan). Detection cutoff levels were determined by running control dilutions of each marker. CSF samples were obtained in the morning. They were immediately frozen and stored in a -80°C freezer until the measurement. All samples were assayed at the same time. The control CSF samples were obtained in seven normal controls with acute viral infections, lacking neurological abnormalities such as seizures; subjects were aged from 1 month–2 years. Parental consent was obtained, and all protocols were approved by the Institutional Ethics Committee of the Tokyo Metropolitan Institute of Neuroscience.

CSF biomarker data are summarized in Table. The levels of the oxidative stress markers 8-OHdG and HEL were elevated at 10 days of age, and although they fell slightly at 25 days of age, the levels remained above the cutoff values. Elevated levels of sTNFR1 were observed at both 4 and 25 days of age, although tumor necrosis factor- α (TNF- α) levels were below the cutoff. No other cytokine exhibited an abnormally high level, except for interleukin (IL)-10 at 25 days of age.

Discussion

The pathogenic mechanism triggering brain lesions in IP patients remains poorly understood. Several mechanisms have been suggested, including destructive,² vascular,^{3,6} and inflammatory mechanisms.¹² In terms of IP dermatosis, a hypothetical sequence of events has been proposed from analyses of data derived using experimental mouse models.^{13,14} At birth, the epidermis of IP patients is a mosaic of cells expressing either wild-type or mutated *NEMO* proteins. At this stage, cells expressing mutated *NEMO* and defective NF- κ B activation begin to produce large quantities of IL-1 β , which likely acts on neighboring cells lacking the mutation. As a response, TNF- α is synthesized by such cells and (reciprocally) affects those cells carrying the *NEMO* mutation, inducing apoptosis. During the first weeks of life, several stimuli may induce the inflammatory response, including bacterial colonization of the skin and gastrointestinal tract, oxidative stress caused by the transition from intrauterine to extrauterine life, and exposure to various environmental antigens. Liao et al.¹⁵ reported a higher serum TNF- α level in a female infant with IP compared with normal controls. However, we do not have enough data to

confirm this finding, although the elevation of sTNFR1 level in the CSF of our patient may suggest that TNF- α is produced intermittently in the CNS during the course of an encephalopathic event. A TNF- α level below the cutoff value may be attributable to rapid metabolism of the cytokine (which has a half-life in serum of 20–30 minutes). The CSF IL-1 β level was below the cutoff value. It is possible that IL-1 β , triggering CNS lesions, may have been produced systemically (thus in blood) rather than in the CNS. We cannot exclude the possibility that cytokine elevation is triggered by prolonged seizures because it is difficult to compare IP patients who do and do not suffer a series of seizures. To fully elucidate the roles played by cytokines in the development of CNS lesions in IP patients, further studies using larger numbers of patients and simultaneous serum and CSF cytokine level measurements are required.

Notably, the levels of CSF oxidative stress markers were elevated markedly in our patient. These values fell only mildly after the neurological symptoms disappeared. 8-OHdG is a sensitive marker of oxidative DNA damage. Fukuda et al.¹⁶ emphasized that the measurement of urine and CSF 8-OHdG levels were useful in evaluation of the extent of oxidative brain damage in children. HEL is a novel marker of oxidative tissue damage occurring during the early stages of lipid peroxidation. The brain is a rich source of fats; thus, any elevation in HEL levels may reflect oxidative brain damage.¹⁷ Together, the data suggest that oxidative stress may contribute to the development of brain lesions in infants with IP. It is possible that a unique inflammatory process operative in such infants may trigger production of excessive levels of oxygen radicals, accelerating brain damage.

Notably, the levels of cytokines other than sTNFR1 were (generally) below the cutoff levels in our patient. This indicates that hypercytokinemia, also referred to as a “cytokine storm,” did not contribute to CNS pathogenesis in our patient. Hypercytokinemia is considered to be a principal cause of acute encephalopathy in children.⁸ Marked elevations in serum and CSF cytokine levels have been reported in children with influenza-associated encephalopathy.^{9,10} Our present results suggest that the “cytokine storm” hypothesis may not account for the development of CNS lesions in IP patients.

Our magnetic resonance imaging findings, especially the DWI data, were similar to those of previous studies.^{2–5} Water diffusion restriction was often evident in the corpus callosum, internal capsule, and basal ganglia, and also in the subcortical white matter of IP infants suffering from encephalopathic events. Cytotoxic edema is a characteristic of CNS lesions of IP patients, and DWI usefully delimits the extents of affected regions.

Conclusions

We measured the levels of CSF oxidative stress markers and cytokines during an encephalopathic event in a neonate with IP. Oxidative stress marker levels were elevated, but cytokine levels (except that of sTNFR1) were mostly below the limits of detection. These results suggest that oxidative stress may be associated with the pathogenesis of brain lesions characteristic of IP and that CSF cytokine levels may not in fact be elevated during an encephalopathic event.

TABLE.

Cerebrospinal Levels of Oxidative Stress Markers and Cytokines

	Mean (S.D.)	6 Days of Age	25 Days of Age
8-OHdG (ng/mL)	0.04 (0.02)	0.277	0.198
HEL (nmol/L)	3.28 (1.32)	9.687	7.455
IFN- γ (pg/mL)	6.6 (0.21)	<0.16	<0.16
TNF- α (pg/mL)	<0.06*	<0.06	<0.06
sTNFR1 (pg/mL)	423 (110)	701	1110
IL-1 β (pg/mL)	0.4 (0.06)	0.24	0.22
IL-2 (pg/mL)	<0.5*	<0.5	<0.5
IL-4 (pg/mL)	0.1 (0.01)	<0.01	0.08
IL-6 (pg/mL)	3.5 (2.9)	1.22	0.97
IL-8 (pg/mL)	58.5 (30)	41.66	35.45
IL-10 (pg/mL)	0.9 (0.8)	<0.11	5.19

8-OHdG = 8-hydroxy-2-deoxyguanosine

HEL = Hexanoyl-lysine adduct

IFN = Interferon

IL = Interleukin

sTNFR1 = Soluble tumor necrosis factor receptor 1

TNF- α = Tumor necrosis factor receptor- α

* In TNF- α and IL-2, the detection sensitivity was shown because the value was undetectable in both the patient and the controls.

This study is supported by the grant from the Ministry of Health, Labour and Welfare (H24-Shinkou-Ippan-002) and the grants from the Ministry of Education, Culture, Sports, Science, and Technology (23591518 and 26461551).

References

- Smahi A, Courtois G, Vabres P, et al. Genomic rearrangement in NEMO impairs NF- κ B activation and is a cause of incontinentia pigmenti. The International Incontinentia Pigmenti (IP) consortium. *Nature*. 2000;405:466–472.
- Hart AR, Edwards C, Mahajan J, Wood ML, Griffiths PD. Destructive encephalopathy in incontinentia pigmenti. *Dev Med Child Neurol*. 2009;51:162–163.
- Wolf NI, Krämer N, Harting I, et al. Diffuse cortical necrosis in a neonate with incontinentia pigmenti and an encephalitis-like presentation. *Am J Neuroradiol*. 2005;26:1580–1582.
- Loh NR, Jadresic LR, Whitelaw A. A genetic cause for neonatal encephalopathy: incontinentia pigmenti with NEMO mutation. *Acta Paediatr*. 2008;97:379–381.
- Abe S, Okumura A, Hamano S, et al. Early infantile manifestations of incontinentia pigmenti mimicking acute encephalopathy. *Brain Dev*. 2011;33:28–34.
- Hennel SJ, Ekert PG, Volpe JJ. Insights into the pathogenesis of cerebral lesions in incontinentia pigmenti. *Pediatr Neurol*. 2003;29:148–150.
- Kaczala GW, Messer MA, Poskitt KJ, Prendiville JS, Gardiner J, Senger C. Therapy resistant neonatal seizures, linear vesicular rash, and unusually early neuroradiological changes: incontinentia pigmenti. *Eur J Pediatr*. 2008;167:979–983.
- Mizuguchi M, Yamanouchi H, Ichiyama T, Shiomi M. Acute encephalopathy associated with influenza and other viral infections. *Acta Neurol Scand*. 2007;186(4 suppl):45–56.
- Aiba H, Mochizuki M, Kimura M, Hojo H. Predictive value of serum interleukin-6 level in influenza virus-associated encephalopathy. *Neurology*. 2001;57:295–299.
- Ichiyama T, Morishima T, Isumi H, Matsufuji H, Matsubara T, Furukawa S. Analysis of cytokine levels and NF- κ B activation in peripheral blood mononuclear cells in influenza virus-associated encephalopathy. *Cytokine*. 2004;27:31–37.
- Miyata R, Tanuma N, Hayashi M, et al. Oxidative stress in patients with clinically mild encephalitis/encephalopathy with a reversible splenic lesion (MERS). *Brain Dev*. 2012;34:124–127.
- Chatkupt S, Gozo AO, Wolansky LJ, Sun S. Characteristic MR findings in a neonate with incontinentia pigmenti. *Am J Radiol*. 1993;160:372–374.
- Pasparakis M, Courtois G, Hafner M, et al. TNF-mediated inflammatory skin disease in mice with epidermis-specific deletion of IKK2. *Nature*. 2002;417:861–866.
- Nenci A, Huth M, Funteh A, et al. Skin lesion development in a mouse model of incontinentia pigmenti is triggered by NEMO-deficiency in epidermal keratinocytes and requires TNF signaling. *Hum Mol Genet*. 2006;15:531–542.
- Liao SL, Lai SH, Huang JL, Lee NC, Lee WI. Serial cytokine expressions in infants with incontinentia pigmenti. *Immunobiology*. 2013;218:772–779.
- Fukuda M, Yamauchi H, Yamamoto H, et al. The evaluation of oxidative DNA damage in children with brain damage using 8-hydroxydeoxyguanosine levels. *Brain Dev*. 2008;30:131–136.
- Suzuki T, Kazui T, Yamamoto S, et al. Effect of prophylactically administered edaravone during antegrade cerebral perfusion in a canine model of old cerebral infarction. *J Thorac Cardiovasc Surg*. 2007;133:710–716.