

Published in final edited form as:

Psychosomatics. 2014 ; 55(6): 525–535. doi:10.1016/j.psych.2014.03.010.

Catatonia After Cerebral Hypoxia: Do the Usual Treatments Apply?

Davin K. Quinn, M.D.¹ and Christopher C. Abbott, M.D.¹

¹University of New Mexico School of Medicine, Department of Psychiatry, Albuquerque, NM

Abstract

Introduction—Neurologic deterioration occurring days to weeks after a cerebral hypoxic event accompanied by diffuse white matter demyelination is called delayed post-hypoxic leukoencephalopathy (DPHL). Manifestations of DPHL are diverse, and include dementia, gait disturbance, incontinence, pyramidal tract signs, parkinsonism, chorea, mood and thought disorders, akinetic mutism, and rarely catatonia.

Methods—The authors report a case of malignant catatonia in a patient diagnosed with DPHL that was refractory to electroconvulsive therapy (ECT), and review the literature on catatonia in DPHL.

Results—The patient was a 56 year-old female with schizoaffective disorder who was admitted with catatonia two weeks after hospitalization for drug overdose and respiratory failure. Her catatonic symptoms did not respond to lorazepam, amantadine, methylphenidate, or ten sessions of bilateral ECT at maximum energy. Repeat magnetic resonance imaging revealed extensive periventricular white matter lesions not present on admission scans, and she was diagnosed with DPHL.

Discussion—No treatment for DPHL has been proven to be widely effective. Hyperbaric oxygen treatments may reduce the rate of development, and symptom improvement has been reported with stimulants and other psychotropic agents. Review of the literature reveals rare success with GABAergic agents for catatonia after cerebral hypoxia, and no cases successfully treated with ECT. There are seven case reports of neurologic decompensation during ECT treatment after a cerebral hypoxic event.

Conclusion—Caution is advised when considering ECT for catatonia when delayed sequelae of cerebral hypoxia are on the differential diagnosis, as there is a dearth of evidence to support this treatment approach.

© 2014 Academy of Psychosomatic Medicine. Published by Elsevier Inc. All rights reserved.

Address for Correspondence: Dr. Davin K. Quinn, UNM Psychiatric Center, 2600 Marble Avenue NE, Albuquerque, NM 87131, dquinn@salud.unm.edu, Phone: 505-272-4763, Fax: 505-272-0690.

Disclosure: The authors report no financial or ethical conflicts of interest to disclose.

Publisher's Disclaimer: This is a PDF file of an unedited manuscript that has been accepted for publication. As a service to our customers we are providing this early version of the manuscript. The manuscript will undergo copyediting, typesetting, and review of the resulting proof before it is published in its final citable form. Please note that during the production process errors may be discovered which could affect the content, and all legal disclaimers that apply to the journal pertain.

Introduction

Prolonged cerebral hypoxia, regardless of etiology, may result in a wide spectrum of acute neurologic manifestations in humans.^{1,2} Cortical gray matter, basal ganglia, white matter, cerebellum, midbrain, and hippocampus may all show evidence of acute damage following hypoxia.¹⁻³ Common causes of cerebral hypoxia include strangulation, carbon monoxide inhalation, cardiac arrest, anesthesia, overdose from sedatives and narcotics, and respiratory failure.³⁻⁵ A delayed neurological syndrome (DNS) may develop following a symptom-free interval up to 40 days after cerebral hypoxia, although cases of symptoms emerging up to one year later have been reported.^{6,7} Contemporary estimates of the prevalence of DNS after carbon monoxide poisoning range from 3 to 9%.^{6,8} The most common symptoms of DNS are confusion, incontinence, gait disturbance, mutism, and parkinsonism, but may include pyramidal tract signs, rigidity, pathologic reflexes, chorea, dementia, mood disorders, psychosis, hysteria, and akinetic mutism.^{1,2,6,7} Risk factors for DNS include more severe acute hypoxic symptoms, acute neuroimaging abnormalities, and age greater than 40.^{9,10} Although initial scan abnormalities do not necessarily predict the development of DNS, symptom improvement tends to correlate with resolution of neuroimaging findings over time.^{11,12} Prognosis is encouraging: up to 75% of cases of DNS recovered fully after carbon monoxide poisoning in a large cohort study of this phenomenon.⁶ When DNS is accompanied by demyelination of cerebral white matter seen on neuroimaging or at autopsy, it is termed delayed post-hypoxic leukoencephalopathy (DPHL).^{13,14} Bed rest, hyperbaric oxygen, and psychotropic medications have been described in case reports and case series to be helpful, but no proven treatments exist for DNS or DPHL.^{1,14,15}

Catatonia is rarely described after cerebral hypoxia.⁶ The authors report a case of malignant catatonia in a patient with schizoaffective disorder that did not respond to benzodiazepines, dopamine agonists, or ten sessions of bilateral ECT, and was later diagnosed as DPHL. The literature on catatonic symptoms in DNS and DPHL is reviewed, including epidemiology, diagnosis, and treatment.

Case Report

The patient is a 56 year-old female with an established history of schizoaffective disorder and cirrhosis secondary to hepatitis C, who presented to a tertiary care center with three days of progressive change in behavior. Two weeks prior to this presentation she had unintentionally overdosed on her narcotic analgesics and was found unresponsive by family in bed. She was taken to a local hospital where she was diagnosed with aspiration pneumonia and hypoxic respiratory failure, and was intubated and admitted to intensive care. After four days of mechanical ventilation and sedation she was extubated with only mild transient confusion. She was observed for three more days then discharged home where she functioned at her usual baseline for four more days. She then became progressively slowed and confused, with complaints of nausea, neck stiffness, and back pain, and urinary incontinence. She also was noted to stand in one place for several hours, holding her arms over her head, stamping her feet repetitively, and repeating what others would say to her. On the day of admission she was found to be floridly disoriented, agitated, and withdrawing in pain when touched or moved.

She had an allergy to doxycycline, and was taking alendronate, ketoconazole, clopidogrel, fentanyl, oxycodone, escitalopram, divalproex sodium, gabapentin, risperidone, and benztropine. Her psychiatric history included a diagnosis of schizoaffective disorder, with a remote history of hospitalization fifteen years prior to presentation for depression and delusions. She had continued receiving her psychiatric medications during and after the previous hospitalization. She had last used recreational cocaine and alcohol over 15 years ago.

On examination, her temperature was 36.3 degrees Fahrenheit, respiration rate 25 per minute, heart rate 98 beats per minute, blood pressure 127/61. The patient was agitated and mute to most simple questions, with antigravity posturing of the left arm, echolalia of the examiner's questions, verbigeration, staring at the ceiling, bilateral grasp reflexes, and rigidity in all four limbs without cogwheeling. Neurological examination of cranial nerves and deep tendon reflexes was without abnormality. Attempted passive neck flexion elicited pain response.

The patient was admitted to the hospital for work up of her altered mental status. Given the concern for meningismus on examination, vancomycin, ceftriaxone, and acyclovir were started while lumbar puncture was attempted unsuccessfully. Magnetic resonance imaging (MRI) of the brain without contrast did not reveal abnormalities. Electroencephalograph (EEG) revealed a background of generalized polymorphic 6-7 Hz theta waves, 2-3 Hz delta waves, and superimposed beta waves, without epileptiform abnormality. Laboratory testing, including urinalysis, complete blood count, complete metabolic panel, hepatic function tests, B vitamin and homocysteine levels, thyroid function tests, human immunodeficiency virus (HIV) antibody, erythrocyte sedimentation rate (ESR) and c-reactive protein (CRP), coagulation studies, lactic acid, troponin and creatine kinase, lactate dehydrogenase (LDH), arterial blood gas, and hemoglobin A1c were unrevealing. Mean corpuscular volume was elevated at 105. Iron studies revealed elevated serum iron of 232 ug/dL, iron saturation of 90%, and elevated ferritin at 625 ng/mL, which were felt to be acute phase reactants. Ammonia was mildly elevated at 52, and normalized without clinical improvement. Additional tests for plasma porphyrins, cortisol, antithyroid antibodies, ceruloplasmin, urine heavy metals, and paraneoplastic antibodies (including to the NMDA receptor) were unrevealing.

Over the first week of hospitalization the patient's heart rate ranged from 61 to 109 beats per minute and blood pressure varied from 99/55 to as high as 199/114 mmHg. The patient was diagnosed with malignant catatonia/neuroleptic malignant syndrome on the basis of autonomic instability, rigidity, and stupor, and all psychiatric medications were discontinued without change in symptoms. Bush-Francis Catatonia Rating Scale score was 25. A benzodiazepine challenge with 2 mg intravenous lorazepam brought about sedation and improvement in rigidity, but as soon as the patient awoke her catatonic symptoms returned immediately. Standing doses of lorazepam up to 6 mg per day for one week had no further benefit and caused oversedation. Administration of intravenous benztropine 2 mg TID and amantadine up to 400 mg daily for one week yielded no improvement.

With the consent of the patient's family, the patient was given ten rounds of bitemporal electroconvulsive therapy (ECT) with a Thymatron System IV (Somatics LLC, Lake Bluff, IL) for malignant catatonia/neuroleptic malignant syndrome. Induction agents included methohexital and ketamine (to lower seizure threshold), and modification was achieved with rocuronium to reduce risk of hyperkalemia from depolarizing muscle relaxants. EEG seizure lengths ranged from 20 to 48 seconds. No complications of anesthesia or ECT occurred.

By the tenth treatment there had been no improvements in the patient's condition, and ECT was ceased. Neurology was consulted, and repeat MRI without contrast was obtained, which showed new extensive bilateral periventricular white matter changes (see Figure 1). An exhaustive workup for causes of leukoencephalopathy included serum and urine protein electrophoresis, cancer markers, antinuclear antibody titer, angiotensin-converting enzyme level, arylsulfatase level, serum fatty acid levels, and cerebrospinal fluid analysis, all of which were unrevealing. Trials of intravenous steroids and plasmapheresis for possible autoimmune encephalopathy brought about no improvement in the patient's condition. Methylphenidate 10 mg bid was trialed for two weeks without benefit. The patient was discharged to skilled nursing care with a diagnosis of delayed hypoxic leukoencephalopathy, and after one year continued to manifest near-complete mutism and stupor.

Discussion

DPHL is a rare sequel of cerebral hypoxia, and is estimated to occur in 0.06-2.8% of patients with carbon monoxide poisoning.⁶ Severity of initial hypoxia or coma is not consistently correlated with risk of DPHL.⁴ Arylsulfatase A pseudodeficiency has been found in several cases, but this is neither sufficient nor necessary to cause the condition.¹³ The mechanism of injury in DPHL is not known, although the limited arteriolar distribution in white matter and delayed apoptosis of oligodendrocytes responsible for myelin production have been put forward as theoretical contributors.¹⁴ The pattern of damage typically involves subcortical and periventricular frontal and parietal white matter of the centrum semiovale; in contrast, toxic leukoencephalopathy caused by substances such as methadone and heroin is more often found in the cerebellum, internal capsule, hippocampus, and brainstem.¹⁶⁻¹⁸ Neuropathologic findings of intramyelinic vacuolar edema may also distinguish toxic from hypoxic etiologies.¹⁹ Blood-brain barrier disruption and elevated choline and creatine levels in white matter on magnetic resonance spectroscopy have been observed after hypoxic injury.^{20,21} Functional imaging reveals altered cerebral blood flow and hypometabolism in damaged regions, while diffusion tensor imaging of white matter demonstrates reduced fractional anisotropy and tends to correlate with neuropsychiatric outcome.²²⁻²⁴ Many cases of DPHL exhibit spontaneous improvement, some with full functional recovery.^{25,26}

Diagnosis of DPHL is made on the basis of clinical characteristics and neuroimaging findings, and requires ruling out other causes of leukoencephalopathy.¹⁴ The delayed nature of the disorder, occurring days to weeks after the inciting event, can make accurate and timely diagnosis difficult. No treatment for DPHL has been proven to be widely effective. Hyperbaric oxygen treatments have been shown in several studies of acute carbon monoxide poisoning to reduce the rate of development of neurological symptoms, as well as to improve symptoms once diagnosed,^{9,15} but this is not a consistent finding.²⁷ Medications

associated with symptom improvement in case reports and case series include stimulants and dopamine agonists, levodopa, magnesium sulfate, steroids, antipsychotics, and coenzyme Q-10.²⁸⁻³⁴

Cerebral Hypoxia and Catatonia

European neuropsychiatrists of the early 20th century were well-acquainted with neurological symptoms following hypoxia owing to the extensive use of carbon monoxide (CO)-containing gases in domestic and industrial settings. The delayed neurological syndrome was originally described by Sibelius in 1906.³⁵ Emil Kraepelin in 1919 was the first to describe catatonia in hypoxia: an 18 year-old man poisoned by smoke from a flue developed stupor and catalepsy ten days later, and Kraepelin questioned whether the man had dementia praecox.³⁶ Fritz Kant in 1926 reported longitudinal data on the same patient that supported the etiology of CO poisoning, as well as a second case of catatonia in a blacksmith with mutism, stupor, stereotypy, and catalepsy following chronic CO intoxication from a malfunctioning furnace.³⁷ Several English-language descriptions of catatonia after hypoxia followed in the 1930s and 40s, all featuring delayed symptoms of stupor, mutism, and catalepsy.³⁸⁻⁴⁰ These authors made clear in their reports that catatonia and parkinsonism were both common phenomena after hypoxic episodes.

However, as electricity replaced fossil fuels for methods of illumination and mechanization in Europe and the United States, cases of catatonia stemming from hypoxia seemed to dwindle. Gelenberg's 1975 review of the catatonic syndrome listed hypoxia as a potential etiology based on only one of the above cases.⁴¹ Few cases in the modern literature describe patients with DNS or DPHL manifesting catatonia, suggesting this is now a rare phenomenon.^{7,16,25,42} Of the published cases of DPHL in the National Library of Medicine database (Pubmed) after 1980, when MRI scanners became commercially available, only nine cases were identified as meeting DSM-5 criteria for catatonia due to general medical condition (see Table 1).⁴³ However, this apparent rarity is contradicted by the ubiquity of documented catatonia-spectrum symptoms in the modern hypoxia literature. For instance, in Min's 1986 series of 86 patients with DNS after CO poisoning, 100% had apathy, 95% had hypokinesia, 95% had mutism, 87% displayed grasp reflex, 86% displayed muscle rigidity, 70% showed bizarre behavior, 41% displayed mannerisms, and 2% displayed echolalia.³² In Hsiao's small series of 12 patients with DPHL after CO poisoning, 50% displayed mutism, 50% had rigidity, and 42% were bradykinetic.¹² No patients in either of these studies were identified as having catatonia *per se*. In Choi's seminal retrospective series of 2360 cases of carbon monoxide poisoning, catatonia is mentioned as a rare delayed sequel but no specific prevalence is given.⁶ The predilection for damage to the basal ganglia and frontal/parietal white matter after cerebral hypoxia may help explain why rigidity, apathy, catalepsy, and mutism are prevalent in these patients, given the neuroimaging evidence that dysfunction in these areas contributes to catatonic symptoms.⁴⁴ See Table 2 for the differential diagnosis of catatonia after a hypoxic event.

Misunderstanding of catatonia due to a general medical condition likely contributes to its perceived rarity after cerebral hypoxia: a recent published review of DPHL considered the presence of MRI abnormalities to exclude a diagnosis of catatonia, DSM-5

notwithstanding.¹⁴ There is also significant overlap between catatonia and other motor disorders commonly associated with DNS and DPHL such as parkinsonism and akinetic mutism, a problem alluded to in the German literature nearly 100 years ago.^{37,45} The neurologist C. Miller Fisher, in his treatise on catatonia, grappled with the similarities between akinetic mutism and catatonia but ultimately failed to parse them into distinct disorders with distinct etiologies.⁴⁶ Akinetic mute patients, who display little to no volitional movement or speech but manifest alertness and engagement with their eyes, easily qualify for caseness on the Bush-Francis Catatonia Rating Scale by having 2 of the 14 cardinal symptoms;^{47,48} utilizing these criteria the number of DNS and DPHL cases with catatonia would reach into the hundreds.

Perhaps owing to continued misunderstanding, standard treatments of catatonia such as high-dose benzodiazepines and electroconvulsive therapy (ECT) have not been extensively studied in patients with cerebral hypoxic injury. Diazepam and sodium amobarbital successfully alleviated delayed akinetic and catatonic symptoms in two cases of carbon monoxide poisoning.^{49,50} Lorazepam was partially effective for catatonia in DPHL after a methadone overdose, and several cases of akinetic mutism after DPHL responded to zolpidem.^{25,51,52} Dopamine agonists are routinely used for akinetic mutism, and may also have efficacy in catatonia, underlining the overlapping nature of these syndromes.^{29,53}

There are three reports in the medical literature of ECT used unsuccessfully for catatonia symptoms in the context of cerebral hypoxia (Table 3).⁵⁴⁻⁵⁶ Cavioto *et al* in 1960 briefly described a 57 year-old woman hospitalized after twenty-two hours' exposure to natural gas.⁵⁴ She opened her eyes to stimulation and demonstrated generalized rigidity, but was otherwise mute and stuporous. Laboratory studies were normal and EEG showed diffuse slowing. Ten sessions of ECT did not bring about change in her status and she expired 2.5 months after admission. In 1971 Wajgt reported a case of acute carbon monoxide poisoning in a 25 year-old male manifesting negativism, agitation, and restlessness who received one session of ECT three days later and abruptly went into coma and expired.⁵⁵ A third case by Rasmussen described a 65 year-old female who developed delayed catatonic symptoms three weeks after a narcotic overdose.⁵⁶ She received eight bitemporal ECT for presumed catatonic depression, with worsening of her symptoms. MRI post-ECT showed "dramatic white-matter hyperintensities" ascribed to small-vessel ischemic changes that were not detected on pre-ECT computed tomography scan.

Our case represents a fourth instance of ECT failing to ameliorate catatonic symptoms after cerebral hypoxia. The absence of a single case of successful ECT is on the one hand surprising, as ECT can be safe and effective in patients with organic brain disease in general, after acute stroke, and in elderly patients with pre-existing leukoencephalopathy.⁵⁷⁻⁵⁹ On the other hand, several authors have observed that ECT for catatonia is generally less efficacious in neurologically based disorders than in primary psychiatric disorders and that patients with certain neurological conditions may be at higher risk of adverse effects of ECT.^{56,60,61} A small case series of patients with multiple sclerosis undergoing ECT suggested that white matter damage predisposed to neurologic deterioration during treatment.⁶² Other authors have expressed specific concern that ECT after cerebral hypoxia may cause further harm by increasing metabolic demand in neurons damaged by oxygen

deprivation.^{50,63} The historical basis for this concern is comprised of seven cases of ECT performed for major depression within three weeks following suicide attempts by carbon monoxide poisoning (Table 3), with development of delayed neuropsychiatric symptoms during the ECT course.^{50,63-65} A recent review of these cases made note that several of the patients had risk factors for DNS (older age, severity of hypoxia) and that ECT was administered well within the window for DNS to occur.⁶⁶

Despite the lack of evidence for causation in these cases, it has been recommended that in acute neurologic illness, ECT should be used only in the absence of other treatment options, and after a one-month waiting period if following hypoxia.^{56,66} However, moving with alacrity to ECT in cases of malignant catatonia has also been strongly recommended given the risk of medical complications and fatality from cardiovascular collapse.⁶⁷ Two cases of safe and successful ECT after cerebral hypoxia have been described, both for depression in the subacute/chronic phase (Table 3).^{66,68} Thus clinicians are left with a meager evidence base on which to formulate the risk-benefit analysis, between offering ECT to the patient with catatonic symptoms after hypoxia given its broad efficacy, versus withholding ECT given potential for worsening.

Our case is noteworthy in that the patient's catatonic symptoms of DPHL preceded the appearance of leukoencephalopathy by several weeks. Without neuroimaging findings on MRI during the pre-ECT workup, the possibility of a structural neurologic condition was considered less likely compared to a systemic illness or exposure to antipsychotics and anticonvulsants, tipping the risk-benefit analysis toward treatment. It is possible our patient's opiate overdose itself rather than hypoxia *per se* could have caused her delayed leukoencephalopathy. However, she had tolerated the opiates at prescribed doses without problem, and the pattern of damage was more consistent with that seen in hypoxia than in toxic effects. The contribution of ECT to the appearance of leukoencephalopathy on our patient's brain MRI cannot be completely excluded. ECT in its current technical practice causing structural brain damage or significant hypoxia has been amply refuted by prospective trials,^{69,70} and biomarkers of brain damage such as CSF levels of S-100b or neuron specific enolase are absent after ECT treatment.^{71,72} In a recently published review of neuroimaging studies in ECT by the authors, four positron emission tomography (PET) studies found reduced cerebral metabolism in bilateral medial and inferior frontal areas after ECT, corresponding to response of depressive symptoms to treatment.⁷³ This, along with the common occurrence of post-ECT delirium, may at first glance lend credence to the concern that metabolic effects of ECT could be harmful in hypoxia-damaged brain. However, it has also been shown that antidepressant medications and cognitive behavioral therapy can induce frontal and limbic hypometabolism, and these interventions are generally not considered harmful after cerebral hypoxia.⁷⁴ It is not clear at this time whether brain metabolic changes accompanying ECT response necessarily represent a harmful process for the DNS/DPHL patient.

At this time there continues to be no published evidence that ECT is successful for catatonia after cerebral hypoxia. We believe this has significant implications for treatment of future cases. Considering that a majority number of patients recover with less aggressive measures, we agree with the recommendations of prior authors that treatments such as hyperbaric

oxygen, benzodiazepines, stimulants, antidepressants, and cognitive enhancers should be fully explored, a careful risk-benefit analysis performed, and the window for possible DNS allowed to pass before moving to ECT when cerebral hypoxia is on the differential.

Acknowledgments

Dr. Abbott was supported in the writing of this article by the Dana Foundation Brain and Immune Imaging grant and a COBRE Phase II grant (2P20GM103472-01).

References

1. Plum F, Posner JB, Hain RF. Delayed neurological deterioration after anoxia. *Arch Intern Med*. 1962; 110:18–25. [PubMed: 14487254]
2. Garland H, Pearce J. Neurological complications of carbon monoxide poisoning. *Q J Med*. 1967; 36(144):445–455. [PubMed: 6077225]
3. Ginsberg MD, Hedley-White ET, Richardson EP Jr. Hypoxic-ischemic leukoencephalopathy in man. *Arch Neurol*. 1976; 33(1):5–14. [PubMed: 1247396]
4. Posner, JB.; Saper, CB.; Schiff, ND.; Plum, F., editors. *Diagnosis of stupor and coma* Ch 5: multifocal, diffuse, and metabolic brain diseases causing delirium, stupor, or coma. Oxford University Press; Oxford: 2007. p. 43-44.
5. Shprecher DR, Flanigan KM, Smith AG, Smith SM, Schenkenberg T, Steffens J. Clinical and diagnostic features of delayed hypoxic leukoencephalopathy. *J Neuropsychiatry Clin Neurosci*. 2008; 20(4):473–477. [PubMed: 19196933]
6. Choi IS. Delayed neurological sequelae in carbon monoxide intoxication. *Arch Neurol*. 1983; 40(7): 433–435. [PubMed: 6860181]
7. Choi IS. Parkinsonism after carbon monoxide poisoning. *Eur Neurol*. 2002; 48(1):30–33. [PubMed: 12138307]
8. Meigs JW, Hughes JP. Acute carbon monoxide poisoning: an analysis of one hundred five cases. *AMA Arch Ind Hyg Occup Med*. 1952; 6(4):344–356. [PubMed: 12984846]
9. Hu H, Pan X, Wan Y, Zhang Q, Liang W. Factors affecting the prognosis of patients with delayed encephalopathy after acute carbon monoxide poisoning. *Am J Emerg Med*. 2011; 29(3):261–264. [PubMed: 20825794]
10. Ku HL, Yang KC, Lee YC, Lee MB, Chou YH. Predictors of carbon monoxide poisoning-induced delayed neuropsychological sequelae. *Gen Hosp Psychiatry*. 2010; 32(3):310–314. [PubMed: 20430235]
11. Pavese N, Napolitano A, De Iaco G, Canapicchi R, Collavoli PL, Lucetti C, Gambaccini G, Bonuccelli U. Clinical outcome and magnetic resonance imaging of carbon monoxide intoxication: a long-term follow-up study. *Ital J Neurol Sci*. 1999; 20(3):171–178. [PubMed: 10541600]
12. Hsiao CL, Juo HC, Huang CC. Delayed encephalopathy after carbon monoxide intoxication—long-term prognosis and correlation of clinical manifestations and neuroimages. *Acta Neurol Taiwan*. 2004; 13(2):64–70. [PubMed: 15478677]
13. Lee HB, Lyketsos CG. Delayed post-hypoxic leukoencephalopathy. *Psychosomatics*. 2001; 42(6): 530–533. [PubMed: 11815692]
14. Shprecher DR, Mehta L. The syndrome of delayed post-hypoxic leukoencephalopathy. *NeuroRehabilitation*. 2010; 26(1):65–72. [PubMed: 20166270]
15. Chang DC, Lee JT, Lo CP, Fan YM, Huang KL, Kang BH, Hsieh HL, Chen SY. Hyperbaric oxygen ameliorates delayed neuropsychiatric syndrome of carbon monoxide poisoning. *Undersea Hyperb Med*. 2010; 37(1):23–33. [PubMed: 20369650]
16. Filley CM, Kleinschmidt Demasters BK. Toxic leukoencephalopathy. *New Engl J Med*. 2001; 345(6):426–431.
17. Molloy S, Soh C, Williams TL. Reversible delayed posthypoxic leukoencephalopathy. *AJNR Am J Neuroradiol*. 2006; 27(8):1763–1765. [PubMed: 16971632]

18. Offiah C, Hall E. Heroin-induced leukoencephalopathy: characterization using MRI, diffusion-weighted imaging, and MR spectroscopy. *Clin Radiol.* 2008; 63(2):146–152. [PubMed: 18194689]
19. Kriegstein AR, Shungu DC, Millar WS, Armitage BA, Brust JC, Chillrud S, Goldman J, Lynch T. Leukoencephalopathy and raised brain lactate from heroin vapor inhalation (“chasing the dragon”). *Neurology.* 1999; 53(8):1765–1773. [PubMed: 10563626]
20. Huisa BN, Gasparovic C, Taheri S, Prestopnik JL, Rosenberg GA. Imaging of subacute blood-brain barrier disruption after methadone overdose. *J Neuroimaging.* 2013; 23(3):441–444. [PubMed: 22211853]
21. Beppu T, Nishimoto H, Fujiwara S, Kudo K, Sanjo K, Narumi S, Oikawa H, Onodera M, Ogasawara K, Sasaki M. ¹H-magnetic resonance spectroscopy indicates damage to cerebral white matter in the subacute phase after CO poisoning. *J Neurol Neurosurg Psychiatry.* 2011; 82(8):869–875. [PubMed: 21242286]
22. Sesay M, Bidabe AM, Guyot M, Bedry R, Caille JM, Maurette P. Regional cerebral blood flow measurements with Xenon-CT in the prediction of delayed encephalopathy after carbon monoxide intoxication. *Acta Neurol Scan.* 1996; 166(suppl):22–27.
23. Tengvar C, Johansson B, Sorensen J. Frontal lobe and cingulate cortical metabolic dysfunction in acquired akinetic mutism: a PET study of the interval form of carbon monoxide poisoning. *Brain Injury.* 2004; 18(6):615–625. [PubMed: 15204341]
24. Hou X, Ma L, Wu L, Zhang Y, Ge H, Li Z, Gao Y, Zhou Y, Gao C. Diffusion tensor imaging for predicting the clinical outcome of delayed encephalopathy of acute carbon monoxide poisoning. *Eur Neurol.* 2013; 69(5):275–280. [PubMed: 23429164]
25. Cottencin O, Guardia D, Warembourg F, Gaudry C, Goudemand M. Methadone overdose, auto-activation deficit, and catatonia: a case study. *Prim Care Companion J Clin Psychiatry.* 2009; 11(5):275–276. [PubMed: 19956473]
26. Cocito L, Biagioli M, Fontana P, Inglese ML, Pizzorno M, Spigno F, Volpe S. Cognitive recovery after delayed carbon monoxide encephalopathy. *Clin Neurol Neurosurg.* 2005; 107(4):347–350. [PubMed: 15885398]
27. Buckley NA, Juurlink DN, Isbister G, Bennett MH, Lavonas EJ. Hyperbaric oxygen for carbon monoxide poisoning. *Cochrane Database Syst Rev.* 2011; 13(4):CD002041. [PubMed: 21491385]
28. Smallwood P, Murray GB. Neuropsychiatric aspects of carbon monoxide poisoning: a review and single case report suggesting a role for amphetamines. *Ann Clin Psychiatry.* 1999; 11(1):21–27. [PubMed: 10383172]
29. Arciniegas DB, Frey KL, Anderson CA, Brousseau KM, Harris SN. Amantadine for neurobehavioral deficits following delayed post-hypoxic encephalopathy. *Brain Inj.* 2004; 18(12):1309–1318. [PubMed: 15666573]
30. Custodio CM, Basford JR. Delayed postanoxic encephalopathy: a case report and literature review. *Arch Phys Med Rehabil.* 2004; 85(3):502–505. [PubMed: 15031841]
31. Rozen TD. Rapid resolution of akinetic mutism in delayed post-hypoxic leukoencephalopathy with intravenous magnesium sulfate. *NeuroRehabilitation.* 2012; 30(4):329–332. [PubMed: 22672948]
32. Min SK. A brain syndrome associated with delayed neuropsychiatric sequelae following acute carbon monoxide intoxication. *Acta Psychiatr Scan.* 1986; 73(1):80–86.
33. Hu MC, Shiah IS, Yeh CB, Chen HK, Chen CK. Ziprasidone in the treatment of delayed carbon monoxide encephalopathy. *Prog Neuropsychopharmacol Biol Psychiatry.* 2006; 30(4):755–757. [PubMed: 16581170]
34. Carroll I, Heritier Barras AC, Dirren E, Burkhard PR, Horvath J. Delayed leukoencephalopathy after alprazolam and methadone overdose: a case report and review of the literature. *Clin Neurol Neurosurg.* 2012; 114(6):816–819. [PubMed: 22341930]
35. Sibelius C. Die psychischen störungen nach acuter kohlenoxydvergiftung. *Mschr Psychiat Neurol.* 1906; 18:39–187.
36. Kraepelin, E. Einführung in die psychiatrische klinik. 3rd. Johann Ambrosius Barth; Leipzig: 1921. p. 29–34.
37. Kant F. Katatone motilitätspsychose nach CO-vergiftung. *Archiv fur Psychiatrie und Nervenkrankheiten.* 1926; 78(1):365–374.

38. Dancy TE, Reed GE. Mental disease following carbon monoxide poisoning. *Can Med Assoc J*. 1936; 35(1):47–49. [PubMed: 20320309]
39. Hsu YK, Cheng YL. Cerebral subcortical myelinopathy in carbon monoxide poisoning. *Brain*. 1938; 61:384–392.
40. Herman M, Harpham D, Rosenblum M. Nonschizophrenic catatonic states. *N Y State J Med*. 1942; 42:624–627.
41. Gelenberg AJ. The catatonic syndrome. *Lancet*. 1976; 1(7973):1339–1341. [PubMed: 58326]
42. Quinn DK, McGahee SM, Politte LC, Duncan GN, Cusin C, Hopwood CJ, Stern TA. Complications of carbon monoxide poisoning: a case discussion and review of the literature. *Prim Care Companion J Clin Psychiatry*. 2009; 11(2):74–79. [PubMed: 19617936]
43. American Psychiatric Association. Diagnostic and statistical manual of mental disorders. 5th. American Psychiatric Publishing; Arlington: 2013.
44. Northoff G, Steinke R, Nagel DC, Zerwenka C, Grosser O, Danos P, Genz A, Krause R, Böker H, Otto HJ, Bogerts B. Right lower prefronto-parietal cortical dysfunction in akinetic catatonia: a combined study of neuropsychology and regional cerebral blood flow. *Psychol Med*. 2000; 30(3): 583–596. [PubMed: 10883714]
45. Sours JA. Akinetic mutism simulating catatonic schizophrenia. *Am J Psychiatry*. 1962; 119(5): 451–455. [PubMed: 13978428]
46. Fisher CM. Catatonia due to disulfiram toxicity. *Arch Neurol*. 1989; 46(7):798–804. [PubMed: 2742552]
47. Cairns H, Oldfield RC, Pennybacker JB, Whitteridge D. Akinetic mutism with an epidermoid cyst of the 3rd ventricle. *Brain*. 1941; 64(4):273–290.
48. Bush G, Fink M, Petrides G, Dowling F, Francis A. Catatonia. I. rating scale and standardized examination. *Acta Psychiatr Scand*. 1996; 93(2):129–136. [PubMed: 8686483]
49. Caruso G, Barnaba A. Treatment with diazepam and remission of the extrapyramidal symptoms in a case of parkinsonism caused by carbon monoxide poisoning. *Acta Neurol (Napoli)*. 1968; 23(1): 103–110. [PubMed: 5739546]
50. Ginsburg R, Romano J. Carbon monoxide encephalopathy: need for appropriate treatment. *Am J Psychiatry*. 1976; 133(3):317–320. [PubMed: 1259043]
51. Brefel-Courbon C, Payoux P, Ory F, Sommet A, Slaoui T, Raboyeau G, Lemesle B, Puel M, Montastruc JL, Demonet JF, Cardebat D. Clinical and imaging evidence of zolpidem effect in hypoxic encephalopathy. *Ann Neurol*. 2007; 62(1):102–105. [PubMed: 17357126]
52. Shames JL, Ring H. Transient reversal of anoxic brain injury-related minimally conscious state after zolpidem administration: a case report. *Arch Phys Med Rehabil*. 2008; 89(2):386–388. [PubMed: 18226667]
53. Marin RS, Wilkosz PA. Disorders of diminished motivation. *J Head Trauma Rehabil*. 2005; 20(4): 377–388. [PubMed: 16030444]
54. Cavioto H, Silberman J, Feigin I. A clinical and pathologic study of akinetic mutism. *Neurology*. 1960; 10:10–21. [PubMed: 13812693]
55. Wajgt A. Cerebral vascular lesions after use of electroshock in a case of psychotic syndrome following carbon monoxide intoxication. *Neurol Neurochir Pol*. 1971; 5(4):587–590. [PubMed: 5122064]
56. Rasmussen KG, Hart DA, Lineberry TW. ECT in patients with psychopathology related to acute neurologic illness. *Psychosomatics*. 2008; 49(1):67–72. [PubMed: 18212179]
57. Zvil AS, Pelchat RJ. ECT in the treatment of patients with neurological and somatic disease. *Int J Psychiatry Med*. 1994; 24(1):1–29. [PubMed: 8077081]
58. Weintraub D, Lippman SB. Electroconvulsive therapy in the acute poststroke period. *J ECT*. 2000; 16(4):415–418. [PubMed: 11314880]
59. Coffey CE, Figiel GS, Djang WT, Cress M, Saunders WB, Weiner RD. Leukoencephalopathy in elderly depressed patients referred for ECT. *Biol Psychiatry*. 1988; 24(2):143–161. [PubMed: 3390496]
60. Swartz CM, Acosta D, Bashir A. Diminished ECT response in catatonia due to chronic neurologic condition. *J ECT*. 2003; 19(2):110–114. [PubMed: 12792461]

61. Krystal ED, Coffey CE. Neuropsychiatric considerations in the use of electroconvulsive therapy. *J Neuropsychiatry Clin Neurosci.* 1997; 9(2):283–292. [PubMed: 9144111]
62. Mattingly G, Baker K, Zorumsky CF, Figiel GS. Multiple sclerosis and ECT: possible value of gadolinium-enhanced magnetic resonance scans for identifying high-risk patients. *J Neuropsychiatry Clin Neurosci.* 1992; 4(2):145–151. [PubMed: 1627975]
63. Smith JS, Mellick RS. Neuropsychiatric relapse following acute carbon monoxide poisoning—the contribution of electroconvulsive therapy. *Med J Aust.* 1975; 1(15):465–468. [PubMed: 1152691]
64. Sandson TA, Lilly RB, Sodkol M. Kluver-Bucy syndrome associated with delayed post-anoxic leukoencephalopathy following carbon monoxide poisoning. *J Neurol Neurosurg Psychiatry.* 1988; 51(1):156–157. [PubMed: 3351520]
65. Yogaratnam J, Hariram J, Lee DS, Chua SP, Kim J, Sengupta S, Sim K. Delayed neuropsychiatric sequelae and recovery following carbon monoxide poisoning. *Ann Acad Med Singapore.* 2011; 40(11):516–517. [PubMed: 22206071]
66. Chiang CL, Tseng MC. Safe use of electroconvulsive therapy in a highly suicidal survivor of carbon monoxide poisoning. *Gen Hosp Psychiatry.* 2012; 34(1):103.e1–3. [PubMed: 21958445]
67. Mann SC, Caroff SN, Bleier HR, Welz WK, Kling MA, Hayashida M. Lethal catatonia. *Am J Psychiatry.* 1986; 143(11):1374–1381. [PubMed: 3777225]
68. Jerrett JG, Steffens DC. Carbon monoxide-related organic mood disorder successfully treated with ECT. *J Clin Psychiatry.* 1995; 56(7):332–3. [PubMed: 7615491]
69. Devanand DP, Dwork AJ, Hutchinson ER, Bolwig TG, Sackeim HA. Does ECT alter brain structure? *Am J Psychiatry.* 1994; 151(7):957–970. [PubMed: 8010381]
70. Bergsholm P, Larsen JL, Rosendahl K, Holsten F. Electroconvulsive therapy and cerebral computed tomography: a prospective study. *Acta Psychiatr Scand.* 1989; 80(6):566–572.
71. Angelink MW, Andrich J, Postert T, Wurzing U, Zeit T, Klotz P, Przuntek H. Relation between electroconvulsive therapy, cognitive side effects, neuron specific enolase, and protein S-100. *J Neurol Neurosurg Psychiatry.* 2001; 71:394–396. [PubMed: 11511718]
72. Palmio J, Huuhka M, Laine S, Huhtala H, Peltola J, Leinonen E, Suhonen J, Keranen T. Electroconvulsive therapy and biomarkers of neuronal injury and plasticity: serum levels of neuron-specific enolase and S-100b protein. *Psychiatry Res.* 2010; 177:97–100. [PubMed: 20378182]
73. Abbott CA, Gallegos P, Rediske N, Lemke NT, Quinn DK. A review of longitudinal electroconvulsive therapy: neuroimaging investigations. *J Geriatr Psychiatry Neurol.* 2014; 27(1):33–46. [PubMed: 24381234]
74. Kennedy SH, Konarski JZ, Segal ZV, Lau MA, Bieling PJ, McIntyre RS, Mayberg HS. Differences in brain glucose metabolism between responders to CBT and venlafaxine in a 16-week randomized controlled trial. *Am J Psychiatry.* 2007; 164:778–788. [PubMed: 17475737]
75. Gheuens S, Michotte A, Flamez A, De Keyser J. Delayed akinetic catatonic mutism following methadone overdose. *Neurotoxicology.* 2010; 31(6):762–764. [PubMed: 20688102]
76. Lou M, Jing CH, Selim MH, Caplan LR, Ding MP. Delayed substantia nigra damage and leukoencephalopathy after hypoxic-ischemic injury. *J Neurol Sci.* 2009; 277(1-2):147–149. [PubMed: 18954879]
77. Chen-Plotkin AS, Pau KT, Schmammann JD. Delayed leukoencephalopathy after hypoxic-ischemic injury. *Arch Neurol.* 2008; 65(1):144–145. [PubMed: 18195154]
78. Nzwalo H, Sa F, Cordeiro I, Ferreira F, Basilio C. Delayed hypoxic-ischemic leukoencephalopathy. *BMJ Case Rep.* 2011:bcr0620114344.

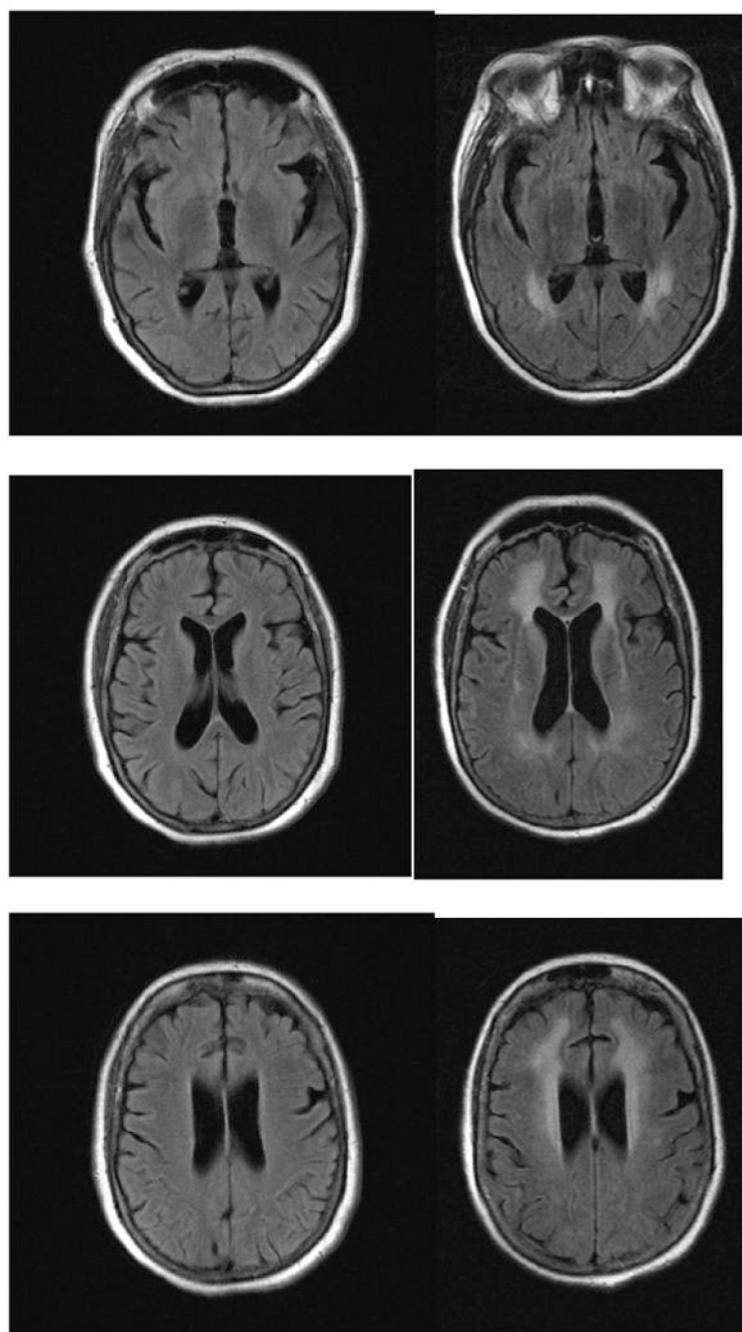


Figure 1.
Initial and 1-month brain MRIs (without contrast) in patient manifesting catatonic symptoms after respiratory failure. Angles of cut account for minor discrepancies in anatomy.

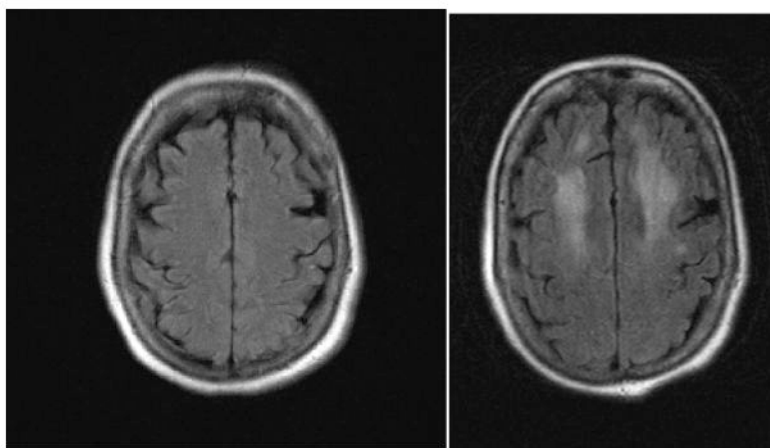


Figure 2.

Table 1

Case reports meeting DSM-5 criteria for catatonic features in delayed hypoxic leukoencephalopathy (3 or more of 12 features).(5,13,25,26,42,75-78)

Authors	Year	Age/Sex	Cause of Hypoxia	Lucid interval	Catatonic features	Neuroimaging	Treatment	Long-term outcome
Lee et al.	2001	71F	BZD	14 days	Stupor, stereotypy, mutism	B periventricular WM	Supportive care	Gait impairment
Cocito et al.	2005	62M	CO	20 days	Stupor, mutism, echolalia	B periventricular WM	Nimodipine, supportive care	Full recovery
Shprecher et al.	2008	51F	Methadone	21 days	Stupor, stereotypy, mutism	B hemispheric WM	Supportive care	Cognitive impairment
Chen-Plotkin et al.	2008	53F	Respiratory arrest	2 weeks	Stupor, mutism, posturing	B hemispheric WM	Supportive care	Cognitive impairment, physical impairment
Cottencin et al.	2009	38M	Methadone	15 days	Stereotypy, mutism, posturing, agitation	B subcortical WM, GP	Lorazepam, amilsulpride	Full recovery
Lou et al.	2009	62F	Anemia	2 weeks	Stupor, mutism, posturing	B subcortical WM, GP, SN	Levodopa, HBO	Cognitive impairment, physical impairment
Quinn et al.	2009	57F	CO	17 days	Stupor, stereotypy, mutism, posturing, grimacing	B frontal WM, GP	Lorazepam, dextroamphetamine	Cognitive impairment, physical impairment
Gheuens et al.	2010	49F	Methadone	"a few weeks"	Stupor, mutism, posturing	B frontal/parietal WM	Cognitive therapy	Cognitive impairment
Nzwalo et al.	2011	55F	BZD, heroin	12 days	Stupor, negativism, mutism	B subcortical, periventricular WM	Coenzyme Q10, baclofen, steroids	Minimally conscious

(BZD = benzodiazepine; CO = carbon monoxide; B = bilateral; WM = white matter; GP = globus pallidus; SN = substantia nigra; HBO = hyperbaric oxygen;

Table 2**Differential Diagnosis of Catatonia after Cerebral Hypoxia.**

Metabolic Derangements
Lactic acidosis
Carbon dioxide narcosis
Hypoxemia
Hypo/hyperglycemia
Renal ischemia/Uremia
Hepatic ischemia
Nutritional deficiency
Cardiovascular Complications
Hypotension
Hypertension
Anemia
Congestive heart failure
Myocardial infarction
Posterior reversible encephalopathy syndrome (PRES)
Infection
Meningo-encephalitis
Pneumonia/Aspiration
Urinary tract infection
Sepsis
HIV/Neurosyphilis
Toxin-related
Acute intoxication
Withdrawal
Toxic effect
Heroin/Opioids
Alcohol
Organic solvents
Immunosuppressants
Chemotherapy
Heavy metals
Stimulants
Radiation
Herbal extracts
Acute Cerebral Injury
Trauma
Axonal shearing
Intraparenchymal hemorrhage
Subdural/Epidural hematoma
Subarachnoid hemorrhage

Ischemia

Inflammation

Hypoxia

Basal ganglia/thalamus

Cerebellum

Brain stem

Hippocampus

Cortex

White matter

Delayed Neurological SyndromesM

Coma

Mutism

Parkinsonism

Apathy/Akinetic mutism

Dystonia

Chorea

Gait disturbance

Dementia

Psychiatric Disorders

Depression

Mania

Schizophrenia

Acute stress disorder/dissociation

Personality disorder

Conservation withdrawal

Table 3

Case reports of ECT after cerebral hypoxia. (50,54-56,63-66,68)

Authors	Year	Age/Sex	Cause of hypoxia	Time to ECT	Symptoms targeted by ECT	# ECT Type	Effective (Y/N)	Neurological complications	Long-term neurological outcome
Cavioto et al.	1960	57F	CO	23 days	Catatonia	10NR	N	No improvement of akinetic mutism	Death
Wajgt et al.	1971	25M	CO	3 days	Catatonia, psychosis	1NR	N	Coma, fever, neck stiffness	Death
Smith et al.	1975	53F	CO	11 days	Depression, psychosis	5RUL	N	Confusion, incontinence, spasticity	Dementia, parkinsonism
		58M	CO	2 days	Depression	6Bitemporal	N	Confusion, delusions, agitation	Dementia
		54F	CO	6 days	Depression	2NR	N	Confusion, ataxia, incontinence, spasticity	Mild dementia, ataxia
		73F	CO	2 days	Depression	5Bitemporal	N	Confusion, parkinsonism	Dementia, parkinsonism
Ginsburg et al.	1976	59F	CO	1 week	Depression	6NR	N	Stupor, mutism, posturing, shuffling gait	Dementia, parkinsonism
Sandson et al.	1987	32M	CO	8 days	Depression	1RUL	N	Confusion, disinhibition, ataxia, rigidity	Full recovery
Jerrett et al.	1995	59F	CO	4 years	Depression	9RUL	Y	None	Full recovery
Rasmussen et al.	2008	65F	Narcotics	~3 weeks	Catatonia	8Bitemporal	N	Confusion, muttering, agitation	Dementia, tremor
Yogarajam et al.	2011	46M	CO	NR	Depression	5NR	N	Confusion, unsteady gait, MMSE 11/30	Full recovery
Chiang et al.	2012	29M	CO, sedative	38 days	Depression	6Bitemporal	Y	None	Full recovery