

Growing Dissecting Aneurysm of Basilar Trunk Treated with Stent-assisted Coiling

Chao Fu, MSc, Conghai Zhao, MD, Hang Zhao, MD, Dongyuan Li, MD,
and Weidong Yu, MSc

Growing basilar dissecting aneurysm is a scarce but increasingly recognized entity, accounting for a significant risk of death and disability. Controversy exists regarding the optimal management. A 61-year-old man presented with dysarthria and left hemiparesis attributable to a basilar trunk dissecting aneurysm. Antiplatelet therapy was instituted, and the patient's clinical condition markedly improved. However, he developed severe headache, dysarthria, and left hemiparesis 35 days later. Angiography revealed significant enlargement of the aneurysm, and stent-assisted coiling was then uneventfully performed. The patient remained clinically stable with only mild left-sided hemiparesis at the 2-year clinical follow-up. **Key Words:** Basilar artery—dissecting aneurysm—endovascular treatment—stent-assisted coil embolization.

© 2015 by National Stroke Association

Introduction

Growing dissecting aneurysm involving the basilar artery (BA) is a rare but potentially life-threatening entity, representing a therapeutic challenge. The optimal treatment of this lesion remains controversial because its natural history has not yet been clearly understood. Generally, in cases presenting with brain stem ischemic symptoms, conservative management is preferred.¹⁻⁵ However, it is of note that the lesion is prone to precipitate progressive

neurologic deterioration associated with mass effect or subarachnoid hemorrhage, with a high risk of disability and mortality.^{2,3,5} Therefore, surgical or endovascular intervention should be recommended for patients in whom rupture or enlargement of the dissecting aneurysms was found.^{1,3,6}

We herein present a patient with progressive ischemic symptoms caused by a growing dissecting aneurysm of the basilar trunk, which was subsequently treated with stent-assisted coil embolization.

Case Report

A previously healthy 61-year-old man was initially admitted to another hospital with a sudden onset of dysarthria and left hemiparesis. There was no history of trauma or sudden brisk movements of the head and neck before symptom onset. Brain computed tomography revealed a prepontine clot compressing the midbrain, without significant subarachnoid spreading (Fig 1, A). He was referred to our hospital for further evaluation and management. Admission magnetic resonance imaging disclosed a right pontine infarct, the presence of an

From the Department of Neurosurgery, The Third Bethune Hospital (China-Japan Union Hospital), Norman Bethune Health Science Center of Jilin University, Changchun, Jilin Province, People's Republic of China.

Received April 19, 2014; revision received July 4, 2014; accepted July 28, 2014.

Address correspondence to Weidong Yu, MSc, Department of Neurosurgery, The Third Bethune Hospital (China-Japan Union Hospital), Norman Bethune Health Science Center of Jilin University, No. 126 Xiantai Street, Changchun 130033, Jilin Province, People's Republic of China. E-mail: fc616@126.com.

1052-3057/\$ - see front matter

© 2015 by National Stroke Association

<http://dx.doi.org/10.1016/j.jstrokecerebrovasdis.2014.07.033>

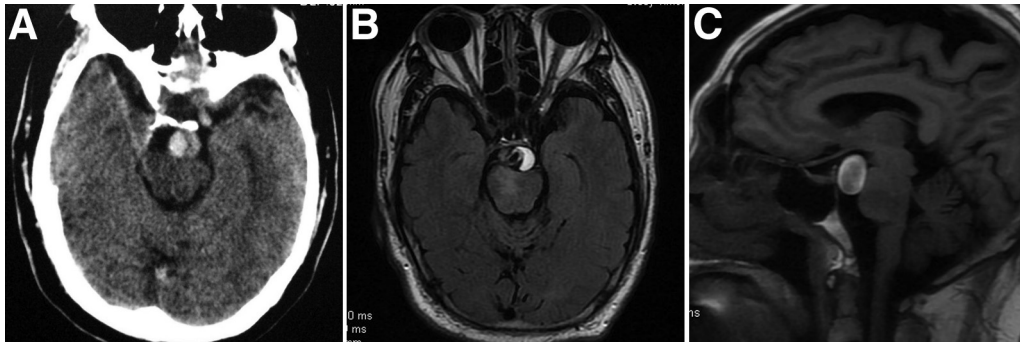


Figure 1. (A) Noncontrast computed tomography showed a high-density lesion in the prepontine cistern, without significant subarachnoid spreading. (B and C) Magnetic resonance imaging demonstrated an intimal flap with the double-lumen sign and a crescent-shaped thrombus within the false lumen compressing the brain stem, as well as a right pontine infarct.

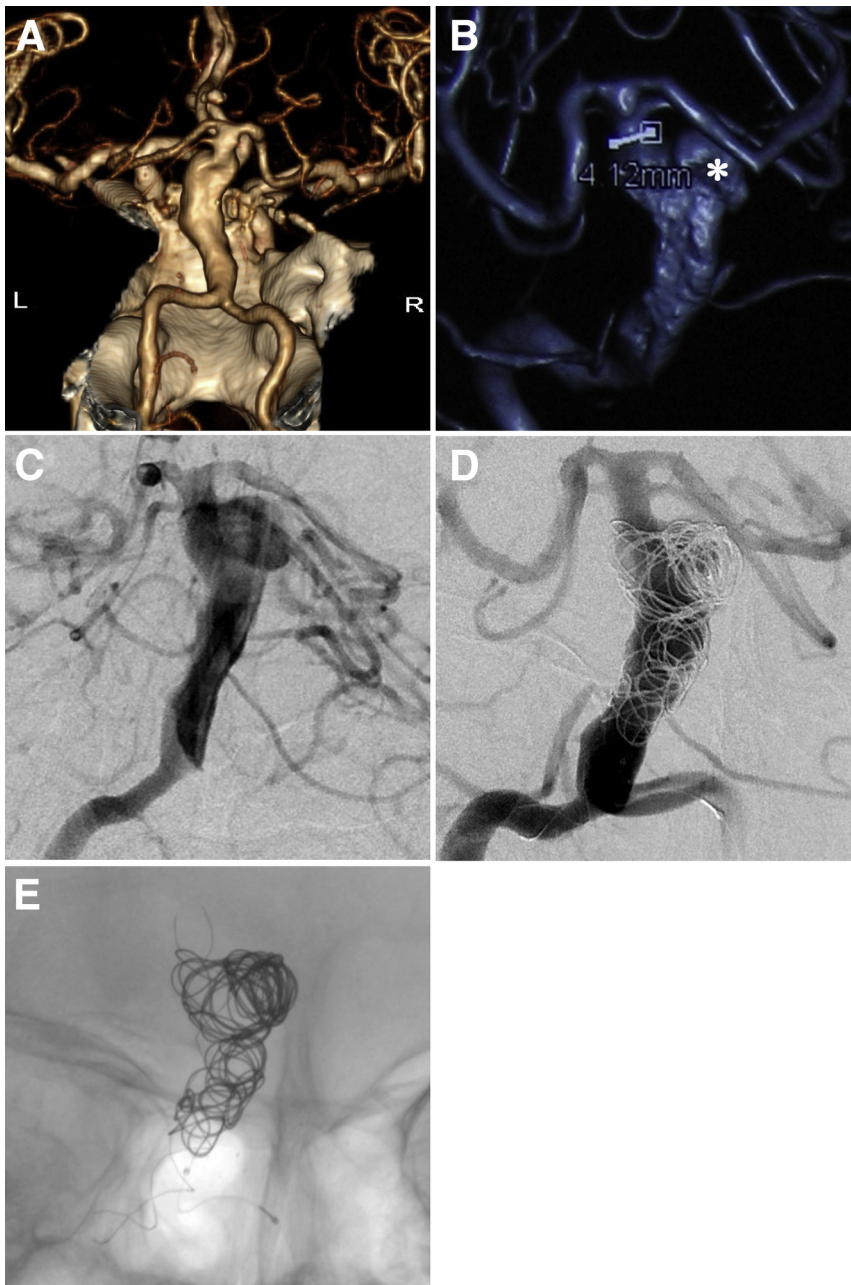
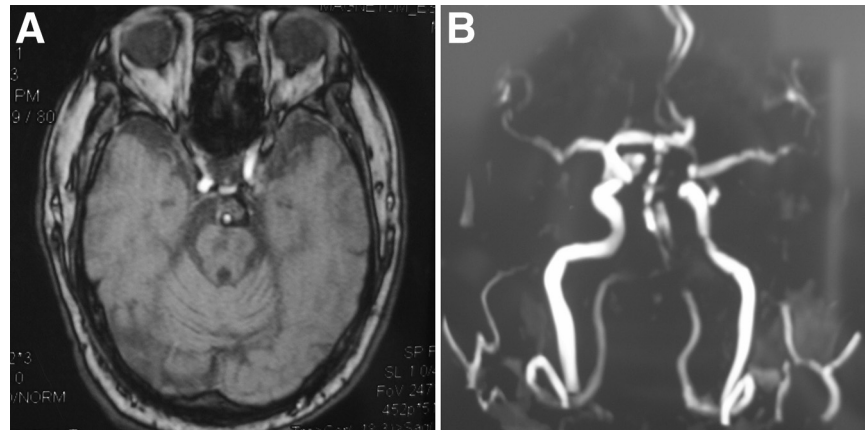


Figure 2. (A) Computed tomography angiography reconstruction showed a fusiform aneurysm involving the basilar trunk. (B and C) Three-dimensional and conventional vertebral angiograms revealed a remarkable enlargement of the basilar artery dissecting aneurysm (asterisk). (D and E) Angiography disclosed adequate occlusion of the aneurysm.

Figure 3. (A) Follow-up T1-weighted magnetic resonance imaging at 2 years showed a marked resolution of intraluminal thrombus without compression of the brain stem and multiple pontine infarcts. (B) Magnetic resonance angiography demonstrated patency of the basilar artery.



intimal flap with the “double-lumen” sign within the BA, and a crescent-shaped intraluminal thrombus compressing the brain stem (Fig 1, B,C). On computed tomography angiography, a large aneurysm with fusiform dilatation on the BA trunk was found (Fig 2, A). These findings were consistent with a diagnosis of basilar trunk dissecting aneurysm. Conservative treatment with antiplatelet therapy was instituted. His clinical condition gradually improved, and he was discharged on day 15.

However, the patient’s neurologic condition deteriorated on day 35 after the initial onset of symptoms. He was readmitted with severe headache, dysarthria, and left-sided hemiparesis. At that time, the size of the aneurysm was assumed to increase, and he was scheduled for stent-assisted coil embolization after obtaining the informed consent. He was preloaded with clopidogrel (75 mg) and aspirin (300 mg) daily for 3 days. The right and left femoral arteries were punctured with 6-French sheaths, under general anesthesia. The patient was administered 5000 units of heparin before microcatheterization, and the activated coagulation time was maintained at approximately 300 seconds throughout the procedure. The right and left vertebral arteries were catheterized with 6-French guiding catheters. Right vertebral angiography showed that the dissecting aneurysm had markedly enlarged (Fig 2, B,C). The dimension of the aneurysm was 13.5 mm × 36 mm. A Vasco 25 microcatheter (BALT Extrusion, Montmorency, France) was positioned through the right vertebral artery distally into the BA terminus via a Traxcess 14 guidewire (MicroVention, Tustin, CA). A 150-cm Headway microcatheter (MicroVention) was placed through the left vertebral artery to reach into the aneurysm sac via another Traxcess 14 guidewire; and thereafter, the aneurysm was obliterated with 4 detachable coils (10 mm/30 cm, 8 mm/30 cm, 7 mm/30 cm, and 6 mm/20 cm; Microplex 10; MicroVention, Aliso Viejo, CA). Subsequently, a 4.5 mm × 50 mm LEO self-expanding stent (BALT Extrusion) was delivered across the dissecting aneurysm via the Vasco 25 microcatheter. Finally, the stent was de-

ployed from the distal BA into the distal right vertebral artery, and the aneurysmal lumen appeared adequately occluded, with patency of the parent artery (Fig 2, D,E).

Low molecular weight heparin (nadroparin calcium, 0.4 IU, twice a day) treatment was administered in the first 3 postoperative days. His headache disappeared, and he was discharged on postoperative day 5. A 6-week course of clopidogrel (75 mg) was instituted; aspirin (100 mg) treatment was to be continued life long. Follow-up magnetic resonance imaging and magnetic resonance angiography at 2 years demonstrated multiple brain stem infarcts and remarkable resolution of wall hematoma without compressing the brain stem, as well as patency of the BA (Fig 3). No further treatment was given. The patient recovered well except for mild left hemiparesis.

Discussion

With the rapid development and widespread application of neuroimaging modalities, growing basilar dissecting aneurysms are becoming increasingly recognized. Although the exact mechanism contributing to this phenomenon has yet to be elucidated, fragmentation of the internal elastic lamina seems to be the primary pathogenic factor.^{2,5}

The natural history of this lesion remains poorly understood because of its rarity. As such, the appropriate treatment strategy has not yet been established. Three therapeutic options are currently available, including conservative management, surgery repair, and endovascular therapy. We conducted a thorough literature review and found 14 reported cases with growing basilar dissecting aneurysms verified by radiological evidence (Table 1).^{1-5,7-10} Among the 14 patients, as listed in the Table 1, conservative treatment was primarily considered in 13 patients. Unfortunately, of the 6 patients who solely managed by conservative treatment, 3 eventually died of subarachnoid hemorrhage, 2 died as a result of brain stem compression, and only 1 did well. In contrast, the patients

Table 1. Summary of reported cases with growing basilar dissecting aneurysms confirmed by radiological evidence

Year	Authors	Number of cases	Age (y), sex	Initial presentation	Treatment	Outcome	Follow-up duration (y)
1994	Takagi et al ⁷	1	59, M	SAH	Conservative → clipping	Resolution of symptoms postoperatively	?
1996	Mizutani et al ²	5	60, M	Brain stem infarct	Conservative	SAH → death	2
			42, M	VBI	Conservative	Good	3
			53, M	VBI	Conservative	SAH → death	6.5
			74, M	Hemifacial spasm	Conservative	Brain stem compression → death	9.5
			51, M	Brain stem infarct	Conservative	Brain stem compression → death	3
1997	Amin-Hanjani et al ⁸	1	45, F	SAH	Conservative → proximal basilar ligation	Good	>1
2002	Nabika et al ³	1	58, M	Brain stem ischemia	Conservative	SAH → death	6.5
2003	Ali et al ⁹	1	45, F	SAH	Conservative → left VA balloon occlusion → clipping	Good	2
2003	Nagashima et al ⁴	2	47, F	SAH	Right VA clip occlusion → stent-assisted coiling	Good	?
			70, M	Brain stem ischemia	Conservative → stent-assisted coiling	Basilar artery occlusion → death	?
2004	Jamous et al ⁵	1	45, M	Brain stem infarct	Conservative → stenting	Good	2
2008	Peluso et al ¹⁰	1	58, F	SAH	Conservative → stent-assisted coiling	Cognitive impairment, memory disturbances	0.5
2014	Gong et al ¹	1	48, F	SAH	Conservative → Pipeline embolization device	Good	0.5
2014	Present study	1	61, M	Brain stem infarct	Conservative → stent-assisted coiling	Good	2

Abbreviations: F, female; M, male; SAH, subarachnoid hemorrhage; VA, vertebral artery; VBI, vertebrobasilar insufficiency; ?, not mentioned.

who underwent surgical or endovascular intervention, as well as our case, were more likely to have a favorable outcome. Hence, in view of the poor natural history, surgical, or endovascular treatment should be judiciously considered when the patients develop progressive symptomatic deterioration attributable to rupture or enlargement of the aneurysms.^{1,3,6}

Clinically, open surgical repair of this entity is still challenging because of the complex anatomic environment and the fragile aneurysmal wall making it even more difficult to manipulate.^{1,6} There have been reported successful cases whose growing basilar dissecting aneurysms treated using surgical methods, including craniotomy for aneurysm clipping and proximal BA ligation with flow reversal.⁷⁻⁹ Nevertheless, the efficacy of the procedures remains unproven.

The stent-assisted coiling seems to be a feasible alternative treatment option for the dissecting aneurysms

involving the basilar trunk, while preserving the patency of the parent arteries.^{4,6,10} The stent served as a buttress allows for a higher packing density during coiling. This technique remodels the parent artery and redirects blood flow away from the aneurysm, which thereafter promotes thrombus formation within the aneurysm. Notably, the coils may herniate into the basilar trunk through the strut of stent, thereby resulting in fatal BA occlusion.⁴ Moreover, stent-alone treatment for such aneurysms has been previously reported, and the patient remained in good neurologic condition during the 2-year follow-up.⁵ Gong et al¹ recently reported a case of successful embolization of a growing dissecting aneurysm of basilar trunk by the Pipeline embolization device, a new-generation flow-diverting stent for neurovascular reconstruction. Contemporarily, in spite of a variety of interventional techniques and materials available to deal with such lesion, treatment decision should be made on a case-by-case basis.

In conclusion, serial angiography is necessary to monitor the growth of such dissecting aneurysms managed conservatively. Rupture or enlargement of the lesion should be advocated for positive surgical or endovascular intervention. Our case highlights that the stent-assisted coiling may be a potentially effective alternative to surgical therapy for this lesion.

References

1. Gong D, Yan B, Dowling R, et al. Successful treatment of growing basilar artery dissecting aneurysm by Pipeline flow diversion embolization device. *J Stroke Cerebrovasc Dis* 2014;23:1713-1716.
2. Mizutani T. A fatal, chronically growing basilar artery: a new type of dissecting aneurysm. *J Neurosurg* 1996;84:962-971.
3. Nabika S, Oki S, Migita K, et al. Dissecting basilar artery aneurysm growing during long-term follow up—case report. *Neurol Med Chir (Tokyo)* 2002;42:560-564.
4. Nagashima H, Hongo K, Matsumoto Y, et al. Clinical results and pathological findings of stent-assisted coil embolization for basilar artery trunk dissecting aneurysms. *Interv Neuroradiol* 2003;9:95-99.
5. Jamous MA, Satoh K, Matsubara S, et al. Ischemic basilar artery dissecting aneurysm treated by stenting only—case report. *Neurol Med Chir (Tokyo)* 2004;44:77-81.
6. Kim BM, Suh SH, Park SI, et al. Management and clinical outcome of acute basilar artery dissection. *AJNR Am J Neuroradiol* 2008;29:1937-1941.
7. Takagi M, Hirata K, Fujitsu K, et al. Unusual angiographic changes in a dissecting aneurysm of the basilar artery: case report. *Neurosurgery* 1994;34:356-358.
8. Amin-Hanjani S, Ogilvy CS, Buonanno FS, et al. Treatment of dissecting basilar artery aneurysm by flow reversal. *Acta Neurochir (Wien)* 1997;139:44-51.
9. Ali MJ, Bendok BR, Tella MN, et al. Arterial reconstruction by direct surgical clipping of a basilar artery dissecting aneurysm after failed vertebral artery occlusion: technical case report and literature review. *Neurosurgery* 2003;52:1475-1480.
10. Peluso JP, van Rooij WJ, Sluzewski M. Rapidly growing basilar dissecting aneurysm. *J Neurol Neurosurg Psychiatry* 2008;79:685.