

Flow control using Scepter™ balloons for Onyx embolization of a vein of Galen aneurysmal malformation

Raoul Pop · Monica Manisor · Valérie Wolff ·
Pierre Kehrli · Christian Marescaux · Rémy Beaujeux

Received: 8 October 2014 / Accepted: 20 October 2014 / Published online: 31 October 2014
© Springer-Verlag Berlin Heidelberg 2014

Abstract

Purpose We present a technical development of the endovascular treatment technique for vein of Galen aneurysmal malformation, using Onyx™ (ethylene vinyl alcohol copolymer) delivered under flow control through double-lumen balloon microcatheters.

Materials and methods An 11-month-old patient that initially presented with increasing head circumference was diagnosed with mural type vein of Galen aneurysmal malformation. Complete cure was obtained in a single endovascular treatment session. Onyx was delivered simultaneously through two double-lumen balloon microcatheters (Scepter™,

Microvention, Terumo Group). In both arterial feeders, balloon inflation occluded the high-flow arterial-venous shunting and thus facilitated the controlled propagation of the embolic product in the afferent artery and the shunt point while preventing distal migration into the venous system.

Results Two years post-procedure, MR imaging showed persistent occlusion of arterial-venous shunts with complete regression of the venous dilatation. On clinical examination, the patient had no neurological deficits, and no cognitive impairment was detected at neuropsychological testing.

Conclusion The use of double-lumen balloon microcatheters for flow control during delivery of Onyx represents a viable alternative for the endovascular treatment of vein of Galen aneurysmal malformations.

R. Pop (✉) · M. Manisor · R. Beaujeux
Interventional Neuroradiology Department, Hôpitaux Universitaires
de Strasbourg, Strasbourg, France
e-mail: pop.raoul@gmail.com

M. Manisor
e-mail: monicamanisor@yahoo.com

R. Beaujeux
e-mail: remy.beaujeux@chru-strasbourg.fr

R. Pop
Institut Hospitalo-Universitaire, Strasbourg, France

P. Kehrli
Neurosurgery Department, Hôpitaux Universitaires de Strasbourg,
Strasbourg, France
e-mail: pierre.kehrli@chru-strasbourg.fr

V. Wolff · C. Marescaux
Vascular Neurology Department, Hôpitaux Universitaires de
Strasbourg, Strasbourg, France

V. Wolff
e-mail: valerie.wolff@chru-strasbourg.fr

C. Marescaux
e-mail: christian.marescaux@chru-strasbourg.fr

Keywords Embolization · Vein of Galen malformation ·
Onyx

Introduction

Vein of Galen aneurysmal malformation (VGAM) is a rare congenital disease resulting from impaired development of the intracranial embryonic midline venous system at the level of the median prosencephalic vein—the embryonic precursor of the Galen vein. Multiple arterial-venous shunts are formed between choroidal feeders and the ectatic prosencephalic vein, which is usually disconnected from the internal cerebral veins [9]. Two main types are recognized—the mural type with one or more direct arterial-venous shunts; and the choroidal type, where multiple arterial feeders create a nidus-like structure that drains into the dilated venous pouch.

The clinical presentation varies according to the age of diagnosis [2, 4, 7, 9–11, 14]. The majority of cases diagnosed

in the neonatal or antenatal period will present signs of high-output cardiac failure due to high-volume blood shunting, whereas older children and adults present with increased head circumference, hydrocephalus, seizures, cognitive dysfunction and, rarely, subarachnoid hemorrhage.

During the last two decades, advances in endovascular treatment techniques have significantly improved the prognosis of VGAMs. The results of these procedures are now confirmed beyond immediate technical success, with up to 74 % of treated patients neurologically normal at long-term follow-up [2]. The vast majority of patients are currently being treated using n-Butyl cyanoacrylate (NBCA) and/or coils using a trans-arterial or transvenous approach [2, 4, 7, 10, 11, 14].

We report on an alternative for the endovascular treatment technique, which uses the newer liquid embolic agent Onyx™ (ethylene vinyl alcohol copolymer) delivered under flow control through double-lumen balloon microcatheters. To our knowledge, this is the first report of this method for the treatment of VGAM.

Patient description and proposed treatment technique

An 11-month-old male patient without any significant previous medical history was found to have an abnormal increase in cranial circumference during routine surveillance, associated with plateauing of the growth curves. On clinical examination, there were no neurological abnormalities and no signs of cardiovascular impairment. A brain MRI (Fig. 1) revealed an abnormal dilatation of the vein of Galen, measured at 2.1 cm in diameter. Angiographic sequences demonstrated arteriovenous shunting between this dilatation and branches of the left posterior cerebral artery (PCA), compatible with a diagnosis of vein of Galen aneurysmal malformation (VGAM). Moderate secondary tri-ventricular hydrocephalus was also observed.

Pretreatment angiographic evaluation (Fig. 2) confirmed a diagnosis of mural type VGAM. Direct arterial-venous shunts were observed between three separate arterial branches, and the dilated median prosencephalic vein that drains into the straight sinus: the posterior medial choroidal artery originating from the distal basilar trunk, the posterior lateral choroidal artery from the left P2 segment, as well as a smaller right posteromedial choroidal artery from the right P1 segment. A stenosis of approximately 60 % was seen in the initial part of the straight sinus. The venous drainage of the two cerebral hemispheres was redirected towards the superficial venous system.

Endovascular treatment technique

Under general anesthesia and therapeutic anticoagulation with continuous intra-venous heparin infusion, bilateral femoral

artery puncture was performed, with placement of two 4 French short pediatric sheaths. Subsequently, two 4 French long sheaths (Cook Medical Inc, Bloomington, USA) were placed in the left vertebral artery and the left common carotid artery (CCA) by using over-the-wire exchange techniques.

Through the introducer sheaths, two 4×10-mm double-lumen balloon microcatheters (Scepter™ Compliant Balloon, Microvention Europe, Saint-Germain-en-Laye, France) were navigated into the left posterior medial choroidal artery and the left posterior lateral choroidal artery, respectively (Fig. 3). Global angiographic runs through the left vertebral artery and left CCA were performed, to allow safe navigation and inflation of the balloons using roadmaps. The global runs were repeated after both balloons were inflated, in order to confirm complete occlusion of the respective arterial feeders. Super-selective injections performed under balloon inflation through the two microcatheters (Fig. 3) demonstrated a significantly reduced speed of arterial-venous passage through both arterial feeders. These angiographic runs also permitted the visualization of a branch supplying normal brain territory in the distal aspect of the left posterior lateral choroidal artery.

Keeping the balloons inflated, the embolic agent was injected simultaneously through the two microcatheters under fluoroscopic control (8 % Ethylene Vinyl Alcohol Copolymer—Onyx™ 34 (Ev3 Neurovascular, Irvine, CA)). Satisfactory occlusion of the two arterial-venous shunt points was obtained, as well as retrograde filling of the insertion point of the small contralateral choroidal feeder. During the initial injection, a minimal quantity of embolic product diffused distally in the straight sinus and right lateral sinus (Fig. 3). During the same injection, we could not avoid distal Onyx diffusion within the distal branch of the left posterior lateral choroidal artery, supplying normal brain territory (Fig. 3).

At the end of the procedure, global angiographic runs showed complete exclusion of the malformation with good patency of the left and right posterior cerebral arteries (Fig. 3). The total quantity of injected contrast material was restricted to 39.5 ml. A continuous intra-venous heparin infusion was administered for the first 48 h post intervention (titrated to obtain a twofold increase in activated partial thromboplastin time—aPTT) in order to prevent a thrombosis of the dilated venous pouch after an abrupt occlusion of arterial inflow. After 48 h, the IV treatment was switched to subcutaneous injections of fractionated heparin, continued for 2 weeks.

Results

Approximately 24 h after the intervention, the patient developed a transient motor deficit of the right upper extremity. An emergency brain MRI showed a small area of acute infarction

Fig. 1 Pre- and posttreatment MRI imaging. **a–c** Pretreatment MRI images: **a** Venous MRI angiography—direct arteriovenous shunting between branches of the left posterior cerebral artery and the vein of Galen aneurysmal malformation (VGAM) that drains into the straight sinus; **b** Native TOF angiography sequence—circulating aneurysmal dilatation of the median prosencephalic vein; **c** Sagittal T1 sequence showing the VGAM that drains into the straight sinus. **d–f** 1 year 11 months posttreatment MRI images: **d** Venous MRI angiography confirming complete exclusion of the VGAM; **e** Native TOF angiography; and **f** Sagittal T1 sequence with complete regression of the venous dilatation and artifact due to presence of embolic material in the arterial feeders (*white arrow head*)

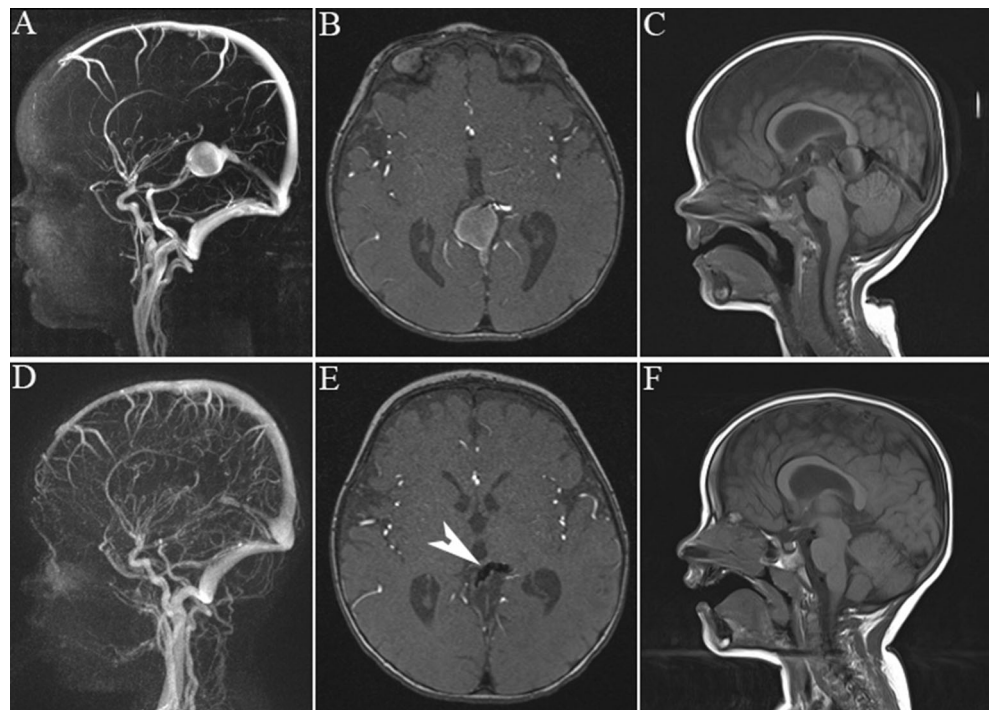


Fig. 2 Pretreatment angiography. **a–b** Right vertebral artery injections and **c–d** left internal carotid artery injections showing three separate arterial feeders of the VGAM: left posterior medial choroidal artery (1), left posterior lateral choroidal artery (2), right posterior medial choroidal artery (3). A venous outlet stenosis is observed in the proximal third of the straight sinus (4)

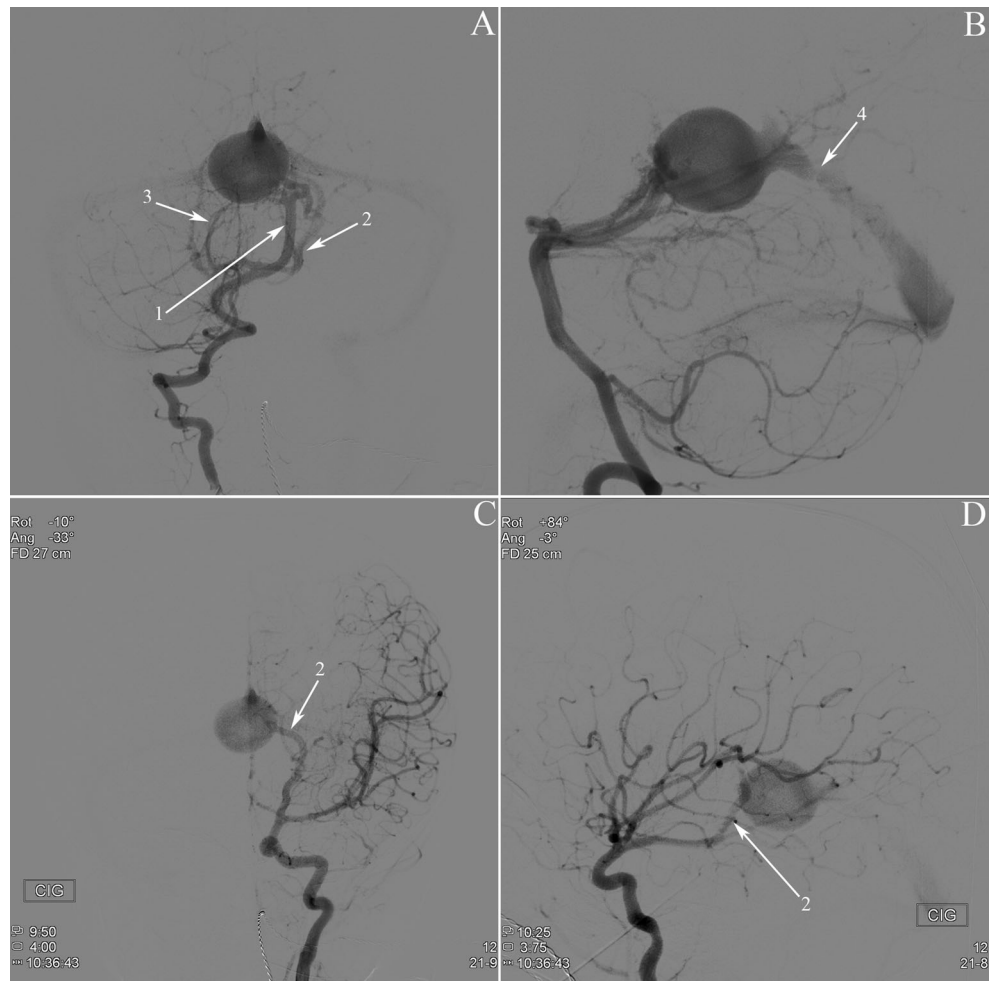
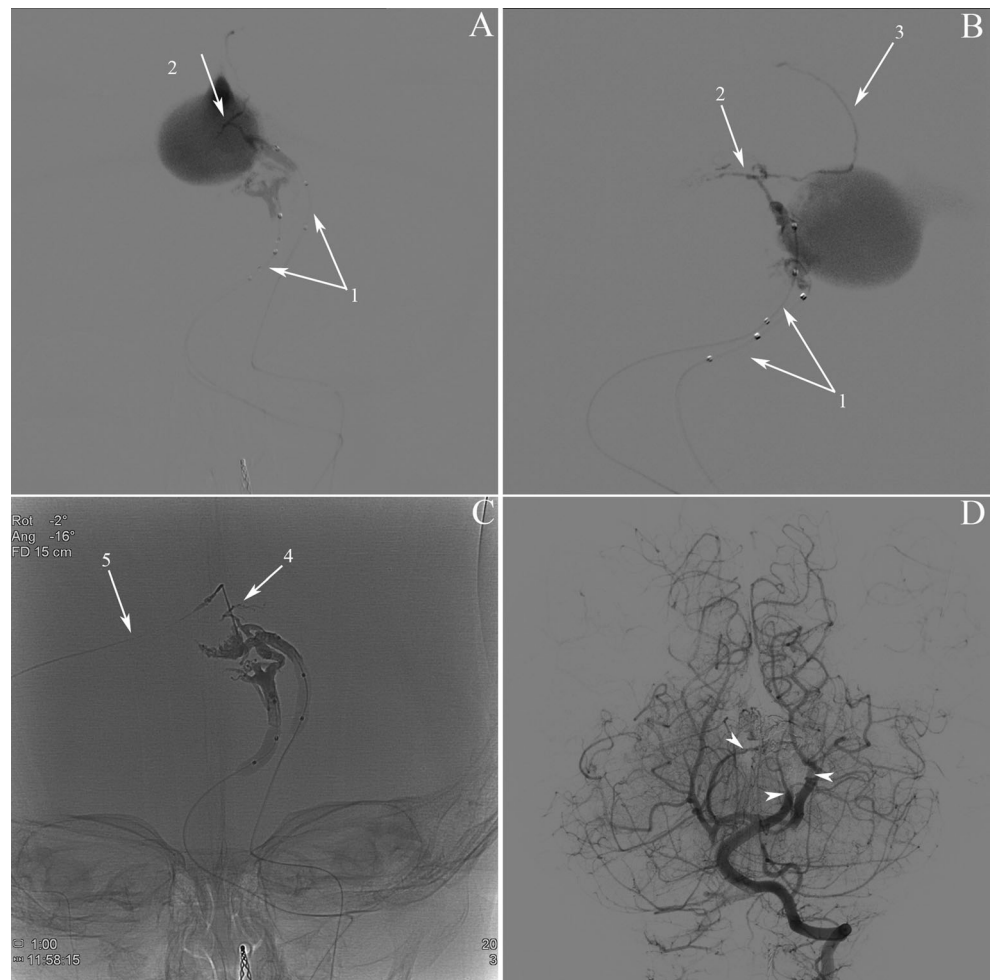


Fig. 3 Embolisation procedure. **a** Anteroposterior view and **b** lateral view of super-selective injections under double balloon inflation (1), showing significantly slowed arterial-venous passage. A distal branch supplying normal brain parenchyma is observed in the distal part of the left posterior lateral choroidal artery (2). This branch is anastomosed with the pericallosal artery (3) via a persistent embryonic limbic arterial circle; **c** non-subtracted images showing the final Onyx cast. Distal Onyx migration in the territory of the posterior lateral choroidal is observed (4). A small non-occlusive trace of embolic material is seen in the straight and right lateral sinus (5); **d** final left vertebral angiographic run at the end of the procedure, showing complete exclusion of the VGAM, with contrast stagnation in the three arterial feeders (arrow heads)



in the left posterolateral thalamus and posterior internal capsule, consistent with an ischemic lesion in the territory of the left posterior lateral choroidal artery. The motor deficit completely resolved within a few days.

Two years after the intervention, he is neurologically intact. Both head circumference and growth curves had normalized and no developmental delay was noted on neurocognitive evaluation. MRI imaging 1 year 11 months after the procedure (Fig. 1) confirmed persistent occlusion of all arterial-venous shunts, with complete regression of the aneurysmal malformation and good patency of the straight sinus.

Discussion

The presented case demonstrates the use of Onyx via a trans-arterial access for a mural type VGAM. The vast majority of patients are currently being treated with pure n-Butyl cyanoacrylate (NBCA) delivered through flow-directed microcatheters [2, 4, 7, 9–11, 14]. The use of Onyx in high-flow arterial-venous shunts that are often encountered in

VGAM, was limited mainly due to the product's tendency to diffuse distally into the venous system.

We believe that this problem can be overcome with the use of double-lumen balloons. Scepter™ (Microvention, Terumo Group) is a double-lumen balloon microcatheter designed specifically for neurovascular interventions and compatible with the use of Onyx and its solvent dimethyl sulfoxide (DMSO). Balloon inflation blocks the arterial inflow, consequently slowing or even stopping the arterial-venous passage of blood through the respective point of shunt. This will in turn significantly reduce the product's tendency to distal migration and allow for gradual progression of Onyx in the arterial feeder and in the point of arterial-venous shunt itself.

There are several theoretical advantages associated with the use of this system in comparison to NBCA glue. The main advantage, which has already made it the product of choice for brain arteriovenous malformations (AVMs), lies in its chemical properties—gradual precipitation allows it to diffuse and progressively infiltrate the tortuous anatomy of nidus-like structures. It also enables the operator to make use of longer and repeated injections through the same microcatheter with significantly less risk of catheter gluing to the vessel wall.

Combined with the control of arterial-venous flow obtained through balloon inflation, these properties make Onyx injections easier to control, in comparison with NBCA glue, especially with regards to venous passage.

A good example of this is seen in the presented case: although only two of the three arterial feeders were embolized, the product diffused on the wall of the venous dilatation and retrogradely occluded the insertion of the third and last arterial feeder (contralateral posterior medial choroidal artery). This allowed us to obtain a complete cure of the malformation in a single treatment session. We hypothesize that the use of this method can reduce the length and number of treatment sessions—an important factor when considering the potential adverse effects of multiple femoral punctures and cumulated dosimetric exposure in newborns and young children. This hypothesis needs to be confirmed in larger series of patients.

A second advantage consists of a lower risk of retrograde non-target embolization. The inflated balloon prevents the reflux of embolic product that could extend to normal arterial branches.

Moreover, the realization of global angiographic runs before embolization, while the balloons are temporarily inflated, allows for improved understanding of the vascular architecture of the malformation. Flow arrest in the catheterized arterial feeders facilitates the visualization of smaller afferences, venous drainage patterns as well as normal non-malformative vessels, by reducing the vascular steal phenomenon induced by high-flow arterial-venous passage. In our case, the selective injections under balloon inflation allowed us to visualize the normal brain supply in the distal aspect of the left lateral posterior choroidal artery (Fig. 3).

Various other methods of flow control to facilitate the delivery of embolic agents have been described. In a group of patients that included four VGAM [16], coiling of the arterial feeder was performed prior to the Onyx injection. Albuquerque et al. [1] describe a technique of retrograde catheterism of the arterial feeders through the venous side, followed by injections of Onyx, in a series that included one VGAM patient. Other authors report on more extreme measures of flow control, like the use of adenosine to induce cardiac stand-still during NBCA injection [17]. Double-lumen balloons offer an elegant alternative to these methods, with the added advantage of flexibility of placement and complete reversibility of flow arrest.

In a recently published article [5], Scepter balloons were used for delivery of Onyx in seven patients with intracranial and head and neck AVMs. The authors emphasize that balloon inflation during injections of Onyx increases their degree of nidal penetration by preventing retrograde reflux. In the context of VGAM, we used balloon inflation for a different purpose—to temporarily block the high-flow arterial-venous shunt and thus to obtain a slow and controlled diffusion of Onyx with less risk of distal venous migration. Whether the

desired effect is accelerating or slowing the penetration of Onyx, both papers show that flow manipulation with double-lumen balloons is a feasible technique that could improve the safety and efficacy of embolization procedures. Although several other papers described the use of this system for the treatment of peripheral and intracranial vascular malformations [3, 6, 8, 12, 13, 15], to our knowledge, the presented case is the first report of its use for the treatment of VGAM.

On the other hand, the use of the presented system involves additional risks when compared to the established method of NBCA glue embolization. Firstly, the vascular access system was more complex—we used two 4 French long sheaths placed at the origin of the vertebral and common carotid arteries, through which the balloons were navigated coaxially. The placement of the long sheaths involves an exchange maneuver and poses the risk of vessel dissection. However, the 4F long sheath that we used has a fairly soft and non-traumatic distal extremity that minimizes these risks, especially if placed proximally at the origin of the common carotid or vertebral artery. Moreover, we believe that the theoretically increased risk of local complications associated with bilateral femoral artery puncture in an infant was counterbalanced by the fact that we achieved complete cure in a single treatment session, thus avoiding further sessions and multiple arterial punctures.

Secondly, Scepter balloons are stiffer than the lower caliber, flow-guided microcatheters normally used for delivery of NBCA glue. This can render distal navigation in small arterial feeders more difficult, especially in case of marked vessel tortuosity. In the presented case, we did not encounter any difficulties for long sheath placement or for distal navigation. While the Scepter balloon with an outer diameter of 2.1 F (0.71 mm) can be introduced via a standard 4F diagnostic catheter, the ability to perform contrast injections is lost because of the too small discrepancy between the outer diameter of the balloon and the inner diameter of most catheters. This was the reason for which we chose to use long sheaths, which have a sufficient inner diameter that permits injections around the balloon microcatheter.

Thirdly, we need to mention the inherent risk of balloon inflation in a distal intracranial artery. There is a relatively little published experience on the use of dual-lumen balloons in distal intracranial arteries and very few cases in the pediatric population. To minimize the risks of vessel rupture, we performed balloon inflations under roadmap guidance. All roadmaps were obtained by performing proximal injections through the long sheaths.

Under balloon inflation we obtained an optimal diffusion of embolic product within the distal part of the arterial feeders and on the wall of the VGAM, with retrograde occlusion of a third arterial feeder and minimal distal venous migration. We could not avoid distal Onyx diffusion in the distal normal

branch of the posterior lateral choroidal artery. Arguably, this would have occurred even if pure NBCA glue would have been used, but this event could also be attributed to the increased chance of distal non-target embolization due to increased pressure of injection in the context of a wedged balloon catheter. By using the presented technique, we obtained complete cure of the malformation in a single treatment session, with an excellent clinical result on long term follow-up.

Conclusion

The use of double-lumen balloon microcatheters for flow control during delivery of Onyx represents a viable alternative for the endovascular treatment of vein of Galen aneurysmal malformations. In selected cases, this method can offer advantages in comparison with the classical method of NBCA glue embolization.

Conflict of interest The authors declare that they have no conflicts of interest.

Human rights and informed consent This article was written using retrospective data from anonymized patient files. No informed consent is needed.

References

- Albuquerque FC, Ducruet AF, Crowley RW, Bristol RE, Ahmed A, McDougall CG (2014) Transvenous to arterial Onyx embolization. *J Neurointerv Surg* 6(4):281–285
- Berenstein A, Fifi JT, Niimi Y, Presti S, Ortiz R, Ghatan S et al (2012) Vein of Galen malformations in neonates: new management paradigms for improving outcomes. *Neurosurgery* 70:1207–1214
- Dabus G, Linfante I, Martínez-Galdámez M (2014) Endovascular treatment of dural arteriovenous fistulas using dual lumen balloon microcatheter: technical aspects and results. *Clin Neurol Neurosurg* 117:22–27
- Gailloud P, O’Riordan DP, Burger I, Levrier O, Jallo G, Tamargo RJ et al (2005) Diagnosis and management of vein of Galen aneurysmal malformations. *J Perinatol* 25:542–551
- Jagadeesan BD, Grigoryan M, Hassan AE, Grande AW, Tummala RP (2013) Endovascular balloon-assisted embolization of intracranial and cervical arteriovenous malformations using dual-lumen coaxial balloon microcatheters and onyx: initial experience. *Neurosurgery* 73(ONS Suppl 2):ons238–ons243
- Jagadeesan BD, Mortazavi S, Hunter DW, Duran-Castro OL, Snyder GB, Siedel GF, Golzarian J (2014) Endovascular balloon-assisted embolization of high-flow peripheral vascular lesions using dual-lumen coaxial balloon microcatheter and onyx: initial experience. *J Vasc Interv Radiol* 25(4):587–592
- Khullar D, Andeejani AMI, Bulsara KR (2010) Evolution of treatment options for vein of Galen malformations. *J Neurosurg Pediatr* 6:444–451
- Kim ST, Jeong HW, Seo J (2013) Onyx embolization of dural arteriovenous fistula, using scepter C balloon catheter: a case report. *Neurointervention* 8(2):110–114
- Lasjaunias PL, Berenstein A, ter Brugge KG (2006) Surgical neuroangiography. 3rd volume—clinical and interventional aspects in children, 2nd edn. Springer, Berlin
- Lasjaunias PL, Chng SM, Sachet M, Alvarez H, Rodesch G, Garcia-Monaco R (2006) The management of vein of Galen aneurysmal malformations. *Neurosurgery* 59:S3184–S3194
- Li A, Armstrong D, ter Brugge KG (2011) Endovascular treatment of vein of Galen aneurysmal malformation: management strategy and 21-year experience in Toronto. *J Neurosurg Pediatr* 7:3–10
- Martínez-Galdámez M, Rodríguez-Arias CA, Utiel E, Arriba E, Gonzalo M, Arenillas JF (2014) Paraspinal arteriovenous malformation Onyx embolization via an Ascent balloon. *J Neurointerv Surg* 6(3):e19
- Paramasivam S, Niimi Y, Fifi J, Berenstein A (2013) Onyx embolization using dual-lumen balloon catheter: initial experience and technical note. *J Neuroradiol* 40(4):294–302
- Pearl M, Gomez J, Gregg L, Gailloud P (2010) Endovascular management of vein of Galen aneurysmal malformations. Influence of the normal venous drainage on the choice of a treatment strategy. *Childs Nerv Syst* 26:1367–1379
- Spiotta AM, Miranpuri AS, Vargas J, Magarick J, Turner RD, Turk AS et al (2013) Balloon augmented Onyx embolization utilizing a dual lumen balloon catheter: utility in the treatment of a variety of head and neck lesions. *J Neurointerv Surg*. doi:10.1136/neurintsurg-2013-010833
- Thiex R, Williams A, Smith E, Scott RM, Orbach DB (2010) The use of Onyx for embolization of central nervous system arteriovenous lesions in pediatric patients. *AJNR Am J Neuroradiol* 31:112–120
- Tsimpas A, Chalouhi N, Halevy JD, Tjoumakaris S, Gonzalez LF, Monteith SJ et al (2013) The use of adenosine in the treatment of a high-flow vein of Galen malformation in an adult. *J Clin Neurosci*. doi:10.1016/j.jocn.2013.11.014