

Early Diagnosis of Cerebral Ischemia in Cerebral Vasospasm by Oxygen-Pulse Near-Infrared Optical Topography

Yuichi Tanaka, Akira Ebihara, Masashi Ikota, Tomotaka Yamaguro, Haruna Kamochi, Gen Kusaka, Mami Ishikawa, Takehiko Konno, Toshihiro Mashiko, and Eiju Watanabe

Abstract Purpose: Early diagnosis of vasospasm is a key factor in the choice of treatment after subarachnoid hemorrhage (SAH). However, a noninvasive method of diagnosing delayed ischemic neurological deficit (DIND) has not been established. We therefore propose a new method of diagnosing cerebral ischemia using near-infrared optical topography (OT) with oxygen inhalation.

Materials and Methods: We used a 44-channel OT system that covers the bilateral frontotemporoparietal areas to assess 29 patients who underwent surgery within 72 h of the onset of SAH. The patients inhaled room air followed by oxygen for 2 min, and then peripheral oxygen saturation (SpO₂) was continuously monitored at the index fingertip. The patients were assessed by *N*-isopropyl-p-[¹²³I]iodoamphetamine (IMP)-SPECT and OT on the same day. Ischemic findings were confirmed using principal component analysis with reference to the systemic SpO₂ value.

Results: Seven of 29 patients developed DIND. Evidence of ischemia was identified by OT in all seven of these patients before the onset of DIND. The OT and SPECT findings agreed in 27 (93 %) of the 29 patients.

Discussion and Conclusions: Our method might detect cerebral ischemia before the onset of DIND and thus be clinically useful for assessing cerebral ischemia with vasospasm.

Keywords Near-infrared optical topography • Cerebral ischemia • Cerebral vasospasm • Oxygen inhalation • SPECT

Y. Tanaka (✉) • A. Ebihara • M. Ikota • T. Yamaguro
H. Kamochi • G. Kusaka • M. Ishikawa
Department of Neurosurgery,
Jichi Medical University Saitama Medical Center,
Saitama-Ken, Japan
e-mail: chinu@jichi.ac.jp

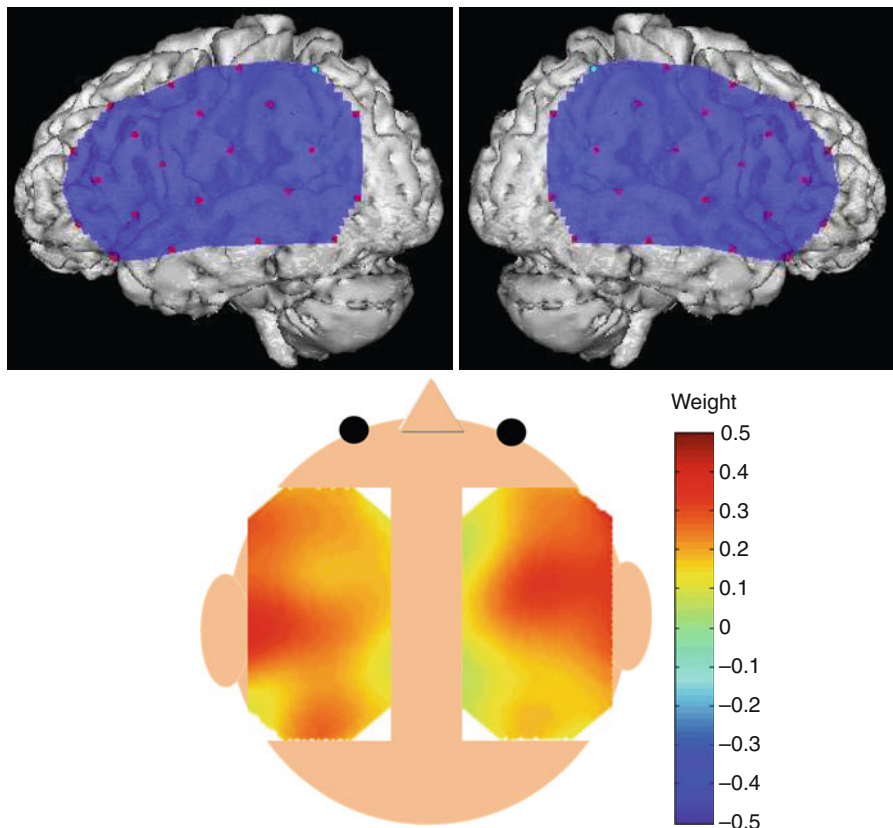
T. Konno • T. Mashiko • E. Watanabe
Department of Neurosurgery, Jichi Medical University,
Saitama-Ken, Japan

Introduction

Few drugs are available that can specifically and effectively treat cerebral vasospasm, which is a serious complication that affects the prognosis of subarachnoid hemorrhage (SAH). On the other hand, asymptomatic cerebral ischemia arises before delayed ischemic neurological deficits (DIND) manifest [8]. Therefore, the early diagnosis of cerebral ischemia caused by cerebral vasospasm is a key factor in the choice of treatment for cerebral vasospasm after SAH. However, a totally noninvasive diagnostic procedure for diagnosing cerebral ischemia caused by cerebral vasospasm has not yet been established. Cerebral hemodynamics are conventionally assessed using cerebral angiography, perfusion computed tomography (CT), magnetic resonance imaging angiography (MRA), single-photon emission computed tomography (SPECT), and positron emission tomography (PET). Although these modalities can evaluate cerebral perfusion deficits, they have several disadvantages, because they expose patients to physical stress and considerable invasiveness, and because assessment takes time [7, 14]. A less invasive method is needed that can repeatedly measure changes in cerebral hemodynamics, preferably at the bedside in real time.

Near-infrared spectroscopy (NIRS) can measure changes in the concentrations of oxygenated (HbOxy), deoxygenated (HbR), and total (HbTotal) hemoglobin in cerebral tissues, as well as changes in cerebral blood volume (CBV) [3–6, 12, 13]. Total hemoglobin is defined as the sum of HbOxy and HbR. Optical topography (OT) is a NIRS technique that provides spatial maps of hemodynamics and changes in oxygenation in cerebral tissues [6, 12, 13] and it is suitable for repeatedly measuring changes in cerebral oxygenation at bedside. We developed a new noninvasive method of diagnosing chronic cerebral ischemia using near-infrared OT with oxygen inhalation [2].

Fig. 1 Position of probes on brain surface and near infrared optical topogram of weight coefficients from a healthy volunteer



Materials and Methods

We assessed 29 patients with Hunt and Kosnik neurological grades 1–4 who were treated by surgical clipping or coiling at our hospital within 72 h of the onset of SAH between 2006 and 2010. Their average age was 53.9 years, and they had aneurysms located in the anterior cerebral (ACA; $n=17$), middle cerebral (MCA; $n=8$), internal carotid ($n=8$), and vertebral ($n=1$) arteries. Cerebral vasospasm in all patients was treated with fasudil and nitroglycerin for 14 days after clipping or coiling. Patients with acutely deteriorating DIND were assessed by cerebral angiography to determine whether an arterial infusion of fasudil would be beneficial. Cerebral ischemia caused by cerebral vasospasm was assessed in all patients using SPECT on days 6 or 8 and DIND was clinically diagnosed. Deterioration in consciousness level, the appearance of motor weakness, sensory deficits, or aphasia was defined as DIND if postoperative cerebral hematoma, hydrocephalus, recurrent SAH, and electrolyte disturbances were absent [9].

Measurement by OT and ^{123}I -IMP SPECT

The 29 patients were examined by OT on days 2, 4, 6, 8, 10, 12, and 14, and simultaneously by SPECT on days 6 or 8 on the same day as OT after the onset of SAH. The OT and *N*-isopropyl- p -[^{123}I]iodoamphetamine (^{123}I -IMP)-SPECT

findings on either day 6 or day 8 were compared to assess whether cerebral ischemia was identified.

Evaluation of Optical Topography

The patients were assessed using an ETG4000 continuous-wave OT system (Hitachi Medical Corporation, Tokyo, Japan). Near-infrared light rays with wavelengths of 695 and 830 nm were guided by optical fiber bundles and transmitted into the cranium. Reflections of near-infrared rays were detected by receiver probes positioned on the scalp at 30 mm from transmitter probes. Both the scalp and cerebral hemodynamics influence OT signals because near-infrared light is absorbed by hemoglobin in the extracerebral and cerebral tissues. However, changes in cerebral hemodynamics and oxygenation caused by manipulating the type of inhaled gas can be detected using settings similar to those applied herein [3, 10].

Changes in hemoglobin concentrations in areas of the MCA were measured in supine patients by placing the probes on the scalp to cover the bilateral frontotemporoparietal area (Fig. 1). Measurements proceeded with a response rate of 10 Hz.

Patients breathed through an OX-135 oxygen face mask (Atom Medical Corporation, Tokyo, Japan) and peripheral oxygen saturation (SpO_2) was measured at the tip of the index finger using an OLV 3100 SpO_2 monitor (Nihon Kodens Corporation, Tokyo, Japan). Air was delivered through the oxygen face mask at a flow rate of 8 L/min, and OT measurements were started.

After the OT values were stabilized, the patients inhaled air for 1 min, followed by oxygen at the same flow rate for 2 min, and then air once again at the same flow rate for 3 min. The SpO₂ changed in a trapezoidal manner under these conditions. Changes in HbOxy associated with oxygen inhalation in the cerebral tissues were measured using OT [1].

Analysis of OT Data

The time courses of HbOxy data were analyzed as follows. Data from OT were processed using MATLAB R14 (Math Works Inc., Natick, MA, USA) and principal component analysis (PCA) was applied to the data. Signal interference has been identified and removed from extracerebral tissues using this technique [11]. The weights are the coefficients of each channel for the synthesis of the principal component, and they reflect the degree to which the data in each channel contribute to the principal component data. Cross-correlations between each component and SpO₂ were calculated. The principal component with the highest correlation coefficient included changes in HbOxy associated with oxygen inhalation, and this was analyzed in detail. To evaluate the transmission of systemic SpO₂ changes to cerebral tissues, the weight coefficients of the principal components were calculated for each channel. Contour maps (topograms) were drawn using weight coefficients positioned at each measurement point (Fig. 1).

Evaluation of Cerebral Ischemia

The laterality of OT was determined by comparing the channel inspections in the symmetrical positions on the topogram. The side with a lower weight coefficient was defined as the ischemic side. Statistical significance was determined using the nonparametric Mann-Whitney *U* test. Differences with $P < 0.05$ were considered significant. Two neurosurgeons and two radiologists determined the ischemic side on SPECT images. The ischemic sides in OT and SPECT were compared, and the possibility of identifying cerebral ischemia was investigated. The ischemic side of OT was compared with those of SPECT, and two neurosurgeons investigated the possibility of identifying ischemic findings and ischemic sides.

Results

Table 1 shows the results of the 29 patients who were assessed by OT and ¹²³I-IMP SPECT on the same day. DIND developed in 7 (24 %) of the patients who had concurrent ischemic findings on both images. However, ischemia was detected on OT before DIND. Early ischemic findings were not evident in OT images of 10 patients, and none of them

developed DIND. In 22 patients who did not develop DIND, OT and ¹²³I-IMP SPECT image showed ischemic findings in 11 and 13 of them, respectively. Among the 13 patients with ischemic findings on ¹²³I-IMP SPECT images, 11 (84.6 %) were concurrent with those of OT and all 9 patients without ischemic findings on ¹²³I-IMP SPECT images also had no ischemic findings on OT images. Among the 22 patients who did not develop DIND, the findings on OT and ¹²³I-IMP SPECT agreed in 20 (90.9 %) of them. Among all 29 patients, ¹²³I-IMP SPECT and OT images showed ischemic findings in 20 and 18 of them, respectively, and the findings were concurrent in 18 (90 %) of the 20 patients with such findings on ¹²³I-IMP SPECT images. Among all 29 patients, 9 patients had no ischemic findings on either ¹²³I-IMP SPECT or OT images. In total, the presence or absence of ischemia on OT and ¹²³I-IMP SPECT images concurred in 27 (93.1 %) of the 29 patients.

Seven of the 20 patients with evidence of ischemia on SPECT images developed DIND, whereas 9 without such evidence did not. On the other hand, DIND did not develop in 10 patients without evidence of early ischemia on OT. Among 19 patients with evidence of early ischemia on OT, 7 (36.8 %) developed DIND, whereas the ischemic findings on OT improved in the remaining 12 (63.2 %) patients and DIND did not arise.

Case Presentation

A 59-year-old woman was admitted to our hospital with sudden onset of severe headache and disturbed consciousness. Assessment by CT revealed moderate SAH and cerebral angiography revealed an anterior communicating artery aneurysm, which was surgically clipped on day 1. Ischemic findings or brain damage caused by the surgery were not evident on postoperative CT images and her level of consciousness improved. Laterality was essentially absent on OT images on day 2 (Fig. 2a), but evidence of ischemia appeared in the left sides of the topogram (Fig. 2b) and of the SPECT images on day 6 (Fig. 2b). However, DIND had not yet developed at this point. We determined that ischemia caused by vasospasm had started and we enhanced the systemic therapy for cerebral vasospasm. The topogram on day 11 indicated improved ischemia (Fig. 2c) and the absence of DIND.

Discussion

We developed a new method of diagnosing chronic cerebral ischemia using OT with oxygen inhalation [2]. This method can repeatedly evaluate cerebral oxygenation and detect cerebral ischemia at the bedside. The present study aimed to

Table 1 Patient characteristics

Case no.	Age	Sex	AN	Op	DIND	Ischemic side		Early ischemia (OT)
						SPECT	OT	
1	35	M	Acom	Clip	-	N	N	-
2	62	F	MCA	Clip	-	R	R	+
3	63	F	Acom	Clip	+	L	L	+
4	40	M	MCA	Clip	-	R	N	+
5	52	F	ACA	Clip	-	L	L	+
6	24	M	ACA	Clip	-	N	N	-
7	63	F	ACA	Clip	-	N	N	-
8	51	F	MCA	Clip	+	R	R	+
9	55	F	MCA	Clip	-	R	R	+
10	65	F	ACA	Clip	+	L	L	+
11	51	F	MCA	Clip	-	N	N	-
12	60	F	ACA	Clip	-	L	L	-
13	57	F	MCA	Clip	-	N	N	-
14	45	M	ICA	Coil	-	N	N	-
15	47	F	ACA	Clip	-	R	R	+
16	70	F	ICA	Clip	-	L	L	+
17	57	M	ACA	Clip	-	N	N	+
18	54	M	ACA	Clip	-	N	N	-
19	66	F	VA	Clip	-	N	N	-
20	55	F	MCA	Clip	+	L	L	+
21	51	M	ACA	Clip	+	R	R	+
22	53	F	ACA	Clip	-	L	L	+
23	78	F	ICA	Coil	-	R	R	+
24	45	F	ACA	Clip	-	R	R	+
25	61	F	ACA	Clip	+	R	R	+
26	34	M	ACA	Clip	+	L	L	+
27	56	M	MCA	Clip	-	R	R	+
28	52	F	ACA	Clip	-	R	R	+
29	61	F	ACA	Clip	-	R	N	-

Columns labeled SPECT, OT, and Early ischemia (OT) indicate side with cerebral ischemia in each modality

ACA anterior cerebral artery, Acom anterior communicating artery, AN aneurysm, *Early ischemia (OT)* early ischemic finding on OT, F female, ICA internal carotid artery, L left, M male, MCA middle cerebral artery, N no laterality, Op operation, OT optical tomography, R right, SPECT single-photon emission computed tomography, VA vertebral artery

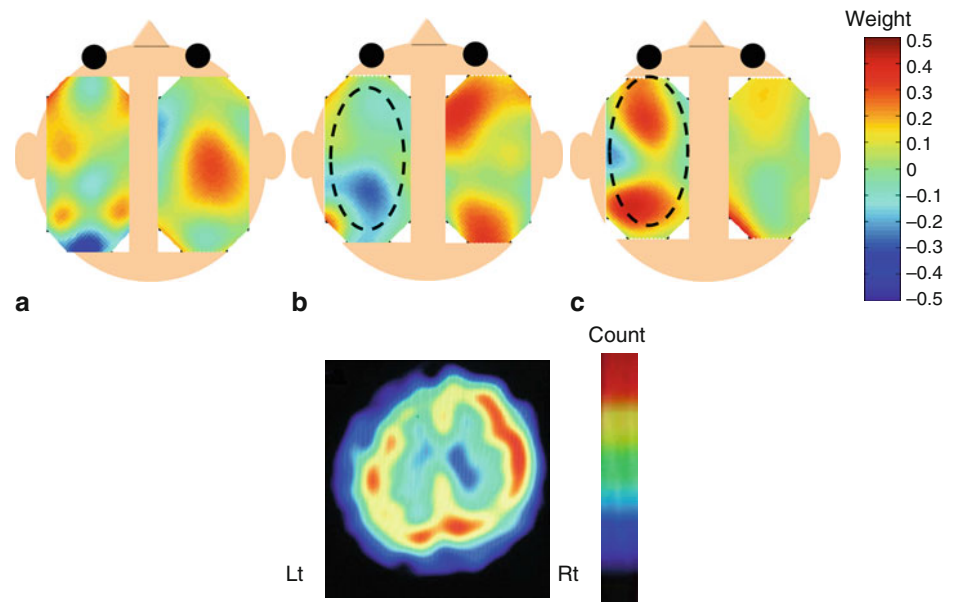
determine whether OT with oxygen inhalation can detect acute cerebral ischemia caused by cerebral vasospasm before the onset of DIND.

The concentration of HbOxy in cerebral tissue increases under oxygen inhalation and decreases under room air inhalation. However, concentrations of HbOxy induced by oxygen inhalation change less in ischemic than in normal regions [2]. We developed a new method of diagnosing chronic cerebral ischemia using OT with oxygen inhalation [2]. This method detects changes in the HbOxy concentration of brain tissue, and thus chronic cerebral isch-

emia in patients with conditions such as unilateral internal carotid artery occlusion [2].

Here, we investigated whether our method could detect acute ischemic states caused by cerebral vasospasm before the onset of DIND. We assessed 29 patients by OT and CT on either day 6 or day 8 after surgery within 72 h of the onset of SAH. We investigated the occurrence of DIND and the detection of early ischemia on OT images from all 29 patients. We found DIND in seven of them and the OT and SPECT findings of ischemia agreed in all of them. Early ischemic findings were detected by OT before DIND devel-

Fig. 2 Optical topograms of patient 1 on days 2, 6, and 10, and SPECT on day 6. Laterality of weight coefficients is essentially absent on day 2 (a). Ischemic findings are evident in the left frontal lobe on OT (dotted circle) and in SPECT (b). Ischemic findings on day 10 are improved by additional enhanced treatment for cerebral vasospasm (dotted circle) (c)



oped in these seven patients. Ten patients with no evidence of ischemia on OT images did not develop DIND. These results suggest that OT could detect cerebral ischemia before the onset of DIND and as well as SPECT after the onset of DIND. On the other hand, DIND did not occur in the other 22 patients. Among these 22 patients, ischemic findings were evident on ^{123}I -IMP SPECT images from 13 of them, 11 (84.6 %) concurred with those of OT. However, OT did not detect ischemic findings in two patients. These results suggest that the sensitivity of detecting cerebral ischemia is lower for OT than for SPECT [2]. Among the 22 patients who did not develop DIND, the findings on OT and ^{123}I -IMP SPECT concurred in 20 (90.9 %) of the cases. In total, the findings on OT and ^{123}I -IMP SPECT concurred in 27 (93.1 %) of the 29 patients. This 93.1 % rate of diagnostic agreement with SPECT suggests that our method could help to diagnose cerebral ischemia during the acute phase of SAH.

Optical topography uncovered evidence of ischemia in 19 patients, among whom 7 developed DIND. However, ischemic findings improved in 12 (63 %) of the 19 patients because of additional enhanced treatment, and none of them developed DIND. Thus, enhanced treatment for vasospasm improved ischemia in 63 % of patients in whom OT detected early ischemic findings and DIND consequently did not develop. These results suggest that the enhanced systemic treatment for vasospasm that started soon after OT prevented DIND. However, ischemic findings did not improve in the remaining seven (37 %) patients despite additional treatment and all of them developed DIND.

Our method could detect ischemia before DIND occurred and 63 % of patients in whom ischemia was detected by OT received enhanced treatment for vasospasm and did not develop DIND. These results suggest that our method could be applicable to the early diagnosis of cerebral ischemia caused by vasospasm.

Conclusion

We developed a practical method of detecting cerebral oxygenation that could detect cerebral ischemia and identify its location before DIND onset. Thus, the method might be clinically applicable as a real-time, noninvasive means of assessing cerebral ischemia with a view to treating cerebral vasospasm.

Conflict of Interest Statement We declare that we have no conflict of interest.

References

- Cooper RJ et al (2012) The utility of near-infrared spectroscopy in the regression of low-frequency physiological noise from functional magnetic resonance imaging data. *Neuroimage* 59(4):3128–3138
- Ebihara A, Tanaka Y, Konno T, Kawasaki S, Fujiwara M, Watanabe E (2012) Evaluation of cerebral ischemia using near-infrared spectroscopy with oxygen inhalation. *J Biomed Opt* 17(9):096002
- Germon TJ et al (1998) Sensitivity of near infrared spectroscopy to cerebral and extra-cerebral oxygenation changes is determined by emitter-detector separation. *J Clin Monit Comput* 14:353–360
- Hillman EM et al (2007) Optical brain imaging in vivo. Techniques and applications from animal to man. *J Biomed Opt* 12(5):051402
- Kannan RP et al (2002) Non-invasive assessment of language lateralization by transcranial near-infrared optical topography and functional MRI. *Hum Brain Mapp* 16(3):183–189
- Koh PH, Elwell CE, Delpy DT (2009) Development of a dynamic test phantom for optical topography. *Adv Exp Med Biol* 645:141–146
- Komiyama M et al (1998) Prospective analysis of complications of catheter cerebral angiography in the digital subtraction angiography and magnetic resonance era. *Neurol Med Chir* 38(9):534–540
- Ohkuma H, Suzuki A, Habler O et al (2003) Cortical blood flow during cerebral vasospasm after aneurysmal subarachnoid hemorrhage: three-dimensional N-isopropyl-[^{123}I]iodoamphetamine single photon emission CT findings. *AJNR Am J Neuroradiol* 24:444–450
- Shibuya M et al (1992) Effect of AT 877 on cerebral vasospasm after aneurysmal subarachnoid hemorrhage. *J Neurosurg* 76(4):571–577

10. Terborg C et al (2003) Non invasive monitoring of cerebral oxygenation during vasomotor reactivity tests by a new near-infrared spectroscopy device. *Cerebrovasc Dis* 16(1):36–41
11. Virtanen J, Nojonen T, Merilainen P (2009) Comparison of principal and independent component analysis in removing extracerebral interference from near-infrared spectroscopy signals. *J Biomed Opt* 14(5):054032
12. Watanabe E et al (1996) Non-invasive functional mapping with multi-channel near infra-red spectroscopic topography in humans. *Neurosci Lett* 205(1):41–44
13. Watanabe E et al (2000) Noninvasive cerebral blood volume measurement during seizures using multichannel near-infrared spectroscopic topography. *J Biomed Opt* 5(3):287–290
14. Wintermark M et al (2005) Accuracy of dynamic perfusion CT with deconvolution in detecting acute hemispheric stroke. *AJNR Am J Neuroradiol* 26(1):104–112