

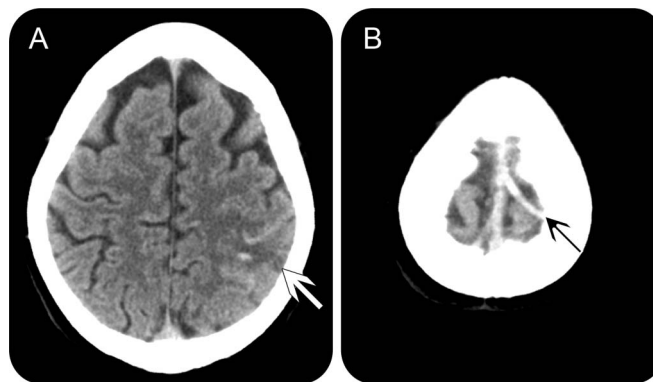
# Teaching NeuroImages:

## Magnetic resonance susceptibility effect for acute isolated cortical vein thrombosis

Slaven Pikija, MD  
Peter Unterkreuter, MD  
Michael Knoflach, MD

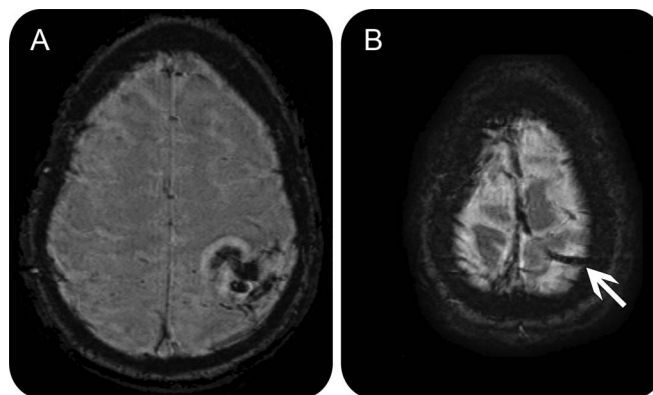
Correspondence to  
Dr. Pikija:  
spikija@gmail.com

**Figure 1** Baseline noncontrast CT scan



Axial CT scan shows subtle hemorrhagic infarction in left parietal region (white arrow; A) with associated hyperdense cortical vein (black arrow; B).

**Figure 2** MRI susceptibility-weighted imaging 15 hours after onset



Axial MRI with susceptibility-weighted imaging shows magnetic susceptibility effect in left parietal area (A) and ipsilateral cortical vein (arrow; B). MRI time-of-flight venography was negative (not shown).

A 38-year-old woman using hormonal contraception presented with right-sided abdominal and arm clonic seizures, right hemiparesis, hypesthesia, and nausea. She denied headache. D-dimers were 350 ng/mL (laboratory reference  $\leq 500$  ng/mL). CT showed a small left parietal hemorrhagic infarct with adjacent hyperdense cortical vein (figure 1). MRI 15 hours

after onset showed magnetic susceptibility effect on susceptibility-weighted imaging (SWI, figure 2). Isolated cortical vein thrombosis is present in 5% of patients with cerebral venous thrombosis (CVT).<sup>1</sup> Negative D-dimer and absence of headache does not exclude CVT<sup>1</sup> and SWI is useful for confirmation of the diagnosis.<sup>2</sup>

Download teaching slides:  
[Neurology.org](http://Neurology.org)

From the Department of Neurology (S.P., P.U.), Bezirkskrankenhaus Lienz; and the Department of Neurology (M.K.), Innsbruck Medical University, Austria.

Go to [Neurology.org](http://Neurology.org) for full disclosures. Funding information and disclosures deemed relevant by the authors, if any, are provided at the end of the article.

## AUTHOR CONTRIBUTIONS

Slaven Pikija: drafting/revising the manuscript, study concept or design, analysis or interpretation of data, accepts responsibility for conduct of research and final approval, contribution of vital reagents/tools/patients, acquisition of data, study supervision. Peter Unterkreuter: drafting/revising the manuscript, accepts responsibility for conduct of research and final approval, contribution of vital reagents/tools/patients, acquisition of data. Michael Knoflach: drafting/revising the manuscript, study concept or design, analysis or interpretation of data, accepts responsibility for conduct of research and final approval, study supervision.

## STUDY FUNDING

No targeted funding reported.

## DISCLOSURE

The authors report no disclosures relevant to the manuscript. Go to [Neurology.org](http://Neurology.org) for full disclosures.

## REFERENCES

1. Boukobza M, Crassard I, Bousser MG, et al. MR imaging features of isolated cortical vein thrombosis: diagnosis and follow-up. *AJNR Am J Neuroradiol* 2009;30:344–348.
2. Idbaih A, Boukobza M, Crassard I, et al. MRI of clot in cerebral venous thrombosis: high diagnostic value of susceptibility-weighted images. *Stroke* 2006;37:991–995.

# Neurology<sup>®</sup>

## Teaching *NeuroImages*: Magnetic resonance susceptibility effect for acute isolated cortical vein thrombosis

Slaven Pikija, Peter Unterkreuter and Michael Knoflach

*Neurology* 2014;83:e178-e179

DOI 10.1212/WNL.0000000000000988

**This information is current as of November 10, 2014**

<b>Updated Information &amp; Services</b>	including high resolution figures, can be found at: <a href="http://www.neurology.org/content/83/20/e178.full.html">http://www.neurology.org/content/83/20/e178.full.html</a>
<b>Supplementary Material</b>	Supplementary material can be found at: <a href="http://www.neurology.org/content/suppl/2014/11/08/WNL.0000000000000988.DC1.html">http://www.neurology.org/content/suppl/2014/11/08/WNL.0000000000000988.DC1.html</a>
<b>References</b>	This article cites 2 articles, 2 of which you can access for free at: <a href="http://www.neurology.org/content/83/20/e178.full.html##ref-list-1">http://www.neurology.org/content/83/20/e178.full.html##ref-list-1</a>
<b>Subspecialty Collections</b>	This article, along with others on similar topics, appears in the following collection(s): <b>All Cerebrovascular disease/Stroke</b> <a href="http://www.neurology.org/cgi/collection/all_cerebrovascular_disease_stroke">http://www.neurology.org/cgi/collection/all_cerebrovascular_disease_stroke</a> <b>All Epilepsy/Seizures</b> <a href="http://www.neurology.org/cgi/collection/all_epilepsy_seizures">http://www.neurology.org/cgi/collection/all_epilepsy_seizures</a> <b>Stroke in young adults</b> <a href="http://www.neurology.org/cgi/collection/stroke_in_young_adults">http://www.neurology.org/cgi/collection/stroke_in_young_adults</a>
<b>Permissions &amp; Licensing</b>	Information about reproducing this article in parts (figures, tables) or in its entirety can be found online at: <a href="http://www.neurology.org/misc/about.xhtml#permissions">http://www.neurology.org/misc/about.xhtml#permissions</a>
<b>Reprints</b>	Information about ordering reprints can be found online: <a href="http://www.neurology.org/misc/addir.xhtml#reprintsus">http://www.neurology.org/misc/addir.xhtml#reprintsus</a>

*Neurology*® is the official journal of the American Academy of Neurology. Published continuously since 1951, it is now a weekly with 48 issues per year. Copyright © 2014 American Academy of Neurology. All rights reserved. Print ISSN: 0028-3878. Online ISSN: 1526-632X.

