

# Isolated Left Homonymous Hemianopia Secondary to a Pericatheter Cyst—A Rare Presentation of a Ventriculoperitoneal Shunt Failure

Jordan D. Watkins, PA-C, MSPAS, Janet Lee, MD, MPH, Meagan J. Van Engen, MPH, McKenzie L. Tibbs, Dilantha B. Ellegala, MD, Joyce S. Nicholas, PhD

**Abstract:** A 26-year-old woman developed a left homonymous hemianopia 1 week after placement of a ventriculoperitoneal shunt through a right parieto-occipital approach. Computed tomography demonstrated a parenchymal cyst in the right occipital lobe. After shunt revision, there was concomitant resolution of the cyst and visual field defect over 1 month. The literature is reviewed regarding this unusual complication of ventriculoperitoneal shunt failure.

**Journal of Neuro-Ophthalmology** 2015;35:60–64

doi: 10.1097/WNO.0000000000000189

© 2014 by North American Neuro-Ophthalmology Society

**H**ydrocephalus is a common problem after subarachnoid hemorrhage (SAH) often requiring permanent cerebrospinal fluid (CSF) diversion (1). Obstruction is the most common cause of shunt failure with the most common site located intracranially (2). Signs and symptoms of increased intracranial pressure after shunt failure include headache, nausea, vomiting, and ataxia. Neuro-ophthalmic findings included diplopia, upward gaze palsy, and papilledema. We report a patient who developed a reversible homonymous hemianopia as a rare complication of shunt failure.

## CASE REPORT

A 26-year-old woman had an SAH secondary to a ruptured posterior communicating artery aneurysm. Computed tomography (CT) of the head showed dense SAH with intraventricular hemorrhage (IVH) and Hunt/Hess score

was 3 at the time of admission. The patient underwent clipping of the aneurysm with placement of an external ventricular drain (EVD). Postoperatively, she was oriented and followed commands and consistently drained high volumes of CSF. Once the IVH had cleared, the patient was weaned off EVD. However, she complained of persistent and worsening headache, which improved when the EVD was opened. Twenty-one days after SAH, the patient underwent an uncomplicated right parieto-occipital ventriculoperitoneal shunt with the peritoneal catheter placed under direct visualization and a Strata valve set at 1.0. Before discharge to a rehabilitation facility, physical examination revealed the patient to be neurologically intact, and CT showed the ventricular catheter in satisfactory position (Fig. 1).

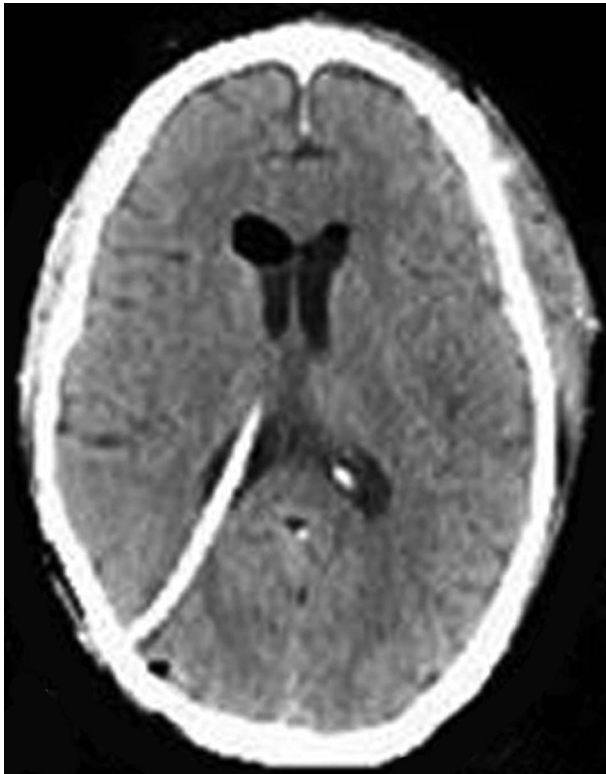
One week later, the patient returned for routine follow-up and reported a new visual disturbance for less than 1 day. She denied nausea, ataxia, or headache and was afebrile with a supple neck. Pupils were equal and reactive to light, and extraocular movements were full. Visual field testing revealed a left homonymous hemianopia (Fig. 2), and ophthalmoscopy was normal. The remainder of the neurologic examination was unremarkable.

Brain CT demonstrated a new cystic area surrounding the right ventricular catheter measuring 38 × 51 mm (Fig. 3). There was no significant ventriculomegaly or transpendymal flow and brain magnetic resonance imaging did not show evidence of infarction. An abdominal radiograph revealed the distal shunt catheter coiled in the right upper quadrant (Fig. 4). The patient underwent revision of the distal catheter, and 40–50 mL of CSF under high pressure were drained once the abdominal incision was opened. The shunt catheter was found to be coiled in the subcutaneous space. The peritoneal cavity was explored to ensure that there were no adhesions or pseudocyst, and the catheter was repositioned in the peritoneal space.

Centra Neuroscience Institute, Lynchburg, Virginia.

The authors report no conflicts of interest.

Address correspondence to Joyce S. Nicholas, PhD, 1901 Tate Springs Road, Lynchburg, VA 24501; E-mail: joyce.nicholas@centrahealth.com

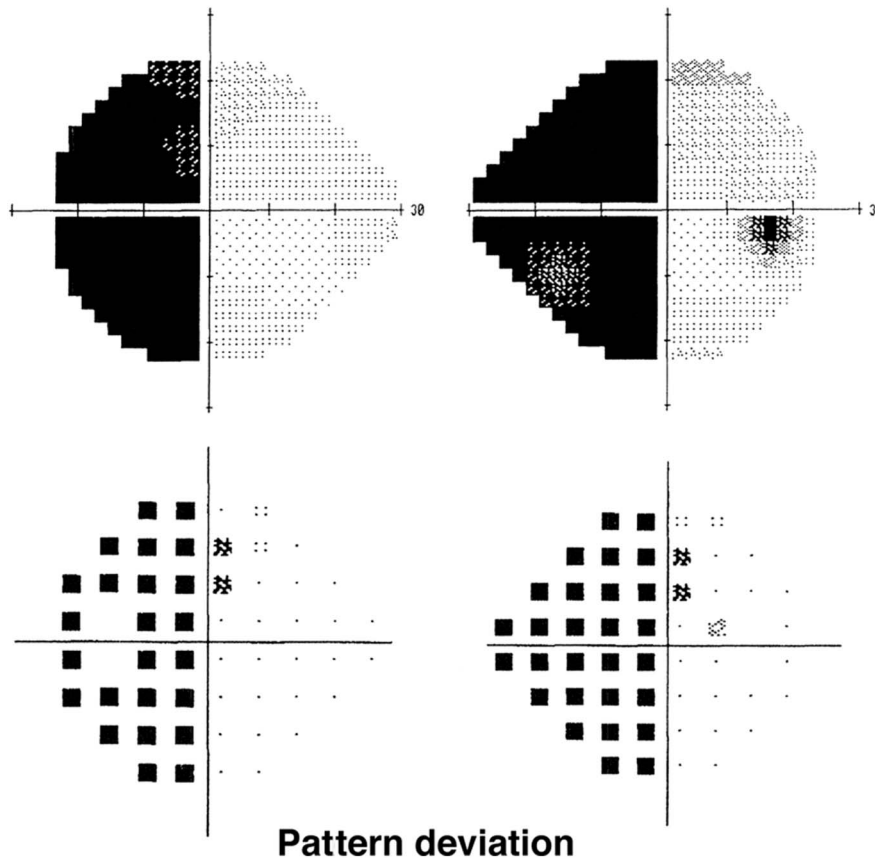


**FIG. 1.** Computed tomography 1 day after surgery shows satisfactory placement of ventriculoperitoneal shunt catheter.

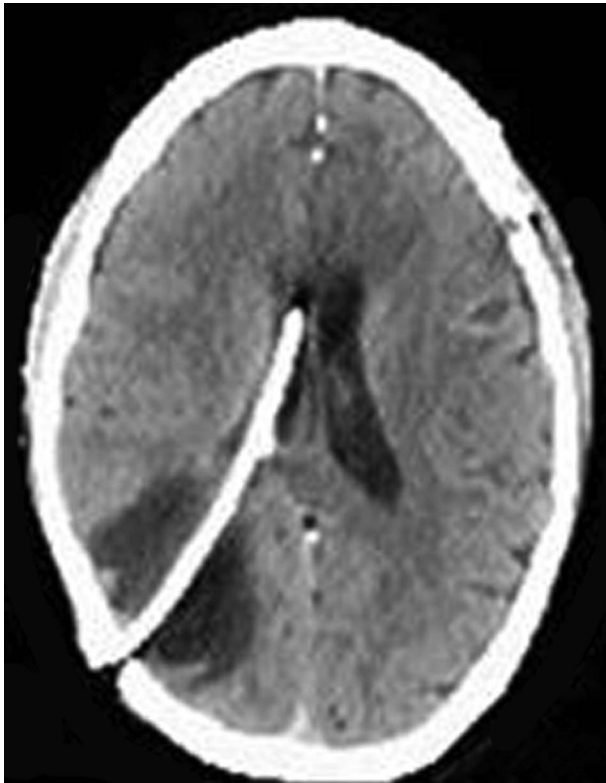
On postoperative day 3, the patient was discharged reporting improvement in the visual deficit. Testing 1 week later showed full visual fields. On CT, the cystic area was reduced in size to 27 × 16 mm and resolved 1 month later (Fig. 5).

**DISCUSSION**

CSF edema and cyst formation after shunt operations has been reported periodically (Table 1). Using the PubMed database, a literature search was conducted using a combination of the key words hydrocephalus, homonymous hemianopia, shunt malfunction, visual deficits, shunt failure, CSF edema, porencephalic cyst, pericatheter cyst, and intraparenchymal cyst. This yielded 13 articles that included cases dealing with cysts or CSF edema after shunt complications from 23 patients. Three articles in Japanese and 1 in French were excluded. All patients had improvement in CSF edema or cysts and their symptoms after shunt revision with the exception of the third case reported by Sugimoto et al (9). That patient required placement of a cyst peritoneal shunt in addition to ventriculoperitoneal shunt revision. The youngest patient included in this search was 32 days (6), and the oldest patient was 65 years (4). The interval between the time that the shunt was

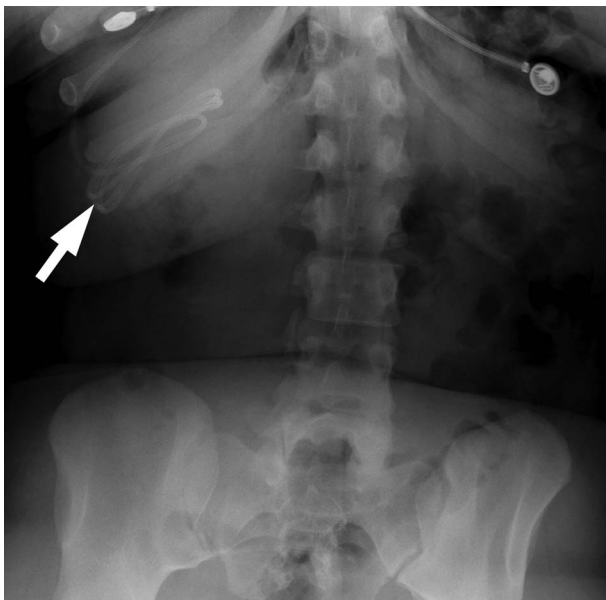


**FIG. 2.** Automated visual fields reveal a left homonymous hemianopia.

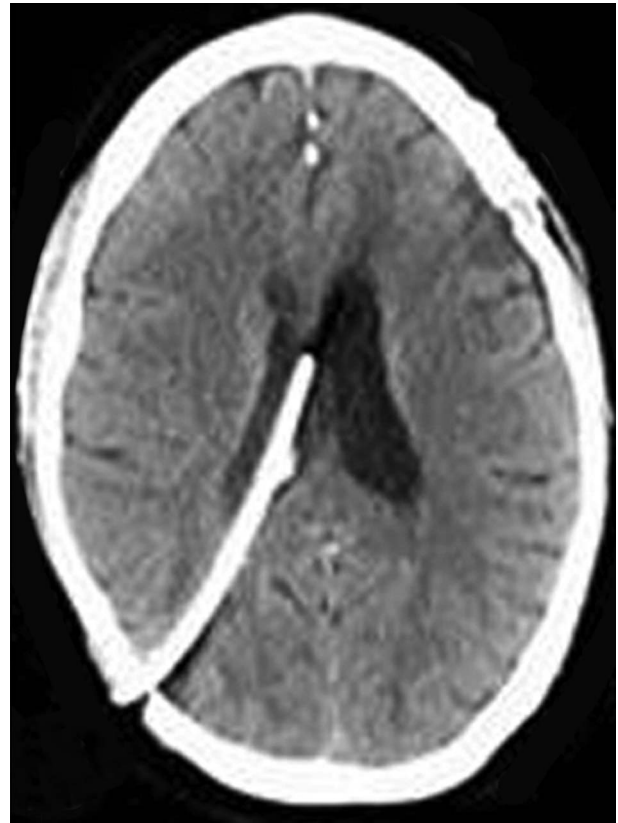


**FIG. 3.** Computed tomography 12 days postoperatively reveals a pericatheter cyst in the right in the right occipital lobe.

placed and the time the patient began experiencing complications ranged from 10 days (10, 11) to 12 years (7). Most patients required shunt revision although shunt removal and observation were also reported.



**FIG. 4.** Abdominal radiograph shows the shunt catheter (arrow) coiled in the right upper quadrant.



**FIG. 5.** Computed tomography demonstrates resolution of the paracatheter cyst 1 month later.

Most patients with VP shunt failure with CSF edema or cyst formation present with headache, vomiting, seizures, or drowsiness (3,7–11,13,14). Less typical presentations include isolated hemiparesis (4), speech and writing disturbances (5), or visual abnormalities. Chiba et al (11) reported a 58-year-old man who developed a low-density area on CT in the right parietal white matter and a left homonymous hemianopia. At surgery, an “excessive amount” of CSF was found under the dura, and with drainage and shunt revision, the visual field defect resolved. Kojima et al (15) documented a similar course in a patient with a left homonymous hemianopia that resolved with revision of a VP shunt. The authors proposed peritubular CSF edema in the right occipital area as the cause of the visual field defect.

We believe that, in our patient, distal shunt failure due to periperitoneal migration of the catheter resulted in elevated intracranial presence. Fluid tracked along the path of least resistance around the shunt catheter in the occipital lobe. Ventriculomegaly did not occur because the ventricles were noncompliant after SAH and were unable to expand to accommodate the increased CSF volume. The homonymous hemianopia was consistent with the location of the fluid accumulation in the right occipital lobe.

**TABLE 1.** Reports of CSF edema and pericatheter cysts after shunt malfunction

Author	No. of Cases	Age	Interval Between Shunt Placement and Complications	Primary Diagnosis	Presenting Symptoms	Site of Malfunction	Management
Iqbal et al, (3)	2	10 y	2 y	Lumbosacral meningocele	Headaches, vomiting, increasing weakness, and spasms in the right arm	Distal	Shunt revision
Shekawat et al, 2012 (4)	1	10 y	1 mo	Posttraumatic hydrocephalus	Headaches with nausea	Distal	Shunt revision
		65 y		Cerebellopontine angle mass with obstructive hydrocephalus	Right hemiparesis	Unknown	Shunt removal
Vajramani and Fugleholm, 2005 (5)	1	51 y	2 y	Hydrocephalus secondary to meningioma	Speech and writing disturbance	NA	Shunt revision
Rim et al, 2011 (6)	1	32 d	2 mo	Hydrocephalus after germinal matrix-intraventricular hemorrhage	Head enlargement and tense fontanel	Proximal	Shunt revision
Owen and Pittman, 2003 (7)	1	13 y	12 y	Tuberculous meningitis	Headache, vomiting, and lethargy	Proximal	Shunt revision
Balasubramaniam et al, 2013 (8)	1	1.5 y	1 y	Meningomyelocele	Seizures	Proximal	Shunt removal
Sugimoto et al, 1991 (9)	3	5 mo	2 mo	Hydrocephalus, meningocele, Chiara malformation	Vomiting	Unknown	Shunt revision and CP shunt added
		2 y	2 y	Congenital hydrocephalus	Vomiting/disturbed consciousness	Distal	Shunt revision
		5 mo	2 mo	Postmeningitis hydrocephalus, encephalocele		Unknown	VP shunt replaced
Prasad et al, 1991 (10)	2	45 y	10 d	Hydrocephalus	Less alert	Distal	Shunt revision
		60 y	2 wk	CPA mass with hydrocephalus	Drowsiness, urinary incontinence	Proximal	Shunt removal
Chiba et al, 1982 (11)	3	58 y	2 mo	Hydrocephalus	Headache, left homonymous hemianopia, hypesthesia, weakness	Distal	Shunt revision
		10 d	10 d	Bacterial meningitis	Signs of increased ICP	Distal	Shunt revision
		2 y	20 mo	Congenital hydrocephalus	Signs of increased ICP	Distal	Shunt revision
Sinha et al, 2008 (12)	2	4 y	4 y	Meningomyelocele	Asymptomatic, incidental cyst finding	NA	Image-guided aspiration
		5 mo	4 wk	Intraventricular cyst	Asymptomatic, incidental cyst finding	NA	Observation
Sakamoto et al, 1994 (13)	4	7 y	3 mo; 12 mo	Myelomeningocele	Subcutaneous fluid collection	Distal	Shunt revision

(Continued)

Author	No. of Cases	Age	Interval Between Shunt Placement and Complications	Primary Diagnosis	Presenting Symptoms	Site of Malfunction	Management
		7 y	9 mo; 16 mo	Achondroplasia	Vomiting, subcutaneous fluid collection	Distal	Shunt revision
		19 y	1 mo	Neurofibromatosis 1	Headache, unconscious spell	Distal	Shunt revision
		6 y	1 y	Occipital encephalocele	Drowsiness, vomiting	Distal	Shunt revision
Villarejo et al, 2004 (14)	1	7 y	7 y	Obstructive hydrocephalus	Headache, left hemiparesis	Proximal	Shunt revision
Kojima et al, 1984 (15)	1	55 y	20 d	Hydrocephalus	Congruous left homonymous hemianopia	Distal	Shunt revision

CSF, cerebrospinal fluid.

REFERENCES

- Auer LM, Mokry M.** Disturbed cerebrospinal fluid circulation after subarachnoid hemorrhage and acute aneurysm surgery. *Neurosurgery.* 1990;26:804–808.
- Cozzens JW, Chandler JP.** Increased risk of distal ventriculoperitoneal shunt obstruction associated with slit valves or distal slits in the peritoneal catheter. *J Neurosurg.* 1997;87:682–686.
- Iqbal J, Hassounah M, Sheikh B.** Intraparenchymal pericatheter cyst. A rare complication of ventriculoperitoneal shunt for hydrocephalus. *Br J Neurosurg.* 2000;14:255–258.
- Shekawat JS, Sundar IV, Poonia N, Sinha VD.** Intraparenchymal pericatheter cyst following ventriculoperitoneal shunt. *Neuro India.* 2012;60:341–342.
- Vajramani GV, Fugleholm K.** Reversible CSF cyst related to a functioning ventriculo-peritoneal shunt. *Acta Neurochir (Wien).* 2005;147:1199–1202.
- Rim H, Hwang SK, Kwon S, Kim H.** Intraparenchymal pericatheter cyst as a complication of a ventriculo-peritoneal shunt in a premature infant. *J Korean Neurosurg.* 2011;50:143–146.
- Owen R, Pittman T.** Shunt malfunction presenting with cerebral edema. *Pediatr Neurosurg.* 2003;38:110–112.
- Balashubramaniam S, Tyagi DK, Sawant HV.** Intraparenchymal pericatheter cyst following disconnection of ventriculoperitoneal shunt system. *J Postgrad Med.* 2013;59:232–234.
- Sugimoto K, Enomoto T, Nose T.** Reversible porencephaly, alteration of the cerebrospinal fluid flow after shunt malfunction. *Child’s Nerv Syst.* 1992;7:394–398.
- Prasad A, Madan VS, Buxi TB, Renjen PN, Vohra R.** The role of the perforated segment of the ventricular catheter in cerebrospinal fluid leakage into the brain. *Br J Neurosurg.* 1991;5:299–302.
- Chiba Y, Takagi H, Nakajima F, Fujii S, Kitahara T, Yagishita S, Itoh Y.** Cerebrospinal fluid edema: a rare complication of shunt operations for hydrocephalus. *J Neurosurg.* 1982;57:697–700.
- Sinha AK, Lall R, Benson R, O’Brien DF, Buxton N.** Intraparenchymal pericatheter cyst following ventriculoperitoneal shunt insertion: does it always merit shunt revision? *Zentralbl Neurochir.* 2008;69:152–154.
- Sakamoto H, Fujitani K, Kitano S, Murata K, Hakuba A.** Cerebrospinal fluid edema associated with shunt obstruction. *J Neurosurg.* 1994;81:179–183.
- Villarejo FJ, Pascual A, Carceller F, Bencosme JA, Perez Diaz C, Goyenechea F.** Cerebral fluid edema: an unusual complication of ventriculoperitoneal shunts. *Child’s Nerv Syst.* 2004;20:195–198.
- Kojima N, Kuwamura K, Tamaki N, Matsumoto S.** Reversible congruous homonymous hemianopia as a symptom of shunt malfunction. *Surg Neurol.* 1984;22:253–256.