

Diagnosis and Therapy in Ophthalmology

Binasal hemianopia due to bilateral internal carotid artery atherosclerosis

Steffen Hamann, Hayder Ghani Obaid and Paula Lopez Celiz

Departments of Ophthalmology (SH, PLC) and Radiology (HGO), Glostrup Hospital, University of Copenhagen, Glostrup, Denmark

Acta Ophthalmol. 2015; 93: 486–487

© 2014 Acta Ophthalmologica Scandinavica Foundation. Published by John Wiley & Sons Ltd

doi: 10.1111/aos.12565

A 70-year-old man with arterial hypertension and a pacemaker was referred for neuro-ophthalmological examination due to visual field defects. The patient was experiencing increased dif-

ficulty with vision at night and increased sensitivity to light and glare, for which he had consulted an ophthalmologist who noted the field defects.

Apart from the visual fields showing binasal hemianopia extending across the vertical midline (Fig. 1A), neuro-ophthalmological examination revealed a best corrected visual acuity of 0.9,

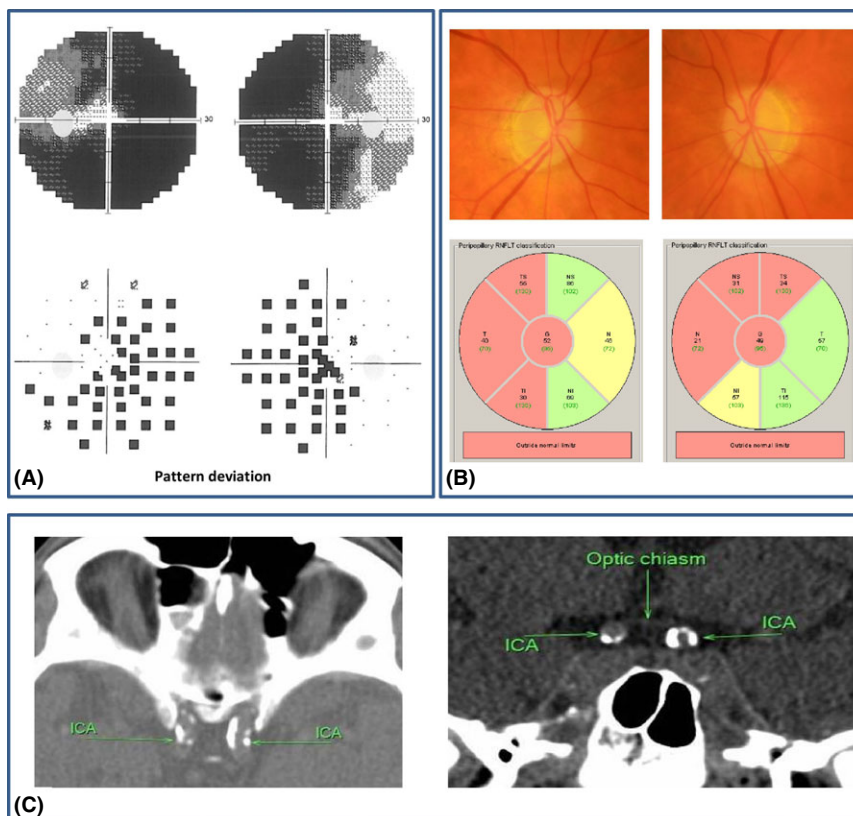


Fig. 1. (A) Automated visual fields (30°, Octopus 900, G Dynamic, Humphrey printout option). Binasal hemianopia extending across the vertical midline. (B) Fundus photographs and measures of the peripapillary retinal nerve fibre layer (RNFL) thickness using optical coherence tomography (OCT). Diffuse pallor of both optic discs was seen; the retinas appeared normal (upper panel). OCT revealed bilateral thinning of the peripapillary RNFL, mainly on the temporal side of the right optic disc and on the nasal and superior sides of the left optic disc (lower panel). Numbers indicate thickness in μm , red colour denotes thinning, yellow colour borderline thinning, and green colour normal thickness. (C) Non-enhanced computed tomography of the brain. Axial (left) and coronal (right) views showing bilateral internal carotid artery (ICA) atherosclerosis and atrophic optic chiasm. Both ICAs are slightly dolichoectatic.

right eye, and 1.0, left eye, and a bilateral severe dyschromatopsia of which the patient was well aware. Pupillary reactions were normal. The intraocular pressure was 21 mmHg bilaterally, and incipient cataracts were noted at slit lamp examination. Fundus examination revealed diffuse pallor of the optic discs bilaterally. No glaucomatous cupping was noted and the retinas appeared normal (Fig. 1B, upper panel). Spectral domain optical coherence tomography (OCT) scan revealed thinning of the temporal peripapillary retinal nerve fibre layer, right eye, and of the nasal and superior peripapillary retinal nerve fibre layer, left eye (Fig. 1B, lower panel). The macular OCTs were completely normal except for minor oedema in the papillomacular region, left eye (not shown).

Computed tomography (CT) scan of the brain showed thick, contiguous calcifications and slight dolichoectasia of both internal carotid arteries adjacent to the optic nerves immediately anterior to the optic chiasm (Fig. 1C). Magnetic resonance imaging was not performed because of a pacemaker. A carotid artery duplex scan showed 30% calcification of the cervical segment of the internal carotid artery bilaterally. Laboratory studies revealed hypercholesterolemia with a total cholesterol of 6.3 mmol/l (national recommendations: <4 mmol/l) and an LDL of 3.6 mmol/L (<1.8 mmol/l), and treatment with clopidogrel as well as simvastatin was subsequently initiated. The patient was followed for a year with symptoms and findings remaining completely stable.

Isolated binasal hemianopia is exceedingly uncommon. As opposed to its counterpart, bitemporal hemianopia, binasal hemianopia has probably more to do with the eyes, including optic nerve head, than the brain. In a study of 100 patients referred for neuro-ophthalmological evaluation,

eight had binasal visual field defects of which six were caused by bilateral optic nerve head involvement such as optic disc drusen or bilateral retinal disease such as retinitis pigmentosa. The remaining two cases were caused by congenital hydrocephalus, where the distended third ventricle putatively had pushed the intracranial optic nerves laterally against the supraclinoid portion of the internal carotid arteries (Salinas-Garcia & Smith 1978).

Binasal hemianopia can conceivably be caused by bilateral atherosclerosis or aneurysms of the internal carotid arteries simultaneously compressing the adjacent non-crossing fibres of both optic nerves. However, the documentation in literature of this causal relationship mostly relies on the examination of post-mortem material (Smith 1905) and the combination of tangent screen perimetry, ophthalmoscopy and X-rays (Knapp 1932). Surprisingly, except for one single case (Fabian 1980), we did not find any cases of binasal hemianopia caused by internal carotid atherosclerosis documented with modern imaging techniques.

Our patient displayed a binasal hemianopia not respecting the vertical midline, which is characteristic for this type of hemianopic field defect. The maculas were spared preserving good central visual acuity. A significant part of the lower temporal fields were affected, especially in the left eye. Corresponding to the field defects, a thinning of the peripapillary retinal nerve fibre layer was noted on OCT, most likely caused by retrograde axonal degeneration as also seen in chiasmal injury (Ostri et al. 2012). There was no sign of glaucoma; the intraocular pressures were consistently normal, the optic discs were not excavated, and the visual field defects were stable despite no antiglaucoma therapy. A CT scan was normal except

for dense bilateral calcification and slight dolichoectasia of the intracranial internal carotid arteries adjacent to and most likely compressing the non-crossing axonal fibres of the prechiasmatic optic nerves. We recommend a CT scan of the chiasmal region for patients presenting with binasal visual field defects and optic atrophy, where optic disc appearance and intraocular pressure readings speak against glaucoma.

References

- Fabian E (1980): [Bilateral occlusion of the internal carotid artery with binasal visual field defect and partial optic atrophy (author's transl)]. *Arch Psychiatr Nervenkr* **228**: 341–350.
- Knapp A (1932): On the Association of Sclerosis of the Cerebral Basal Vessels with Optic Atrophy and Cupping: report of 10 Cases. *Trans Am Ophthalmol Soc* **30**: 343–358.
- Ostri C, Damgaard B & Hamann S (2012): Optical coherence tomography documenting retinal nerve fiber loss in traumatic optic chiasmal syndrome. *Acta Ophthalmol* **90**: 792–794.
- Salinas-Garcia RF & Smith JL (1978): Binasal hemianopia. *Surg Neurol* **10**: 187–194.
- Smith GE (1905): A note on nervous lesions produced mechanically by atheromatous arteries. *Rev Neurol Psychiatr* **3**: 182–184.

Received on July 1st, 2014.

Accepted on August 26th, 2014.

Correspondence:

Steffen Hamann, MD, PhD
Department of Ophthalmology
University of Copenhagen
Nordre Ringvej 57
2600 Glostrup
Denmark
Tel: +45 3863 4653
Fax: +45 3863 3739
Email: steffen.hamann@regionh.dk

The authors report no conflict of interest. No funding was received for this work.