

Bilateral Asymmetrical Asterixis as Limb-shaking Transient Ischemic Attack in Bilateral Carotid Stenosis

Shaida Khan, DO,* Eric Chang, BS,† Georgia Saniuk, BS,† and Ty Shang, MD, PhD*

Asterixis as limb-shaking transient ischemic attack (TIA) is rare and poorly understood. Bilateral asymmetrical asterixis as limb-shaking TIA has not been reported in carotid stenosis. A 69-year-old gentleman presented with a TIA episode (dysarthria, right-arm weakness, and numbness). Bilateral asterixis was observed and was more severe on the right side. No prior infarcts were noted in the thalamus. Liver function was normal. A computerized tomography angiogram revealed 85% stenosis of the right internal carotid artery (ICA) and 65% stenosis of the left ICA. Three days after left ICA endarterectomy, the patient had complete disappearance of bilateral asterixis, with the right side showing initial improvement. The bilateral asterixis observed is proposed to be secondary to hemodynamic impairment and hypoperfusion of certain brain territory with resolution on revascularization. **Key Words:** Carotid stenosis—limb shaking TIA—asterixis—carotid endarterectomy.

© 2015 by National Stroke Association

Case Report

A 69-year-old gentleman presented with symptoms of dysarthria and right-arm weakness and numbness, which resolved within 24 hours. On physical examination, bilateral asymmetrical asterixis were evident, with right side

more severe than the left (Video 1). Asterixis did not appear immediately when arms were outstretched but gradually appeared and progressively worsened. No abnormal movements were noticed at rest. There were no electrolyte or liver function abnormalities. No acute or prior infarcts in thalamus or frontal lobes were noted on magnetic resonance imaging. A computerized tomography angiogram revealed 85% stenosis of the right internal carotid artery (ICA) and 65% stenosis of the left ICA (Fig 1). Endarterectomy was performed on the left ICA. Right asterixis improved significantly on postoperation day 1 and completely resolved on day 2. Left asterixis started to improve on day 2 and resolved by day 3 (Video 2).

From the *Department of Neurology & Neurotherapeutics, University of Texas Southwestern Medical Center, Dallas, Texas; and †School of Medicine, University of Texas Southwestern Medical Center, Dallas, Texas.

Received July 2, 2014; revision received August 14, 2014; accepted August 18, 2014.

T.S. was responsible for study concept and design, acquisition of data, analysis and interpretation, and article writing; S.K. for data interpretation and the article writing; E.C. for article writing; and G.S. for acquisition of data.

The authors have no conflicts of interest to declare.

Address correspondence to Ty Shang, MD, PhD, Department of Neurology & Neurotherapeutics, University of Texas Southwestern, 5323 Harry Hines Boulevard, Dallas, TX 75390-8897. E-mail: ty.shang@utsouthwestern.edu.

1052-3057/\$ - see front matter

© 2015 by National Stroke Association

<http://dx.doi.org/10.1016/j.jstrokecerebrovasdis.2014.08.016>

Discussion

Abnormal limb movement as a symptom of transient ischemic attack (TIA) in the presence of ICA disease was described by Miller Fisher in 1962.¹ “Limb-shaking” TIA was named after reports of a series of similar cases in 1985² and was thought to be uncommon, presenting in 2% of ICA stenosis patients.³ It is typically described

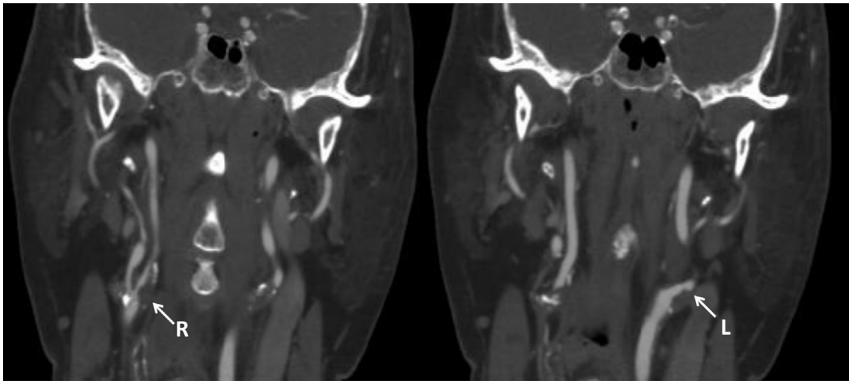


Figure 1. Computerized tomography angiogram showed 85% stenosis of right internal carotid artery (ICA) and 65% stenosis of left ICA.

as brief, coarse, irregular, involuntary movements, or tremble that lasts less than 5 minutes. The pathophysiology of limb-shaking symptoms remains unclear, but it has been recently proposed as an inability to maintain postural tone, a similar mechanism shared with asterixis, but due to hypoperfusion of certain brain territory.^{4,5} Asterixis is usually associated with metabolic disease, such as hepatic encephalopathy if present bilaterally or focal cerebral lesion if present unilaterally. Our patient did not have any metabolic abnormalities or lesions in the thalamus or frontal lobes, and his asterixis resolved completely after revascularization. These observations support that ICA stenosis was the cause of his asterixis, a mild form of limb-shaking TIA.⁴

Limb shaking is often precipitated by a change in body position, such as the prolonged antigravity position of the arms of our patient. His asymmetrical asterixis was more significant on the right side, and it appeared early with a larger amplitude and higher frequency. Compared with patients without limb shaking in carotid stenosis, patients with limb shaking were reported to have a worse hemodynamic state of blood flow.^{6,7} Therefore, it is reasonable to postulate that greater asterixis was associated with worse hemodynamic instability of the contralateral hemisphere, which was more impaired with a higher risk for stroke. These observations were consistent with his right-sided presenting TIA symptoms. Interestingly, the resolution of asterixis followed the same

order after revascularization, with the right limb initially showing improvement. This case report expands the spectrum of limb-shaking TIA symptoms.

Supplementary Data

Supplementary data related to this article can be found at <http://dx.doi.org/10.1016/j.jstrokecerebrovasdis.2014.08.016>.

References

1. Fisher CM. Concerning recurrent transient cerebral ischemic attacks. *Can Med Assoc J* 1962;86:1091-1099.
2. Baquis GD, Pessin MS, Scott RM. Limb shaking—a carotid TIA. *Stroke* 1985;16:444-448.
3. Kim SH, Han SW, Heo JH. Predictive implications of recurrent transient ischemic attacks in large-artery atherosclerosis. *Cerebrovasc Dis* 2006;22:240-244.
4. Yoon Y, Kim J. Limb-shaking TIA: an asterixis. *Neurology* 2013;81:931-932.
5. Maddula M, Keegan B. Limb shaking as a manifestation of low-flow transient ischemic attacks. *Int J Gerontol* 2010; 4:47-50.
6. Persoon S, Kappelle LJ, Klijn CJ. Limb-shaking transient ischaemic attacks in patients with internal carotid artery occlusion: a case-control study. *Brain* 2010;133:915-922.
7. Paciaroni M, Caso V, Venti M, et al. Outcome in patients with stroke associated with internal carotid artery occlusion. *Cerebrovasc Dis* 2005;20:108-113.