

Reappearance of Free-floating Carotid Thrombus after Discontinuation of Anticoagulant Therapy

Masaki Naganuma, MD,* Yuichiro Inatomi, MD,* Osamu Kobayashi, MD,†
Toru Nishi, MD,† Toshiro Yonehara, MD,* and Yukio Ando, MD, PhD‡

A 73-year-old woman who suddenly developed left hemiparesis was admitted to our hospital. Ultrasonography on admission showed a free-floating thrombus (FFT) attached to an ulcerative plaque in the right common carotid artery. The FFT almost disappeared during treatment with intravenous anticoagulation therapy for acute stroke, but it reappeared when the therapy was discontinued. She underwent endarterectomy on day 13, after which she was free from stroke recurrence. **Key Words:** Carotid endarterectomy—carotid ultrasonography—free-floating thrombus—mobile plaque.

© 2015 by National Stroke Association

A free-floating thrombus (FFT) of the carotid arteries is a rare condition that is considered to have a high likelihood of embolic cerebrovascular disease. An FFT was observed in the carotid artery in around .4% of patients with acute ischemic stroke.^{1,2} Because the natural history of FFT remains unclear, the treatment strategy of FFT in the acute phase of ischemic stroke is controversial.²⁻⁴

A case in which reappearance of an FFT was observed on serial ultrasonography during antithrombotic therapy in acute ischemic stroke is reported.

From the *Department of Neurology, Stroke Center, Saiseikai Kumamoto Hospital, Kumamoto; †Department of Neurosurgery, Stroke Center, Saiseikai Kumamoto Hospital, Kumamoto; and ‡Faculty of Life Sciences, Department of Neurology, Kumamoto University, Kumamoto, Japan.

Received August 1, 2014; revision received August 19, 2014; accepted August 27, 2014.

The authors report no conflicts of interest.

Address correspondence to Masaki Naganuma, MD, Department of Neurology, Stroke Center, Saiseikai Kumamoto Hospital, 5-3-1 Chikami, Minami-ku, Kumamoto 861-4193, Japan. E-mail: naganuma@f6.dion.ne.jp.

1052-3057/\$ - see front matter

© 2015 by National Stroke Association

<http://dx.doi.org/10.1016/j.jstrokecerebrovasdis.2014.08.031>

Case Report

A 73-year-old woman was admitted to our hospital due to sudden left hemiparesis. Diffusion-weighted magnetic resonance imaging on admission (day 0) showed scattered multiple foci mainly in the cortex and subcortex of the right frontal and parietal lobes. Carotid ultrasonography showed an FFT attached to the ulcerated plaque that moved with the cardiac cycles in the right common carotid artery (Fig 1, A, Video 1). She was immediately treated with intravenous Argatroban and unfractionated heparin, as well as oral aspirin, clopidogrel, and atorvastatin. On day 5, carotid ultrasonography showed that the FFT on the ulcerated plaque had almost disappeared, with only a small residual root (Fig 1, B). Therefore, intravenous Argatroban was discontinued on day 6, unfractionated heparin was discontinued on day 8, and oral aspirin and clopidogrel were continued. Carotid ultrasonography on day 12 showed reappearance of the FFT on the plaque at the original site (Fig 1, C), although she had not experienced clinical recurrence. Moreover, magnetic resonance imaging on day 12 showed no recent infarcts. Intravenous unfractionated heparin was restarted immediately, and she underwent right carotid endarterectomy on day 13.

Intraoperative findings during carotid endarterectomy showed a mobile structure attached to the atheromatous

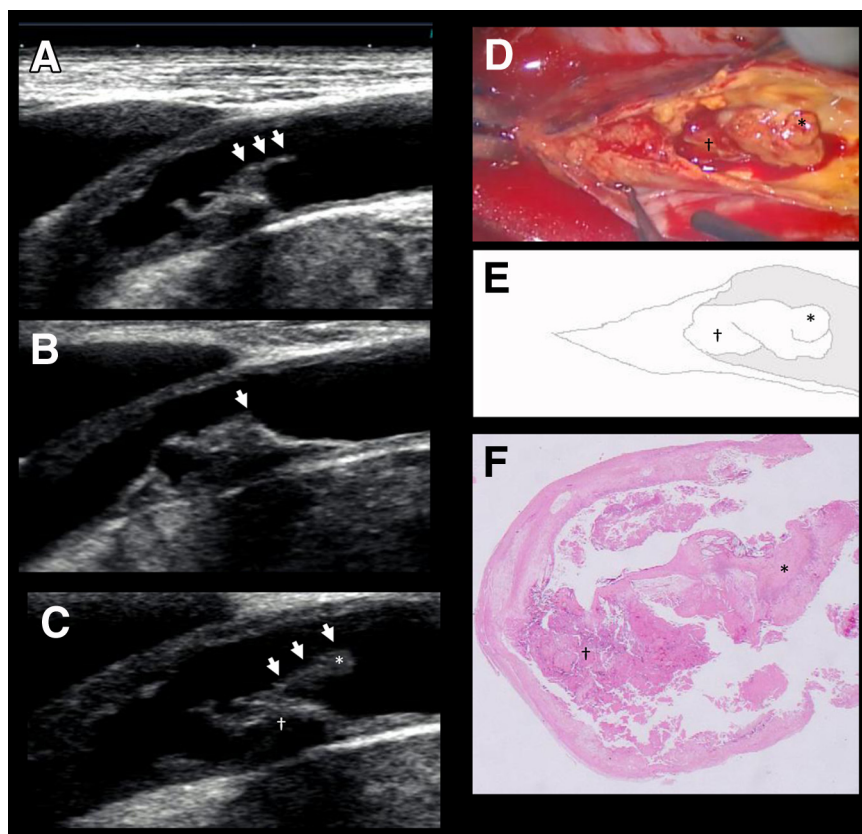


Figure 1. (A-C) Serial studies of the longitudinal view of the right common carotid ultrasonography. (A) Ulcerated plaque with free-floating thrombus (FFT) attached to the plaque (white arrows) that moves with the cardiac cycle (day 0). (B) The FFT has almost disappeared, showing a small residual root (white arrow; day 5). (C) Reappearance of the FFT (white arrows; day 12). (D) Intraoperative image confirms the presence of an FFT on the plaque in the right common carotid artery. (E) Schema of the FFT and plaque based on the intraoperative image. (F) Histology of the FFT and plaque shows mainly fibrin with scattered erythrocytes. The plaque consists mainly of fibrin and foam cells, with some cholesterol clefts. Hemorrhagic change is also observed in some parts of the plaque. (C, D, E, F) * indicates the free-floating thrombus. † indicates the plaque.

plaque (Fig 1, D,E). The pathologic findings of the removed FFT consisted mainly of fibrin with scattered erythrocytes (Fig 1, F).

Postoperatively, the patient was given aspirin and was free of relapse of stroke, with no plaque enlargement for 1 year after onset.

Discussion

Because of the rarity of this condition and the lack of clinical studies with a high level of evidence, there is no consensus concerning the treatment of FFT. Patients with mobile carotid plaque including FFT tend to suffer from recurrent strokes.² Therefore, patients with an FFT often undergo immediate surgical treatment.⁵ On the other hand, there had been a group in which medical treatment was effective.³ In cases treated with medical therapy, the selection of antithrombotic agents is also under discussion.^{3,6,7} Both antithrombotic therapies, antiplatelet and anticoagulant agents, have been reported to be effective and ineffective.^{3,6} The difference in response to medical treatments might depend on the components of the FFT.⁷

With respect to the mechanism of FFT formation, atherosclerosis and plaque rupture are generally considered to be the most common etiology.^{3,8} This type of FFT mainly consists of erythrocytes, because the mechanism involves exposure of the necrotic core to the

blood flow.^{9,10} However, in the present case, the FFT consisted mainly of fibrin.¹⁰ The mechanism of fibrin-rich FFT formation is not well known. In the present case, the small residual root of the FFT may have activated the blood coagulation cascade after the termination of anticoagulation therapy. Therefore, continuation of anticoagulant therapy might be considered in case with a FFT almost disappeared with a residual root after anticoagulant therapy.

Supplementary Data

Supplementary data related to this article can be found at <http://dx.doi.org/10.1016/j.jstrokecerebrovasdis.2014.08.031>.

References

1. Biller J, Adams HP Jr, Boarini D, et al. Intraluminal clot of the carotid artery. A clinical-angiographic correlation of nine patients and literature review. *Surg Neurol* 1986; 25:467-477.
2. Ogata T, Yasaka M, Wakugawa Y, et al. Morphological classification of mobile plaques and their association with early recurrence of stroke. *Cerebrovasc Dis* 2010; 30:606-611.
3. Bhatti AF, Leon LR Jr, Labropoulos N, et al. Free-floating thrombus of the carotid artery: literature review and case reports. *J Vasc Surg* 2007;45:199-205.

4. Chakhtoura EY, Goldstein JE, Hobson RW. Management of mobile floating carotid plaque using carotid artery stenting. *J Endovasc Ther* 2003;10:653-656.
5. Lane TR, Shalhoub J, Perera R, et al. Diagnosis and surgical management of free-floating thrombus within the carotid artery. *Vasc Endovascular Surg* 2010;44:586-593.
6. Urbano LA, Perren F, Rossetti AO, et al. Images in cardiovascular medicine. Thrombus in the internal carotid artery complicating an "unstable" atheromatous plaque. *Circulation* 2003;107:e19-e20.
7. Hill SL, Brozyna W. Extensive mobile thrombus of the internal carotid artery: a case report, treatment options, and a review of the literature. *Am Surg* 2005;71:853-855.
8. Funaki T, Iihara K, Miyamoto S, et al. Histologic characterization of mobile and nonmobile carotid plaques detected with ultrasound imaging. *J Vasc Surg* 2011; 53:977-983.
9. Golledge J, Greenhalgh RM, Davies AH. The symptomatic carotid plaque. *Stroke* 2000;31:774-781.
10. Pisimisis GT, Kantor B, Kalra M, et al. Thrombus of the internal carotid artery: the contribution of computed tomographic angiography to clinical management. *Vasc Endovascular Surg* 2010;44:302-304.