

## **Selected Topics: Neurological Emergencies**



### **POSTTRAUMATIC CAROTID CAVERNOUS FISTULA THAT PRESENTED AS SEIZURE AND FOCAL NEUROLOGICAL DEFICITS WITH SYMPTOM RESOLUTION AFTER THERAPEUTIC COIL EMBOLIZATION**

Ekaterina Klevtsova, MD, MS, Caroline Nguyen-Min, MD, Tania Lalani, MD, Stephen James Carlan, MD, and Mario Madruga, MD

Division of Medical Education, Department of Internal Medicine, Orlando Regional Healthcare, Orlando, Florida

Reprint Address: Stephen James Carlan, MD, Division of Medical Education, Department of Internal Medicine, Orlando Regional Healthcare, 105 West Miller St., Orlando, FL 32806

**Abstract—Background:** A posttraumatic carotid cavernous fistula can remain unrecognized and ultimately present with symptoms characteristic for a middle cerebral artery stroke. Progressive neurologic deterioration can occur until the condition is diagnosed and treated. If unrecognized and untreated, permanent damage may result. **Case Report:** A 46-year-old white man with the history of a motor vehicle crash 6 months prior presented with complaints of acute onset of expressive aphasia and seizure-like activity for 3 days. On presentation, the patient was noted to have moderate proptosis and chemosis of the left eye. Magnetic resonance imaging of the brain showed an arteriovenous fistula arising from the anterolateral precavernous left internal carotid artery. This was directly communicating with the adjacent cortical veins along the medial aspect of the left temporal lobe, resulting in venous congestion in the left frontal opercular region, the left insula, and subinsular tracks. The patient underwent an intracranial coil embolization of a left carotid cavernous fistula. No complications were encountered, and the patient had near-complete resolution of neurologic deficits and left eye proptosis. **Why Should an Emergency Physician Be Aware of This?:** Although posttraumatic carotid cavernous fistula is a rare condition, it is important to be aware of this entity because immediate diagnosis and treatment may improve outcome. © 2015 Elsevier Inc.

**Keywords—**posttraumatic head injury; carotid cavernous fistula; coil embolization

#### **INTRODUCTION**

Carotid cavernous fistula (CCF) occurs between the carotid artery and the cavernous sinus. It is usually due to the rupture of the internal carotid artery within the cavernous sinus, and occurs more frequently after a fracture of the cranial fundus by trauma. According to Barrow et al., CCFs are categorized into four main classification types: type A – direct, high-flow shunts between the internal carotid artery (ICA) and the cavernous sinus; type B – indirect, low-flow communication between meningeal branches of the ICA and cavernous sinus; type C – indirect, low-flow dural shunts between meningeal branches of the external carotid artery (ECA) and the cavernous sinus; and type D – indirect, low flow shunt between meningeal branches of both the ICA and ECA and the cavernous sinus (1–3).

CCF is a rare but serious condition; patients usually experience progressive ocular complications, and may even develop intracerebral hemorrhage (3). Therefore, early detection, immediate attention, and intervention are imperative to decrease the morbidity and mortality in these patients.

#### **CASE REPORT**

A 46-year-old white man with no significant past medical history, other than a motor vehicle collision (MVC)

RECEIVED: 1 July 2013; FINAL SUBMISSION RECEIVED: 2 September 2014;

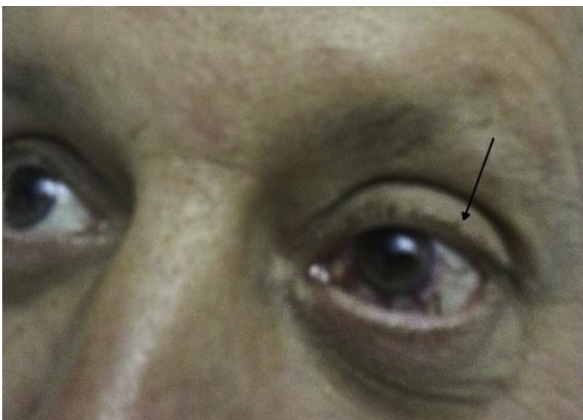
ACCEPTED: 30 September 2014

6 months prior, presented to the Emergency Department complaining of acute neurological disturbances. At the time of the collision, the patient sustained extensive bilateral facial fractures including zygomaticomaxillary fractures, LeFort fractures with the main fracture line extending horizontally through the maxilla to the pterygoid plates, with fracture of both pterygoid plates. Fractures involved the maxillary walls on both sides, both medial and lateral orbital floors, diastatic fractures of both lateral walls of the orbit, and fractures of both zygomas. Also, he had a fractured right mandible. In addition, he sustained facial, rib, and femur fractures with a pneumothorax.

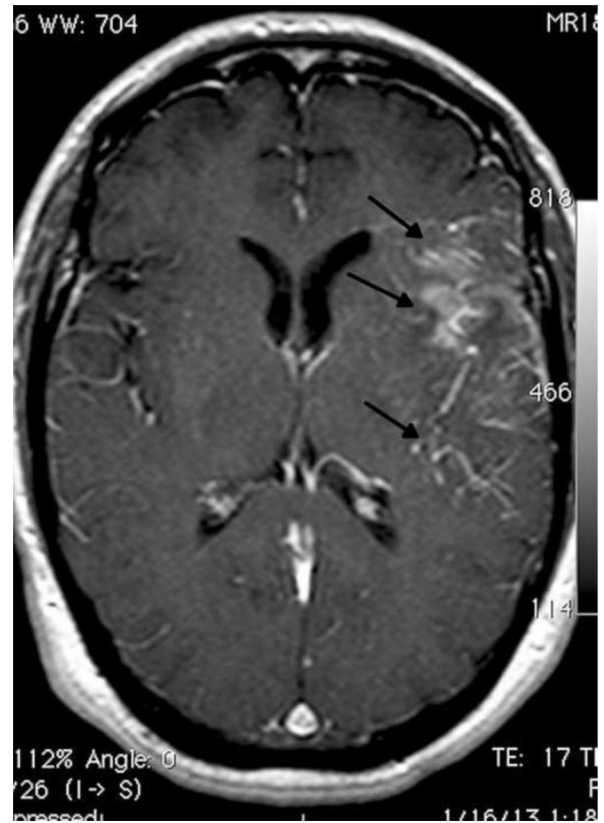At the time of presentation he was complaining of acute onset of expressive aphasia and possible seizure-like activity for the previous 3 days, as well as persistent headache since the accident. He described a sensation of “hearing his brain running.” According to the patient’s sister, he was noted to have a facial droop and tongue deviation to the left, which was new for him.

The physical examination was significant for expressive aphasia, facial droop, left eye proptosis with chemosis (Figure 1), and a tongue deviated to the left. His pupils were round and equally reactive to light, and no eyeball pulsation was noted. The anterior eye chambers were normal in both eyes, and his vision was 20/40 in both eyes. Left deep scleral vessel injection was present.

A computed tomography scan of the head was unremarkable except for a small area of encephalomalacia in the left frontal lobe related to the interval resolution of intra-axial hemorrhage from the initial MVC. The patient was admitted to the hospital and a brain magnetic resonance imaging study (Figure 2) and magnetic resonance angiogram (Figure 3) showed an arteriovenous fistula arising from the anterolateral precavernous left ICA directly communicating with adjacent cortical veins along the medial aspect of the left temporal lobe. This fistula was producing venous congestion in the left frontal



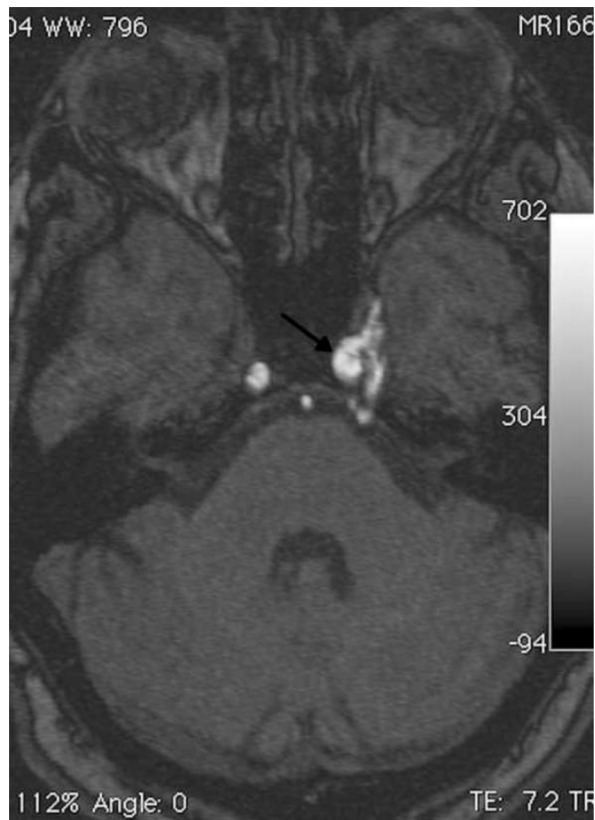**Figure 1.** Left eye proptosis, chemosis (arrow), and significant scleral vessels injection.



**Figure 2.** Magnetic resonance imaging (MRI) study of the brain shows abnormal enhancement as well as fluid-attenuated inversion recovery (FLAIR) hyperintensity in the inferior aspect of the left frontal lobe extending to the anterior aspect of the left temporal lobe in the left periventricular white matter (arrows). This involves the insular and subinsular regions. Multiple linear areas of enhancement are seen in an area of FLAIR hyperintensity, which appear to be vessels and veins with more matted enhancement involving the left insula.

opercular region, the left insula, and subinsular tracks. The left ICA appeared to be significantly larger than the right ICA, which could be attributed to turbulent flow at the level of the carotid bulb. An electroencephalogram (EEG) demonstrated electrographic focal seizures arising from the left frontal region, likely reflective of an underlying structural lesion.

The patient was then started on levetiracetam 1000 mg intravenous on hospital day 2, and his expressive aphasia significantly improved within approximately 24 h. The patient underwent a transvenous cerebral angiography, as requested by Neurosurgery, which confirmed a direct carotid cavernous fistula, which was seen between the left internal carotid artery cavernous section and the left cavernous sinus (Figure 4). The major drainage was through an enlarged inferior petrosal sinus, as well as some retrograde filling of a significantly enlarged left cortical vein, which was causing engorgement of the cortical surface veins.

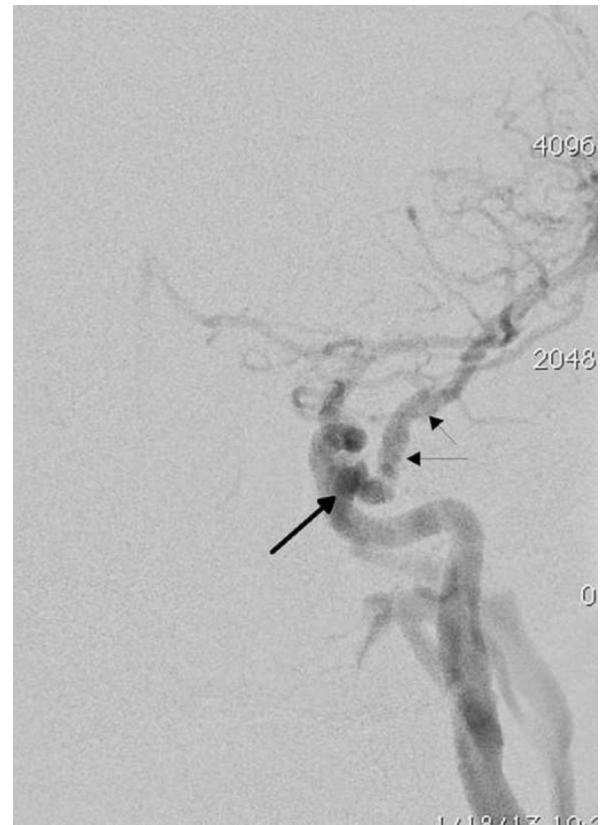

**Figure 3.** Magnetic resonance angiogram of the brain shows an arteriovenous fistula (arrow) arising from the anterolateral aspect of the precavernous left internal carotid artery, directly communicating with adjacent cortical veins.

The patient then underwent an intracranial Codman coil embolization of the left carotid cavernous fistula. Postembolization left internal carotid artery cerebral angiogram was performed, showing a complete absence of the previously seen retrograde filling of the enlarged left cortical vein and absence of retrograde filling of pial venous structures on the cortical surface (Figure 5). No complications occurred during or after the coiling procedure. The patient was discharged after a 10-day hospital stay in stable condition, and he was instructed to follow up with Neurosurgery.

### DISCUSSION

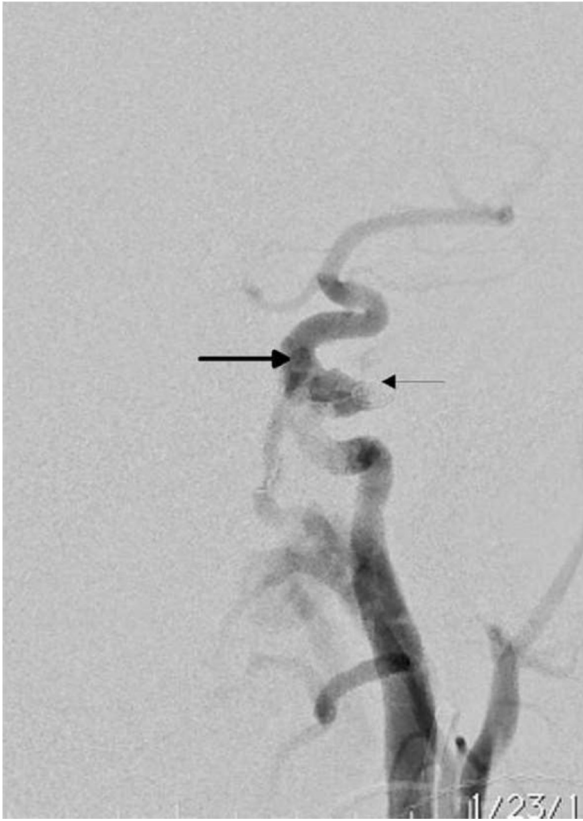The estimated incidence of traumatic brain injury (TBI) in the United States is 1.5 million per year. Approximately 0.2–0.3% of these TBIs are complicated by CCF (2,3). Barrow et al. classified CCF into direct/Type A and Indirect (Types B, C, D) (1). Direct CCF, which most commonly occurs in TBI patients, is a high-flow fistula that develops between the internal carotid artery and cavernous sinus (4,5). Symptomatic direct CCF may be caused by any severity and a wide variety of traumatic



**Figure 4.** Brain arteriogram prior to coil. Direct carotid cavernous fistula between the left internal carotid artery cavernous section and the left cavernous sinus. The major drainage is through an enlarged inferior petrosal sinus as well as retrograde filling of a significantly enlarged left cortical vein. Large arrow is on the fistula and the small arrows are on a huge cortical vein.

brain injury mechanisms (penetrating, or nonpenetrating injuries associated with basal or facial skull fractures related to MVC, falls, fights, orbitocranial perforating injuries, etc.). Spontaneous direct CCF is rare, and usually it occurs in patients with underlying pathology that affects vasculature (connective tissue disease such as Ehlers-Danlos syndrome, systemic vasculopathy due to chronic hypertension, preexisting aneurysm of ICA) (6). Increased venous pressure leads to the classic symptom triad of CCF: exophthalmos, conjunctival injection, and an audible orbital bruit. However, symptoms and signs may range from isolated ocular manifestations to life-threatening brain edema and intracranial hemorrhage (4,5,7–9).

The etiology and pathogenesis of indirect CCF are controversial. In contrast to direct CCF, they usually become symptomatic spontaneously. Factors that reportedly may predispose to development of symptomatic indirect CCF include: pregnancy, hypertension, atherosclerotic vascular disease, and connective tissue disorders. Head trauma may also lead to indirect CCF formation.



**Figure 5.** Image after the coiling procedure. A left internal carotid artery cerebral angiogram with traditional angles and magnification showed a complete absence of the previously seen retrograde filling of enlarged left cortical vein and absence of the previously seen retrograde filling of pial venous structures on the cortical surface. The internal carotid artery is at the large arrow and coil at the small arrow.

This case is notable because the patient presented to the ED months after the initial head injury with acute onset of symptoms that were consistent with a lesion in middle cerebral artery distribution. Because the patient's focal neurologic deficit symptoms improved with the initiation of levetiracetam therapy and then had nearly completely resolved after surgical management of the fistula, we concluded that his stroke-like presentation was actually a seizure manifestation. In fact, the EEG that showed focal activity arising from the left frontal region highly suggested a seizure disorder. However, other possible causes of the seizure manifestation included venous congestion, a steal phenomenon from the ICA due to the CCF, or even a combination of underlying pathologic changes that were all secondary to the original head injury.

Early detection and neurosurgical intervention is warranted for all suspected CCF. It leads to prevention of complications such as intracranial hemorrhage, as well as irreversible partial or total vision loss. Very few cases have been reported in which blindness was reversed post-

transvenous embolization (10). Timely intervention usually results in almost complete resolution of presenting symptoms. However, spontaneous closure of CCF had been reported in literature (11).

Endovascular approach has replaced the traditional surgical approach as the modality of choice due to its safety and high success rate in treating CCF. The goal of endovascular embolization is to completely occlude the abnormal fistula while maintaining patency of the internal carotid artery.

Although transarterial embolization with a detachable balloon is the standard method of treating direct CCF, with reported success rates of 75–88% in preserving the patency of the parent ICA, a transvenous approach or utilization of coil may be necessary in cases where the size of the cavernous sinus and the fistula may lead to failure of embolization via traditional approach and recurrence of CCF (12,13). Near resolution of the patient's symptoms, as well as physical findings, were observed shortly after the endovascular procedure. This improvement was probably secondary to resolution of brain edema due to reversal of blood flow through dural veins.

#### WHY SHOULD AN EMERGENCY PHYSICIAN BE AWARE OF THIS?

The diagnosis of CCF should be kept in mind while evaluating a patient with focal neurological deficits as well as new onset of seizures, because it is a treatable condition in the setting of timely diagnosis.

#### REFERENCES

1. Barrow DL, Spector RH, Braun IF, Landman JA, Tindall SC, Tindall GT. Classification and treatment of spontaneous carotid-cavernous sinus fistulas. *J Neurosurg* 1985;62:248–56.
2. Thurman D, Alverson C, Dunn K, Guerrero J, Sniezek J. Traumatic brain injury in the United States: a public health perspective. *J Head Trauma Rehabil* 1999;14:602–15.
3. Tseng C, Wu K, Tsai S, Lew H. Development of carotid cavernous fistula after traumatic brain injury. *Am J Phys Med Rehabil* 2013; 92:187–8.
4. Vinuela F, Fox A, Debrun G, Peerless S, Drake C. Spontaneous carotid-cavernous fistulas: clinical, radiological, and therapeutic considerations. *J Neurosurg* 1984;60:976–84.
5. Naesens R, Mestdagh C, Breemers M, Defreyne L. Direct carotid-cavernous fistula: a case report and review of the literature. *Bull Soc Belge Ophthalmol* 2006;299:43–54.
6. Miller NR. Carotid-cavernous sinus fistulas. In: Miller NR, Newman NJ, Bioussé V, Kerrison JB, eds. *Walsh & Hoyt's clinical neuro-ophthalmology*. Philadelphia: Lippincott Williams & Wilkins; 2005:2263–96.
7. Murata H, Kubota T, Murai M, Kanno H, Fujii S, Yamamoto I. Brainstem congestion caused by direct carotid-cavernous fistula. *Neurol Med Chir* 2003;43:255–8.
8. Yarandi S, Khoshnoodi M, Chandra P. Hypopituitarism caused by carotid cavernous fistula. *Intern Med* 2011;50:1105–8.
9. Masaya-Anon P. Isolated oculomotor nerve palsy in a white-eyed patient with dural carotid cavernous sinus fistulas: a case report. *J Med Assoc Thai* 2012;95:S143–6.

10. Albuquerque FC, Heinz GW, McDougall CG. Reversal of blindness after transvenous embolization of a carotid-cavernous fistula: case report. *Neurosurgery* 2003;52:233–7.
11. Ishaq M, Arain MA, Ahmed S, Niazi MK, Khan MD, Iqbal Z. Spontaneous resolution of direct carotid cavernous fistula. *J Coll Physicians Surg Pak* 2010;20:622–4.
12. Luo CB, Teng MMH, Chang FC, Chang CY. Transarterial balloon-assisted n-butyl-2-cyanoacrylate embolization of direct carotid cavernous fistulas. *AJNR Am J Neuroradiol* 2006;27:1535–40.
13. Luo C, Teng M, Yen D, Chang F, Lirng J, Chang C. Endovascular embolization of recurrent traumatic carotid-cavernous fistulas managed previously with detachable balloons. *J Trauma* 2004;56:1214–20.