

Letter to the Editor

Palatal myoclonus, eight-and-a-half syndrome, and Holmes tremor in a patient from a single brainstem lesion



Keywords:

Palatal myoclonus
Holmes tremor
Eight and a half syndrome

1. Case presentation

A 53 year old African American male with a past history of hypertension, diabetes, hyperlipidemia, end-stage renal disease, seizures and pontine hemorrhage presented to the hospital with progressive abnormal

movements in his right arm. The patient noticed symptoms started several months after his pontine hemorrhage. On exam, the patient had left gaze palsy with very limited adduction of the left in right gaze (one and a half syndrome). A dissociated horizontal pendular nystagmus was evident, greater in the right eye. He had severe left lower motor neuron facial palsy as well as constant rhythmic contractions of left facial perioral muscles, orbicularis muscle, and elevation of the soft palate. These contractions continued while the patient spoke. The rhythmic contractions were synchronous with the nystagmus. He was severely dysarthric, but without evidence of aphasia. His right arm had 4/5 strength with very ataxic movements on coordination testing with tremor also present to some degree at rest. His right leg also had 4/5 strength with ataxic movements noted on coordination testing. He had decreased sensation to vibration in his right arm and leg. He had a history of ischemic strokes as well as a pontine hemorrhage, likely hypertensive in etiology that occurred in December of 2011. Neuroimaging findings are shown in Fig. 1.

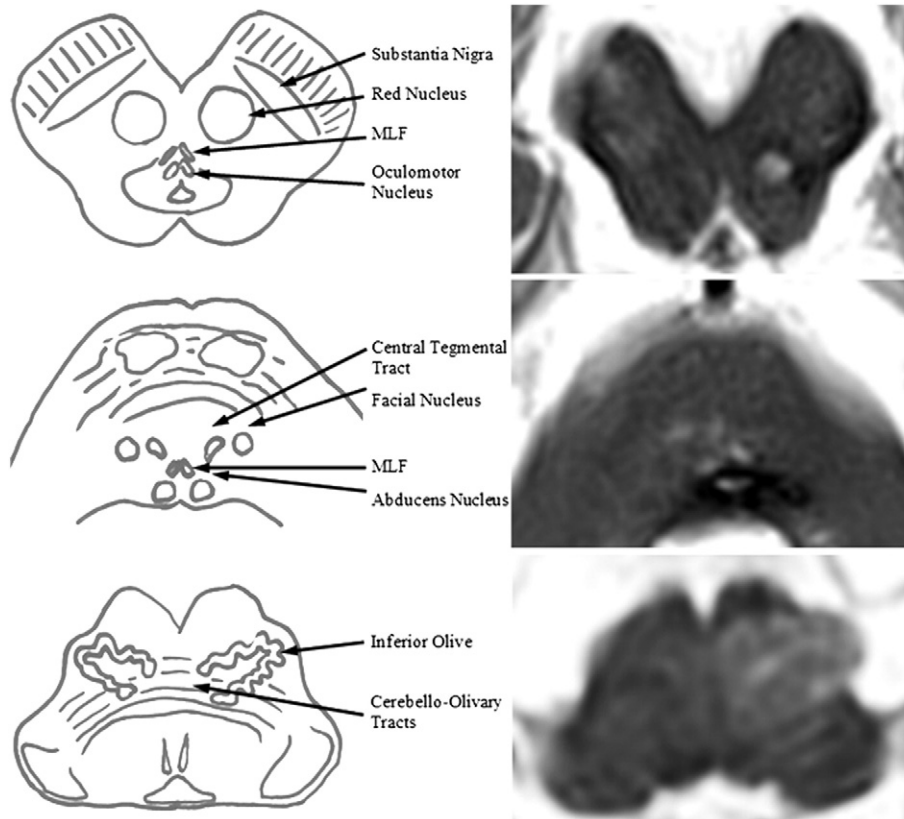


Fig. 1. Schematic diagram of midbrain, pons, and medulla with important structures labeled on the left and T2 weighted MRI images from our patient on the right. The top figure shows extension of the hemorrhage to involve the left red nucleus which is the cause of contralateral Holmes Tremor in this patient. The middle figure shows the bulk of the hemorrhage causing eight and a half syndrome and disconnection of the central tegmental tract which causes disinhibition of the corresponding inferior olivary nucleus. The bottom figure shows the resultant hypertrophy of the left inferior olivary nucleus which leads to oculopalatal myoclonus.

2. Discussion

One and a half syndrome is caused by lesions that involve the ipsilateral abducens nucleus and medial longitudinal fasciculus. The abducens lesion causes the left gaze palsy; involvement of the corresponding MLF disconnects the medial rectus subnucleus of the oculomotor nerve leading to impairment of adduction on right gaze as well. Involvement of the nearby facial nerve nucleus led to the left facial palsy. The combination is called eight-and-a-half syndrome [1]. This occurred immediately after the brainstem hemorrhage.

The right arm tremor was first documented 7 months after his hemorrhage. It had features of rest, intention, and postural tremor admixed together called Holmes tremor. Holmes Tremor has features of rest, intention tremor, frequency <4.5 Hz. It develops 4 weeks to 2 years after the causative lesion [2]. All three preceding criteria were met by our patient. Holmes tremor occurs due to disruption of the nigrostriatal and cerebellothalamic systems [3,4]. The patient's pontine hemorrhage extended rostrally into the midbrain involving the corresponding substantia nigra, thereby the nigrostriatal system. Disruption of the cerebellothalamic system occurred at two different locations: afferent cerebellar tracts entering at the level of the pons via the middle cerebellar peduncle, or efferent cerebellar tracts leaving through the superior cerebellar peduncle toward the red nucleus prior to extension to the thalamus.

Palatal myoclonus develops from lesion(s) involving the triangle of Guillain and Mollaret (dentate nucleus, red nucleus, central tegmental tract and inferior olivary nucleus). Gabaergic connections start in the contralateral dentate nucleus, travel to the red nucleus via the superior cerebellar peduncle before traveling down the central tegmental tract to the inferior olivary nucleus. Weeks to months after disruption, neuronal hypertrophy, gliosis, increased water content, demyelination, and vacuolization occur due to loss of inhibition [5–10]. One hypothesis suggests deafferentation leads to tonic coupling of cells in the inferior olivary nucleus through gap junction channels (called connexions) which permit transmission of ions between dendrites. Deafferentation leads to development of somatosomatic connexon junctions which is postulated to lead to synchronization of the discharge of inferior olivary neurons at 1–2 Hz [10]. This synchronized signal is sent to the cerebellar cortex through climbing fibers leading to maladaptive learning which produces pendular ocular oscillations [2]. This results in the combination of pendular nystagmus and palatal tremor called oculopalatal tremor as seen in our patient.

A treatment trial with diazepam and baclofen was unsuccessful. Subsequently, levodopa/carbidopa (Sinemet) was started for amelioration of Holmes Tremor. After 2 days of treatment, the patient was noted to have decrease in right hand tremor.

This case illustrates the diverse clinical phenomena which occur months to years after a single brainstem lesion resulting from intersection of multiple pathways.

Conflict of interest

The authors have no conflicts of interest to disclose.

References

- [1] Eggenberger E. Eight-and-a-half syndrome: one-and-a-half syndrome plus cranial nerve VII palsy. *J Neuroophthalmol* Jun 1998;18(2):114–6.
- [2] Ruigrok TJ, de Zeeuw CI, Voogd J. Hypertrophy of the inferior olivary neurons: a degenerative regenerative or plasticity phenomenon. *Eur J Morphol* 1990;28(2–4):224–39.
- [3] Zeuner K, Deuschl G. An update on tremors. *Curr Opin Neurol* Aug 2012;25:475–82.
- [4] Deuschl G, Bergman H. Pathophysiology of nonparkinsonian tremors. *Mov Disord* 2002;17(Suppl. 3):S41–8.
- [5] Pearce JMS. Palatal myoclonus (syn. palatal tremor). *Eur Neurol* 2008;60(6):312–5.
- [6] Krings T, Foltys H, Meister IG, Reul J. Hypertrophic olivary degeneration following pontine haemorrhage: hypertensive crisis or cavernous haemangioma bleeding? *J Neurol Neurosurg Psychiatry* Jun 2003;74:797–9.
- [7] Sakai T, Oishi H. Olivary hypertrophy and palatal myoclonus. *Arch Neurol* Dec 2004;61(12):1965.
- [8] Pearce J. Palatal myoclonus. *Proc R Soc Med* Mar 1969;62(3):267.
- [9] Deuschl G, Wilms H. Clinical spectrum and physiology of palatal tremor. *Mov Disord* 2002;17(Suppl. 2):S63–6.
- [10] Borruat FX. Oculopalatal tremor: current concepts and new observations. *Curr Opin Neurol* Feb 2013;26(1):67–73.

Robert D. Bolen, M.D.*

Nikhil Balakrishnan, M.D.

Department of Neurology, Wake Forest Baptist Hospital, Winston Salem, NC, United States

*Corresponding author at: Wake Forest Baptist Hospital, Medical Center Boulevard, Winston Salem, NC 27103, United States.
Tel.: +1 336 716 4101 (office); fax: +1 336 716 2810.
E-mail address: rbolen@wakehealth.edu (R.D. Bolen).

16 September 2014