




Contents lists available at ScienceDirect

Journal of the Neurological Sciences

journal homepage: www.elsevier.com/locate/jns

Short communication

Convexity subarachnoid hemorrhage in ischemic stroke

N. Usmani, F.U. Ahmad, S. Koch*

Department of Neurology and Neurosurgery, University of Miami Miller School of Medicine and Jackson Memorial Hospital, Miami, FL, USA

ARTICLE INFO

Article history:

Received 26 March 2014

Received in revised form 23 November 2014

Accepted 25 November 2014

Available online xxxxx

Keywords:

Convexity subarachnoid hemorrhage

Extracranial vaso-occlusive disease

Ischemic stroke

ABSTRACT

Objective: To report three cases of convexity subarachnoid hemorrhage (cSAH) after acute ischemic stroke and review the relevant literature.

Background: cSAH is an unusual presentation and the association with acute ischemic stroke has only infrequently been reported.

Design and methods: Case series with retrospective review of the clinical presentation and neuroimaging features of patients who presented with cSAH and acute ischemic stroke.

Results: We describe three cases of cSAH who presented with ipsilateral acute ischemic stroke. Two patients had ipsilateral ICA stenosis, with one patient developing cSAH after ICA stenting. The third patient developed cSAH in setting of small distal cortical ischemic lesions with normal cranial vasculature. None of these patients had evidence for cerebral amyloid angiopathy on magnetic resonance imaging–gradient echo (MRI-GRE) sequence. All our patients remained clinically stable with limited neurological deficit at the time of discharge.

Conclusion: We report three more cases linking cSAH with ischemic strokes. All of our patients had good outcome with minimal neurological deficit. cSAH should remain in differential diagnosis and early complication of acute ischemic stroke.

© 2014 Elsevier B.V. All rights reserved.

1. Introduction

Convexity subarachnoid hemorrhage (cSAH) is an unusual presentation of bleeding localized to the subarachnoid spaces overlying the cerebral cortex without involvement the basal cisterns or ventricles. Diverse etiologies of cSAH have been described including trauma, cortical vein thrombosis, posterior reversible leukoencephalopathy syndrome (PRES) in the setting of hypertension, reversible cerebral vasoconstriction syndrome (RCVS), coagulopathy, cocaine use, lupus vasculitis, cerebral amyloid angiopathy (CAA), primary CNS angitis, and rarely with extracranial occlusive arterial disease.

Two recent series, the largest to date, draw attention to CAA as a frequent cause of cSAH, particularly in the elderly [1]. Only a few cases have been reported in which the acute ischemic infarcts have been associated with cSAH [1–6]; however, in some instances, the area of infarction was distant from the location of cSAH [1,4,6]. In this report, we describe the association of acute cortical or juxtacortical small ischemic lesions associated with cSAH and hypothesize on potential mechanisms. While there have been several reports of cSAH associated with ischemic stroke and ICA occlusion [1–6] and following carotid stenting [7,8] and endarterectomy [9], the association of cSAH and small cortically based infarctions has only been described infrequently.

2. Case histories

2.1. Case 1

A 56-year-old male with history of smoking and hyperlipidemia was noted to have right side face and body weakness and numbness and was brought to our hospital with self-improvement of symptoms within 24 h. Patient had a prior episode with transient right lower extremity weakness 2 months ago. Blood pressure was 150/80 mmHg, and neurological exam including mental status, cranial nerves, motor, sensory, cerebellar, and gait testing was normal. Routine laboratory studies were normal. computed tomography (CT) scan showed a left frontal-parietal cSAH (Fig. 1A). MRI also revealed ischemia in left fronto-parietal and caudate head (Fig. 1B). MRI-GRE sequence revealed no evidence for amyloid angiopathy. Magnetic resonance angiogram (MRA) of head and neck revealed severe (75%) narrowing of proximal left ICA at origin, which was later confirmed by conventional angiogram to be 72% with an ulcerated atherosclerotic plaque. He was treated by an outside institution for a period of 6 months with therapeutic dose of Coumadin and has been doing well, with no neurological deterioration.

2.2. Case 2

A 66-year-old female with history of migraines, hypothyroidism, and hyperlipidemia developed sudden-onset right-sided weakness and numbness with slurred speech, 2 days after a long international flight. MRI showed a distal cortical stroke in left post central gyrus.

* Corresponding author at: Leonard M. Miller School of Medicine, University of Miami, 1120 NW 14th Street, Room 1365, Miami, FL 33136. Tel.: +1 305 243 2344; fax: +1 305 243 7538.

E-mail address: skoch@med.miami.edu (S. Koch).

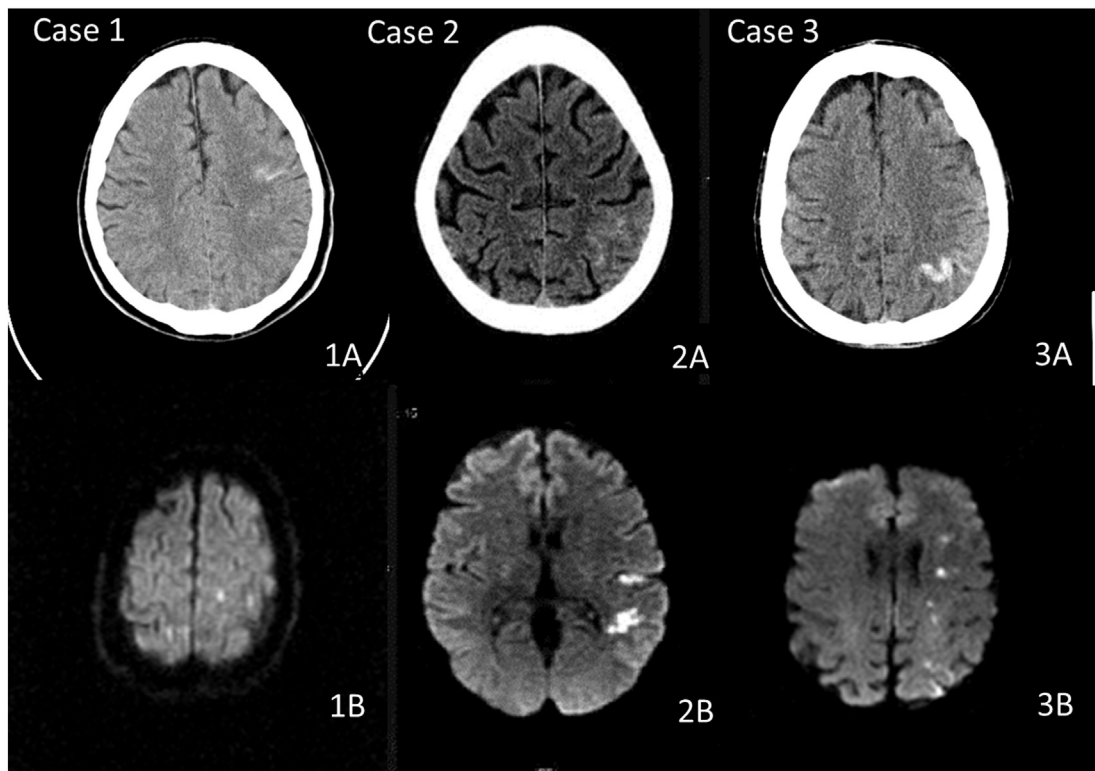


Figure. (Upper) Brain images of 3 acute ischemic stroke patients with CT scan head (Figs. 1A, 2A, 3A) showing the cSAH. (Lower) MRI diffusion-weighted image sequence (Figs. 1B, 2B, 3B) showing the adjacent acute cortical/juxtacortical stroke.

Transesophageal ECHO revealed a large patent foramen ovale (PFO) and a complete hypercoagulable panel that showed a heterozygous prothrombin mutation. Her symptom resolved in 5 days and was discharged home on aspirin and extended release dipyridole. Nine days later, patient was readmitted with a thunderclap headache. Blood pressure was noted to be 105/65, and physical exam was unremarkable except for neck rigidity. CT scan head revealed left parietal cSAH (Fig. 2A), and MRI showed cSAH and foci of acute infarct in left frontal and parietal area with no evidence of past parenchymal bleedings or superficial siderosis (Fig. 2B) unchanged from the previous admission. Conventional angiogram did not show any stenosis, aneurysm, vascular malformation, vasculitis, or cortical vein thrombosis. A brain MRI with GRE imaging, brain MRA, and cerebral MR venogram showed no cerebral vein or cortical vein thrombosis. She discharged on aspirin, rosuvastatin, and nimodipine and has done well for the past 4 years.

2.3. Case 3

A 59-year-old female with history of smoking, hypertension, diabetes mellitus type II, coronary artery disease, hepatitis C, and a remote history of cocaine use was admitted to our hospital for syncope. The workup was unremarkable except for plaque with stenosis noted on bilateral carotid bulbs (right side 90% and left side 60–79% stenosis). Patient underwent an elective left carotid stenting 1 month later. The procedure was uneventful. The blood pressure post procedure was maintained at 120/80, and the patient was treated with aspirin and clopidogrel. Postoperative day 4, patient developed an acute onset right-sided weakness and global aphasia. It was not associated with headache, head trauma, seizure, or drug abuse. CT scan brain revealed a left anterior frontal cSAH with left parietal intraparenchymal hemorrhage (Fig. 3A). MRI also revealed scattered areas of infarction in the watershed distribution in the left parietal-occipital lobe and subinsular cortex infarction with no evidence for microbleeds (Fig. 3B). CTA of neck and head revealed 50% stenosis in right proximal ICA, left ICA stent was patent, and so was the internal

circulation of the brain. Postoperative day 16, patient was discharged on aspirin and clopidogrel and had residual right hand and face weakness. Patient was followed up for a period of 8 months and was asymptomatic.

3. Discussion

In case series of patients with evidence of subarachnoid blood located over the convexities (including traumatic), the prevalence of isolated atraumatic cSAH has varied between 5% and 18% [1,8,10]. The clinical presentation of patients with spontaneous cSAH is different from those with aneurysmal SAH. The most common symptom in spontaneous cSAH group is headache (75%), thunderclap headache being uncommon (5%–56% vs 74% in aneurysmal SAH), and only 5% cases have been reported to have nuchal rigidity, unlike 35% in the aneurysmal SAH [10]. Seizure (20%–58%) [9] and focal neurological deficit [4] (35%–66%) is more frequent after spontaneous cSAH compared to aneurysmal SAH (reported to be 6%–7%) [11,12]. Local cortical irritation and more extensive parenchymal involvement from the underlying causes might explain the higher incidence of seizure and focal neurological deficit. The difference in the clinical presentation of these two categories could be related to the inherent difference in the cause of SAH.

Kumar et al. [8] described RCVS to be the commonest etiology for cSAH in population of age <60 years and CAA in patients >60 year. cSAH in the setting of ischemia has been described in ICA stenosis [2–6], moyamoya disease [13], ICA endovascular procedure stenting [1,7], or carotid endarterectomy [1]. cSAH has been described to occur invariably on the side with more severe stenosis [4,5]. Gerales et al. [4] and Nakajima et al. [6] described all their five cases of severe internal carotid artery atherosclerosis to be associated with ipsilateral cSAH.

Of note, none of the twenty patients described by Refai et al. [10], and only one each in the case series described by Kumar and Beitzke had previous infarcts on MRI [1,8]. Beitzke et al. [1] described five patients each with acute ischemic infarct (3 hemispheric and 2 infratentorial) concurrent to cSAH. In all instances, the ischemic infarct

was distant from cSAH, e.g., one patient had left cerebellum infarct coexisting with right frontal cSAH.

In our case series, we describe three cases of cSAH after ipsilateral acute ischemic stroke. Two patients had ipsilateral ICA stenosis, with one patient developed it after ICA stenting. This patient also had ipsilateral parenchymal hemorrhage along with cSAH. In all three of our patients, cerebral infarcts were acute, cortical (or juxtacortical), and in direct proximity to the cSAH.

Several explanations have been proposed for the association between carotid stenosis and cSAH. Long-standing carotid occlusive disease may lead to rupture of dilated fragile collateral pial vessels [2] with emboli to these marginally perfused vessels leading to necrosis and rupture [3]. In this setting, the role of reperfusion leading to vascular injury and rupture is supported by reports of cSAH hemorrhage occurring after revascularization procedure as in our third case. However, as shown in our second case, this may also occur in the absence of large arterial stenosis, i.e., small embolic occlusions of blood vessels close to the cortex, which subsequently may recanalize spontaneously and lead to endothelial injury and cSAH. In addition, two of our patients were on dual antiplatelet therapy, which could have also likely contributed to the subarachnoid hemorrhagic conversion. No pathological correlation for this presumed mechanism has been proven as yet.

In the three case series described above, the cSAH typically shows unilateral involvement of the subarachnoid space (83%), with the frontal lobe reported to be most often involved followed by parietal region [4,8,10]. In our case series, all cases had frontal and/or parietal cSAH and were ipsilateral to the side of severe stenosis and infarct.

The outcome of patients with non-aneurysmal and non-traumatic cSAH is variable. Patients with CAA-related cSAHs have been reported to have a poor outcome. Katoh et al. [14] reported restricted cSAH in the setting of CAA can be a harbinger for intracranial hemorrhage. Patel et al. [15] described these patients to have a benign course with no subsequent hemorrhages. Nakajima et al. [6], on the other hand, described their eight patients of cSAH with a relatively poor outcome. Three of their patients died (from an unrelated cause), and the other three patients had a significant residual neurological deficit at 3 months follow-up. One patient had suffered intracranial hemorrhage in setting of coumadin use. On subgroup analysis of the Galdes et al. [4] study, patients with cSAH with severe ICA stenosis had a relatively good outcome. The modified Rankin score in four of their five patients was ≤ 2 , at a median follow-up at 13.6 months. In our case series, none of the patients had recurrent events in the ensuing months of follow.

4. Conclusion

Our small case series of cSAH associated with acute ischemic stroke further strengthens the periously but rarely described association. We

would like to emphasize the attention the need to assess patients who present with isolated cSAH by initial brain CT for small ischemic lesions with DWI.

Conflict of interest

The authors have nothing to disclose.

References

- [1] Beitzke M, Gatteringer T, Enzinger C, Wagner G, Niederkorn K, Fazekas F. Clinical presentation, etiology, and long-term prognosis in patients with nontraumatic convexal subarachnoid hemorrhage. *Stroke* 2011;42(11):3055–60.
- [2] Cuvinciu V, Viguier A, Calviere L, Raposo N, Larue V, Cognard C, et al. Isolated acute nontraumatic cortical subarachnoid hemorrhage *AJNR Am J Neuroradiol* 2010; 31(8):1355–62.
- [3] Galdes R, Santos C, Canhao P. A traumatic localized convexity subarachnoid hemorrhage associated with acute carotid artery occlusion. *Eur J Neurol* 2011; 18(2):e28–9.
- [4] Galdes R, Sousa PR, Fonseca AC, Canhao F, Pinho e Melo T. Pinho e Melo T. Nontraumatic convexity subarachnoid hemorrhage: different etiologies and outcomes *J Stroke Cerebrovasc Dis* 2014;23(1):e23–30.
- [5] Kleinig TJ, Kimber TE, Thompson PD. Convexity subarachnoid haemorrhage associated with bilateral internal carotid artery stenoses. *J Neurol* 2009;256(4):669–71.
- [6] Nakajima M, Inatomi Y, Yonehara T, Hirano T, Ando Y. Nontraumatic convexal subarachnoid hemorrhage concomitant with acute ischemic stroke. *J Stroke Cerebrovasc Dis* 2014;23(6):1564–70.
- [7] Hartmann M, Weber R, Zoubaa S, Schranz C, Knauth M. Fatal subarachnoid hemorrhage after carotid stenting. *J Neuroradiol* 2004;31(1):63–6.
- [8] Kumar S, Goddeau Jr RP, Selim MH, Thomas A, Schlaug A, Alhazzani A, et al. A traumatic convexal subarachnoid hemorrhage: clinical presentation, imaging patterns, and etiologies. *Neurology* 2010;74(11):893–9.
- [9] Spitzer C, Mull M, Rohde V, Kosinski CM. Non-traumatic cortical subarachnoid haemorrhage: diagnostic work-up and aetiological background. *Neuroradiology* 2005;47(7):525–31.
- [10] Refai D, Botros JA, Strom RG, Derdeyn CP, Sharma A, Zipfel GJ. Spontaneous isolated convexity subarachnoid hemorrhage: presentation, radiological findings, differential diagnosis, and clinical course. *J Neurosurg* 2008;109(6):1034–41.
- [11] van Gijn J, Rinkel GJ. Subarachnoid haemorrhage: diagnosis, causes and management. *Brain* 2001;124(Pt 2):249–78.
- [12] Pinto AN, Canhao P, Ferro JM. Seizures at the onset of subarachnoid haemorrhage. *J Neurol* 1996;243(2):161–4.
- [13] Marushima A, Yanaka K, Matsuki T, Kojima H, Nose T. Subarachnoid hemorrhage not due to ruptured aneurysm in moyamoya disease. *J Clin Neurosci* 2006;13(1):146–9.
- [14] Katoh M, Yoshino M, Asaoka K, Aoki T, Imamura H, Kashiwazaki D, et al. A restricted subarachnoid hemorrhage in the cortical sulcus in cerebral amyloid angiopathy: could it be a warning sign? *Surg Neurol* 2007;68(4):457–60.
- [15] Patel KC, Finelli PF. Nonaneurysmal convexity subarachnoid hemorrhage. *Neurocrit Care* 2006;4(3):229–33.