

Venous Stroke and Status Epilepticus Due to Milk-Induced Anemia in a Child

Leslie Finkel, MD, Juan Piantino, MD, Joshua Goldstein, MD, and Mark S. Wainwright, MD, PhD

Abstract: The risk factors for cerebral sinus venous thrombosis include dehydration, infection, and anemia. The clinical presentation in children of venous strokes associated with cerebral venous thrombosis is variable and may include seizures. Acute management should focus on the treatment of the primary cause and anticoagulation or antiplatelet therapy if needed. Early recognition and targeted treatment is important because survivors are at increased risk for long-term neurologic complications. We report a case of a 4-year-old girl who presented with status epilepticus and was subsequently found to have a cerebral venous sinus thrombosis in the transverse and sigmoid sinus, with venous infarction in the temporal lobe. Laboratory results were significant for a microcytic anemia caused by excessive milk intake. Although iron deficiency anemia is a common pediatric disorder, this uncommon presentation demonstrates the potential for neurologic complications secondary to anemia, as well as the need for a high index of suspicion in order to identify venous stroke as a cause in children who present to the emergency department with seizures.

Key Words: anemia, cerebral sinovenous thrombosis, status epilepticus, stroke

(*Pediatr Emer Care* 2015;31: 129–131)

Iron deficiency anemia is still a significant problem in the United States. According to the CDC data from 2003 to 2006, 14% of children aged 1 to 2 years and 4% of children aged 3 to 5 years have iron deficiency anemia. Feeding cow's milk to infants and young children is strongly associated with diminished iron stores and increased probability of iron deficiency.^{1,2} Initial symptoms may be subtle and include pallor, pagophagia, and decreased activity. Untreated anemia may result in complications including ischemic cerebrovascular disease and adverse effects on neurodevelopment.²

The incidence of cerebral sinus venous thrombosis (cSVT) in children is less than 1/100,000 per year and may present with protean neurologic deficits including encephalopathy and seizures. Risk factors include infection, dehydration, and anemia.³ Guidelines for management include treatment of the primary cause and anticoagulation or antiplatelet therapy.⁴

We report a case of a healthy child who presented to the emergency department (ED) with status epilepticus due to a venous stroke. She was found to have iron deficiency anemia caused by excess milk ingestion. This case illustrates the diverse presentations of cerebral venous thromboses in children and highlights a preventable neurologic complication of a milk-induced anemia.

CASE

A 4-year-old, previously healthy, girl presented to the ED with status epilepticus. She complained of headache for 2 weeks

and abdominal pain for 2 days before admission. On the morning of presentation, she had experienced onset of right arm tonic-clonic activity and arrived in the ED in complex partial status epilepticus. For acute management of seizures, the patient received 2 doses of intravenous Ativan (0.1 mg/kg) and a dose of Fosphenytoin (20 mg/kg), followed by a 10-mg/kg dose. She was then noted to have sustained eye deviation to the right. Her pupils were dilated (left greater than right) and were nonreactive. Fundoscopic examination was not documented. She did not withdraw to painful stimulus. Her toes were downgoing, clonus was absent, and reflexes were decreased throughout. She was intubated for airway protection and began to have 4 extremity internal rotation with a rhythmic component, for which she received 2 doses of Phenobarbital (20 mg/kg, then 10 mg/kg). Head computed tomography (CT) obtained in the ED (Fig. 1A) was suspicious for subdural hemorrhage or venous sinus thrombosis. Continuous electroencephalogram monitoring showed diffuse left-sided slowing and no ictal activity. The patient became febrile, and a lumbar puncture was performed (Table 1). She was treated with acyclovir and meningitic dosing of vancomycin and ceftriaxone. Magnetic resonance imaging (MRI) with venogram was performed on the same day (Fig. 1B) and showed filling defects in the left transverse and sigmoid sinuses consistent with non-occlusive thrombus. There was also a focal area of T2 hyperintensity in the inferior and lateral left temporal lobe, consistent with a small venous infarction (Fig. 1C).

The patient's social history was notable for a 1-year history of pica (toilet paper), continued use of a bottle to drink, and over 1 year of ingestion of at least 1 ½ gallons of milk daily. Laboratory studies on admission revealed a microcytic anemia (hemoglobin, 7.7 g/dL [normal range, 11.5–13.5 g/dL] and mean corpuscular volume 54 fL [normal range, 75–87 fL]), which was attributed to her excessive milk intake. Echocardiogram and Doppler studies of other extremities revealed no other venous or cardiac thrombi. Screening studies for other genetic or autoimmune factors associated with venous or arterial strokes in children (Table 2) were negative.

She was transfused with red blood cells and treated with a 2-day course of empiric antibiotics. She had no further seizures and was discharged on Levetiracetam 29 mg/kg per day divided twice daily for a 5-month course of treatment. For management of cerebral venous thrombosis, she was treated with Enoxaparin for a 4-month course following published guidelines for treatment of venous stroke in children.⁴ At 4 months follow-up, her neurologic examination was normal, and she had no further symptoms, although the long-term sequelae of this stroke, including seizures and impaired memory, may not yet be apparent.

DISCUSSION

The presenting signs and symptoms of cSVT are variable and may include headache, decreased consciousness, cranial nerve palsies, focal weakness, and papilledema.³ The majority of patients have an identifiable predisposing risk factor including dehydration, infection, diabetic ketoacidosis, or anemia. Our patient presented with seizures, which is the most common presenting

From the Ruth D. & Ken M. Davee Pediatric Neurocritical Care Program, Ann & Robert H. Lurie Children's Hospital of Chicago, Northwestern University Feinberg School of Medicine, Chicago IL.

Disclosure: The authors declare no conflicts of interest.

Reprints: Mark S. Wainwright, MD, PhD, Division of Neurology, No. 51, Ann & Robert H. Lurie Children's Hospital of Chicago, 225 E. Chicago Ave, Chicago, IL 60611 (e-mail: m-wainwright@northwestern.edu).

Copyright © 2015 Wolters Kluwer Health, Inc. All rights reserved. ISSN: 0749-5161

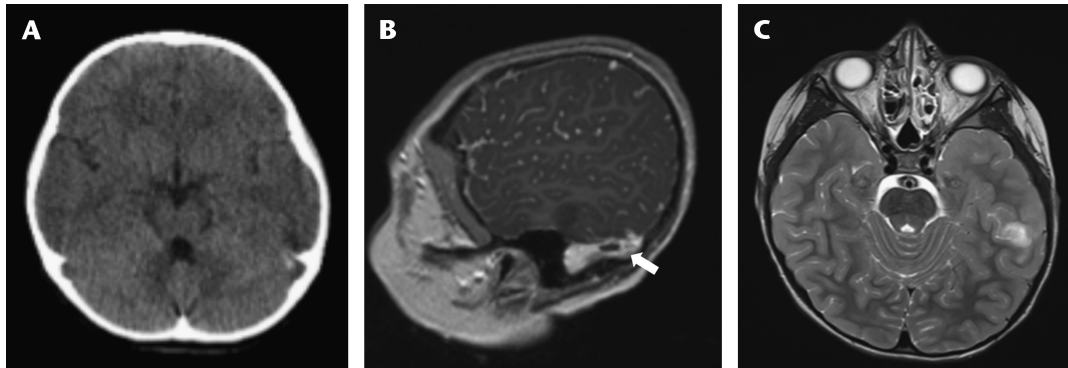


FIGURE 1. (A) Admission CT scan (axial view) showing focal hyperattenuation in the left transverse/sigmoid sinus. (B) MR venogram (sagittal view) showing a filling defect in the left transverse/sigmoid sinus concerning for nonocclusive thrombus (arrow). (C) MRI brain (axial T2 weighted) showing focal signal changes in the inferior and lateral left temporal lobe consistent with small venous infarction.

symptom in many studies.^{3,5} Up to 50% of children with cerebral cSVT may have long-term neurologic deficits, and the risk is increased in infants.⁵ Accordingly, a high index of suspicion is needed in order to identify the thrombosis with appropriate imaging in order to begin treatment and to manage potential complications including seizures, hydrocephalus, and intracranial hemorrhage.

The initial routine head CT obtained in the ED did not identify the presence of cSVT. When cSVT is suspected, this should be confirmed with either MRI T2-weighted imaging with MR venogram or CT venogram if MRI is not available.^{4,6} Acute management can begin in the ED by treatment of the primary disorder using antimicrobials or hydration. Anticoagulation with either

unfractionated or low molecular weight heparin is recommended for children,^{4,7} although this is a class IIa recommendation. The objective of treatment with anticoagulants is to promote recanalization of the vessel and to limit propagation of the thrombus. In adults, there is a specific recommendation for the acute use of weight-adjusted doses of low molecular weight heparin.⁶ No such data are available to recommend a specific agent in children.

Our patient presented with microcytic anemia, which is a recognized risk factor for cSVT. The peak prevalence of iron-deficiency anemia is 4% to 8% in children between the ages of 1 and 3 years.⁸ Iron deficiency affects an estimated 2 billion people worldwide.⁹ Children with iron-deficiency anemia or iron deficiency alone are at increased risk of cognitive impairment, particularly in mathematics, and possibly attention-deficit hyperactivity disorder.^{10,11}

Thrombocytosis was also a prominent laboratory abnormality in our patient, although only on the first complete blood count and may have been an acute phase reaction. The association of iron deficiency anemia, with thrombocytosis and venous stroke in a child has previously been reported.¹² In a more recent series of 4 children with iron-deficiency anemia and stroke, 3 were due to cSVT and 1 due to arterial ischemic stroke. As in our patient, 2 of these patients consumed large quantities of cows' milk and 2 presented with focal seizures.¹³ In a case-control study of children between 12 and 38 months, children with anemia were 10 times more likely to have a stroke. Of these 15 cases, 6 (40%) were venous infarcts.¹⁴

TABLE 1. Laboratory Values

Laboratory Test	Result
WBC	22,800/ μ L*
Hemoglobin	7.7 g/dL*
Hematocrit	30%*
Platelets	1,082,000/ μ L*
MCV	54 fL*
RDW	18%*
Lead	<3 mg/dL
D-Dimer	<1.3 μ g/mL*
Coagulation profile	aPTT 21 s*, PT 11.9 s, INR 1.2
Fibrinogen	202 mg/dL
CRP, ESR	0.4 mg/dL, 7 mm/h
Lumbar puncture	1 WBC, 185 RBC, protein 23, glucose 87, cytology and infectious studies normal
Iron studies	Iron 34*, TIBC 472*, transferrin 372*, % saturation 7, ferritin 8* \rightarrow 22
LDH	351 IU/L
Reticulocytes	1.7%

Basic metabolic panel was within normal limits, with the exception of glucose [data not shown].

*Abnormal values.

MCV indicates mean corpuscular volume; RDW, red cell distribution width; CRP, C-reactive protein; ESR, erythrocyte sedimentation rate; TIBC, total iron binding capacity; LDH, lactate dehydrogenase.

TABLE 2. Thrombophilia Evaluation

Laboratory Test	Result
Prothrombin gene mutation PCR	Negative
Factor V Leiden	Negative
Antiphospholipid antibody panel	Negative
Lupus anticoagulant	Negative
Protein C	86%
Protein S	86%
Antithrombin III	102%
Lipoprotein A	15 nmol/L
Homocysteine	3.4 μ mol/L
Coagulation factor VIII activity	183%*

*Abnormal value.

Given the risk for long-term compromise of neurodevelopment resulting from iron-deficiency and iron-deficiency anemia in infancy, the American Academy of Pediatrics recommends 7 mg per day of dietary iron for children from 1 through 3 years.¹⁵ Bottle feeding has also been associated with excessive milk intake in observational studies, and the American Academy of Pediatrics recommends weaning children from the bottle by 15 months.¹⁶

There is considerable regional variation in the management of cSVT. In an international study of 84 neonates with isolated cSVT, infants in the United States were less likely to be treated with anticoagulation or antiplatelet therapy.¹⁷ However, anticoagulation appears to be safe for the acute treatment and may reduce propagation of the thrombus in both neonates and children.¹⁸ A recent meta-analysis also suggests that anticoagulation reduces both mortality and the risk of sequelae in children and neonates, although these conclusions are limited by differences in study design, endpoints, and duration of follow-up.¹⁹

Iron-deficiency anemia is common in children between the ages of 1 and 3 years, and excess milk intake is a common cause. This general pediatric problem is associated with a significant increase in the risk of stroke, particularly venous thrombosis. The clinical presentation and imaging findings of cSVT may be subtle. This case illustrates the need for a high index of suspicion to identify through appropriate imaging, examination, and laboratory tests early signs of a treatable disorder with the potential for long-term neurologic morbidity.

REFERENCES

1. Penrod JC, Anderson K, Acosta PB. Impact on iron status of introducing cow's milk in the second six months of life. *J Pediatr Gastroenterol Nutr.* 1990;10:462–467.
2. Kwiatkowski JL, West TB, Heidary N, et al. Severe iron deficiency anemia in young children. *J Pediatr.* 1999;135:514–516.
3. Wasay M, Dai A, Ansari M, et al. Cerebral venous sinus thrombosis in children: a multicenter cohort from the United States. *J Child Neurol.* 2008;23:26–31.
4. Roach E, Golomb M, Adams R, et al. Management of stroke in infants and children. *Stroke.* 2008;39:2644–2691.
5. Sebire G, Tabarki B, Saunders D, et al. Cerebral venous sinus thrombosis in children: risk factors, presentation, diagnosis and outcome. *Brain.* 2005;128:477–489.
6. Saposnik G, Barinagarrementeria F, Brown R, et al. Diagnosis and management of cerebral venous thrombosis: a statement for healthcare professionals from the American Heart Association/American Stroke Association. *Stroke.* 2011;42:1158–1192.
7. Monagle P, Chalmers E, Chan A, et al. Antithrombotic therapy in neonates and children: American College of Chest Physicians evidence-based clinical practice guidelines. *Chest.* 2008;133:887S–968S.
8. Booth I, Aukett M. Iron deficiency anemia in infancy and early childhood. *Arch Dis Child.* 1997;76:549–554.
9. Zimmerman M, Hurrell R. Nutritional iron deficiency. *Lancet.* 2007;370:511–520.
10. Halterman J, Kaczorowski J, Aligne C, et al. Iron deficiency and cognitive achievement among school-aged children and adolescents in the United States. *Pediatrics.* 2001;107:1381–1386.
11. Abbas E, Valli S. Iron deficiency anaemia in children with ADHD. *Arch Dis Child.* 2012;97:A93–A94.
12. Belman AL, Roque CT, Ancona R, et al. Cerebral venous thrombosis in a child with iron deficiency anemia and thrombocytosis. *Stroke.* 1990;21:488–493.
13. Munot P, De Vile C, Hemingway C, et al. Severe iron deficiency anaemia and ischaemic stroke in children. *Arch Dis Child.* 2011;96:276–279.
14. Maguire JL, deVeber G, Parkin PC. Association between iron-deficiency anemia and stroke in young children. *Pediatrics.* 2007;120:1053–1057.
15. Baker RD, Greer FR. Diagnosis and prevention of iron deficiency and iron-deficiency anemia in infants and young children (0–3 years of age). *Pediatrics.* 2010;126:1040–1050.
16. Maguire JL, Birken CS, Jacobson S, et al. Office-based intervention to reduce bottle use among toddlers: TARGet Kids! Pragmatic, randomized trial. *Pediatrics.* 2010;126:e343–e350.
17. Jordan LC, Rafay MF, Smith SE, et al. Antithrombotic treatment in neonatal cerebral sinovenous thrombosis: results of the International Pediatric Stroke Study. *J Pediatr.* 2010;156:704–710.
18. Moharir MD, Shroff M, Stephens D, et al. Anticoagulants in pediatric cerebral sinovenous thrombosis: a safety and outcome study. *Ann Neurol.* 2010;67:590–599.
19. Lebas A, Chabrier S, Fluss J, et al. EPNS/SFNP guideline on the anticoagulant treatment of cerebral sinovenous thrombosis in children and neonates. *Eur J Pediatr Neurol.* 2012;16:219–228.