

Loss of motivation for speaking with bilateral lacunes in the anterior limb of the internal capsule

B. Croisile*, E. Henry*, M. Trillet*, G. Aimard*

Introduction

Language disorders, differing from classical cortical aphasia, are frequent after subcortical lesions¹. Bilateral lesions in the basal ganglia are sometimes responsible for behavioral alterations without dementia. The most dramatic is the loss of self psychic activation²⁻⁶, when patients show inertia for all behavioral activities, but it is easily reversible after external stimulation. We report a patient who only lost the motivation for speaking. CT scan showed bilateral lacunes, mainly in the anterior limb of the internal capsule. This case emphasizes the role of activating cortico-subcortical loops.

Case report

Our patient, a 76-year-old man, right-handed, retired master-builder, with systemic hypertension, had no familial or personal history of psychiatric disorders. In December 1987 he suddenly presented with a mild right hemiparesis and his wife noticed that he spoke less than usually. There was no headache, no dysarthria, no word-finding difficulty, no paraphasia and no oral comprehension deficit.

His first medical consultation was in March 1988. Since 4 months he had lost desire for speaking with other people but he was not so reluctant once conversation was engaged. When he took previously one hour for his shopping he

Summary

A 76-year-old man suddenly presented with loss of motivation for speaking. He had no aphasia, depression or dementia, but he did not want to speak with other people. CT scan showed hypodensities, presumably lacunes, mainly in the anterior limb of the two internal capsules. Global behavioral changes with loss of self psychic activation have been reported, but in our patient the disturbance was restricted to oral language. The role of activating cortico-subcortical loops is discussed.

Key words: psychic akinesia, internal capsule, motivation, speaking.

now spent only ten minutes because he avoided his friends with whom he did not want to speak. He told no more jokes. The loss was limited to speaking as he had usual motivation for previous activities which were fully preserved: dining, dressing, washing, reading, writing, gardening, watching television. He demonstrated no anxiety or special feeling about his loss of motivation for speaking. He had no compulsive behavior, no personality change and his affect was normal. Using DSM III and MADRS criteria there was no depression. Attention and orientation were normal. Apart from mild dysprosody his language examination was normal: fluency, articulation, word-naming, oral

* Department of Neurology (Pr Trillet and Pr Aimard), Hôpital Neurologique, Lyon, France

Address for correspondence and reprint requests: Dr. Croisile, Department of Neurology (Pr Trillet and Pr Aimard), Hôpital Neurologique, 59 boulevard Pinel, 69394 Lyon cedex 3, France

Accepted 10.4.89

Clin Neurol Neurosurg 1989. Vol 91-4

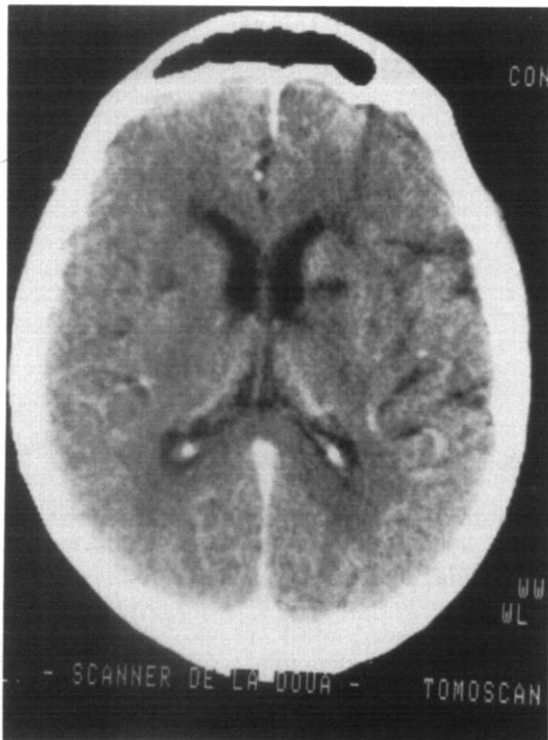


Fig. 1. Contrast-enhanced CT. Lacunes of the left and right anterior limbs of the internal capsule and near the two frontal horns (the left side of the patient is on the right of the photograph)

expression and comprehension, repetition, writing, reading aloud, oral spelling, calculation. There was no frontal semiology and all Luria's series were normal. He could learn and recall digits, words and pictures; he could summarize the story of the various books he was reading (five/week). There was no constructional or limb apraxia.

CT scan showed bilateral hypodensities in the anterior limb of the internal capsule with perhaps involvement of the putamen but limited to its anterior aspect (Fig. 1). There were hypodensities near the two frontal horns, at the entrance of the anterior limb of the internal capsule, and the left sylvian fissure was enlarged. CT scan was performed four months after the onset but these hypodensities were presumably lacunes or infarctions more than sequels from hematoma.

Discussion

Our patient presented with an unusual symptom which cannot be related to dementia, depres-

sion or aphasia. He had no deficit in intellectual or cognitive functioning. His specific loss of interest toward speaking was easily reversible by external stimulations, and conversation was therefore normal. This is not consistent with aphemia, mutism, transcortical motor aphasia or frontal syndrome⁷. Left-sided lesions, involving the anterior limb of the internal capsule, the head of the caudate nucleus and the putamen have been related with dysarthria, right hemiparesis, dysprosody and atypical aphasia⁸. Patients with right-sided lesions in the same sites had often dysarthria or dysprosody⁸. Our patient had only a mild dysprosody; the disturbance of the oral speech was not aphasic and did not resemble the clinical pictures of subcortical aphasia¹. In fact he demonstrated a behavioral syndrome limited to speech rather than a true aphasia.

Pure psychic akinesia (or athymhormia syndrome) corresponds with the loss of drive and initiative²⁻⁶. Patients show dramatic reduction of their usual activities with a flattened affect. They stay for hours doing nothing and they do not take part in sport or in social activities. Mild extrapyramidal symptoms are sometimes present, but there is no reduction of motor abilities. Physical and intellectual capacities are always normal, as are neuropsychological tests. Some patients have compulsive activities: mental counting, verbal and motor stereotypes or obsessive collecting^{2,3,5}. In only one patient this was similar to an obsessive neurosis with intense anxiety and a magic-like clue⁵. In all cases the lack of initiative is also present in language. As in our case, patients talk only if asked and they do not try to engage conversation whereas neuropsychological evaluation failed to demonstrate aphasia, except dysprosody or defect in speech fluency. For Laplane *et al.*^{2,5} this capacity to maintain normal activities after stimulation shows that psychic akinesia is different from frontal lobe syndrome or subcortical dementia, and corresponds to the loss of self psychic activation.

Pure psychic akinesia is the consequence of lesions in the basal ganglia after carbon monoxide poisoning, wasp sting or vascular disease. Lesions are bilaterally located: in the globus pallidus^{2,3,5}, in the head of the caudate nuclei⁴ or in the striatum⁶. These structures are also in-

volved in subcortical diseases with motor or cognitive disturbances (Parkinson's disease, Huntington chorea, progressive supranuclear palsy).

In our patient, as far as we can rely upon the resolution of the CT scan, the anterior limbs of the internal capsule seemed to be mostly damaged with little extension into the gray-matter nuclei. There was a hypodensity near the left frontal horn. The interpretation can be related to (1) disconnection of fibre pathways in the white matter anterior limb and to (2) some damage to the adjacent caudate nuclei and putamens. The globus pallidus was not involved. In the anterior limb of the internal capsule the major pathways are: prefrontal corticopontine tract, projections from the head of the caudate nucleus to the putamen, anterior thalamic radiation connecting the frontal premotor and motor cortex and the prefrontal cortex with respectively ventral anterior, ventral lateral and dorsomedian thalamic nuclei⁹.

Five circuits linking cortex and basal ganglia have been described^{10,11}. Three are of interest in our case. The lateral orbitofrontal and dorsolateral prefrontal cortex have projections on the caudate nucleus, followed by connection with the rostral part of globus pallidus which in turn projects to the dorsomedian and ventral anterior thalamic nuclei. These nuclei send efferents toward prefrontal cortex. Ventral limbic striatum receives efferents from the limbic cortex, mainly the anterior cingulate cortex. Then, through globus pallidus, ventral striatum is the origin of input to the dorsomedian thalamic nucleus which in turn projects largely to the anterior cingulate cortex.

Bilateral lesions in any part of these three

cortico-subcortical loops may result in loss of drive^{2,6}. In our patient there is mainly interruption of white matter pathways linking nuclei in these cognitive and limbic loops. The occurrence of a specific defect with the activation of speech suggests that the lesions do not involve equally the fibres but only those specifically concerned with motivation for speech.

References

- 1 BASSO A, DELLA SALA S, FARABOLA M. Aphasia arising from purely deep lesions. *Cortex* 1987; 23: 29-44.
- 2 LAPLANE D, BAULAC M, WIDLÖCHER D, DUBOIS B. Pure psychic akinesia with bilateral lesions of basal ganglia. *J Neurol Neurosurg Psychiatry* 1984; 47: 377-85.
- 3 ALI-CHERIF A, ROYERE ML, GOSSET A, PONCET M, SALAMON G, KHALIL R. Troubles du comportement et de l'activité mentale après intoxication oxycarbonée. Lésions pallidales bilatérales. *Rev Neurol (Paris)* 1984; 140; 6-7: 401-5.
- 4 RICHFIELD EK, TWYMAN R, BERENT S. Neurological syndrome following bilateral damage to the head of the caudate nuclei. *Ann Neurol* 1987; 22: 768-71.
- 5 LAPLANE D, BOULLIAT J, BARON JC, PILLON B, BAULAC M. Comportement compulsif d'allure obsessionnelle par lésion bilatérale des noyaux lenticulaires. *L'Encéphale* 1988; XIV: 27-32.
- 6 HABIB M, PONCET M. Perte de l'élan vital, de l'intérêt et de l'affectivité (syndrome athymhormique) au cours de lésions lacunaires des corps striés. *Rev Neurol (Paris)* 1988; 144: 571-7.
- 7 STUSS DT, BENSON DF. *The Frontal Lobes*. New York: Raven Press, 1986: 164-7.
- 8 DAMASIO AR, DAMASIO H, RIZZO M, VARNEY N, GERSH F. Aphasia with nonhemorrhagic lesions in the basal ganglia and internal capsule. *Arch Neurol* 1982; 39: 15-20.
- 9 CARPENTER MB, SUTIN J. *Human Neuroanatomy*, ed 8. Baltimore: Williams & Wilkins, 1983.
- 10 NAUTA WJH. Circuitous connections linking cerebral cortex, limbic system, and corpus striatum. In: Doane BK, Livingstone KE, ed. *The limbic system: Functional organization and clinical disorders*. New York: Raven Press, 1986.
- 11 ALEXANDER GE, DELONG MR, STRICK PL. Parallel organization of functionally segregated circuits linking basal ganglia and cortex. *Ann Rev Neurosci* 1986; 9: 357-81.